Volume 05 | Issue 02
28st April 2024
p-ISSN 2721 - 9984
e-ISSN 2721 - 9976
heartscience.ub.ac.id

Heart Science Journal



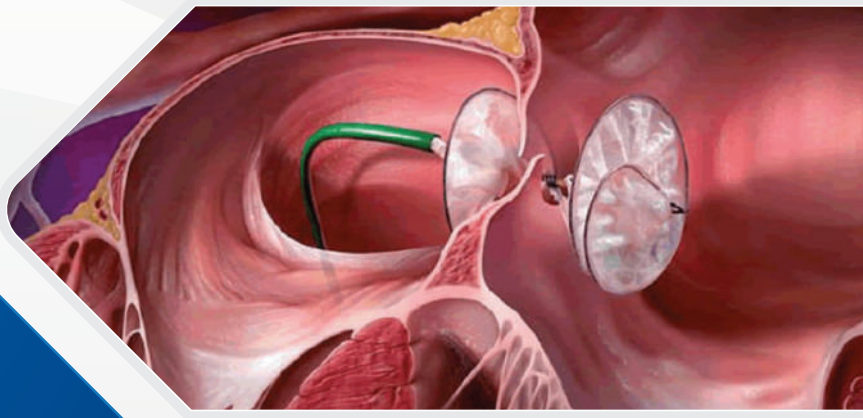



Focus Issue on:

Challenges in the Management of Congenital Heart and Structural Heart Disease

Editorial
· Advancing Scholarship: HSJ Attains Scopus Indexing – Embarking on A New Scientific Journey
· The Current Strategy in Managing Congenital and Structural Heart Disease: Find and Treat them Appropriately

Review Article
· Recognizing Total Anomalous Pulmonary Venous Drainage (TAPVD) from Natural History to the Supportive Imaging Modalities
· Clinical Features and Multimodality Diagnostic Tools of Pulmonary Hypertension
· Echocardiography Features in Patient Rheumatic Mitral Stenosis
· Cardioprotective Effect of Remote Ischemic Preconditioning: From Bench to Bedside
· Sudden Cardiac Death in Young Age, What Should We Know?

Original Article
· Impact of Strict and Lenient Heart Rate Control on Six-Minute Walk Test and Quality of Life in Atrial-Fibrillation Patients with Rheumatic Mitral Stenosis : Randomized Control Trial
· Effects of the Low-Dose Colchicine Regimen on Left Ventricular Adverse Remodeling and Systolic Function in Acute Myocardial Infarction Patients With Anterior ST Segment Elevation Undergoing Primary Percutaneous Coronary Intervention: A Randomized Controlled Trial
· The Relationship Between Cha2ds2-Vasc Scores and The Degree of TIMI Flow in Patients with Acute St-Segment Elevation Myocardial Infarction Who Underwent Primary Percutaneous Coronary Intervention at Dr. Saiful Anwar Malang

Case Report
· How to Recognize and Overcome Pulmonary Hypertension Crisis During Patent Ductus Arteriosus Closure by Device in Adult
· Managing a Challenging Case: Transesophageal Echocardiography-Guided Transcatheter Closure of a large Secundum Atrial Septal Defect in a Pregnant Woman
· Management of Pregnant Women with Atrial Septal Defect and Pulmonary Hypertension: A Case Report
· Navigating Complex Cardiovascular Pathologies: A Case Report on Aortic Arch Replacement in a Middle-Aged Male with Stanford A DeBakery I Aortic Dissection
· Cracking The Case of The Cryptic Coronary: Diagnostic Strategies for Anomalous RCA Originating from LAD
· Recurrent Orthodromic SVT AVRT with Multiple Accessory Pathway in WPW syndrome: Ablate All or Not?

Editor-in-chief
Mohammad Saifur Rohman, Indonesia

Deputy Editors
Yoga Waranugraha, Indonesia
Jonny Karunia Fajar, Indonesia

Universitas Brawijaya

p-ISSN 2721 - 9984
e-ISSN 2721 - 9976

Heart Science Journal

Official Open Access Journal of Brawijaya Cardiovascular Research Center

Volume 5 • Issue 2 • April 2024 • page 1–91

DOI: http://dx.doi.org/10.21776/ub.hsj.2024.005.02

Focus and Scopes

The **Heart Science Journal** is the official open access journal of Brawijaya Cardiovascular Research Center, Department of Cardiology and Vascular Medicine, Faculty of Medicine, Universitas Brawijaya, Malang, Indonesia. The journal publishes articles four times per year in January, April, July and October. The journal is a peer reviewed publication and accepts articles for publication from across the world. **Heart Science Journal** accepts and publishes articles in the English language only.

The primary goal of this journal is to publish clinical and basic research relevant to cardiovascular medicine. The journal covers the following topics: clinical cardiology, interventional cardiology, intensive and acute cardiovascular care, vascular diseases, non-invasive cardiology, pediatric cardiology, cardiac nuclear medicine imaging, arrhythmia, cardiac prevention and rehabilitation, and cardiac surgery. Animal studies are also considered for publication in **Heart Science Journal**.

To serve the interest of both practicing clinicians and researchers, the journal provides platform or forum for research scholars, intellectuals, and cardiologists to reveal their views and research work for dialogue, education, and interaction to the entire world. HEART SCIENCE JOURNAL publishes original research, reviews, brief reports, case reports, case series, editorial, and commentary. **Heart Science Journal** also publishes the special issues and abstracts of papers presented at the annual meeting of the Cardiological Society of Malang.

Peer Review Process

This journal uses double-blind review. All contributions will be initially assessed by the editor for suitability for the journal. Papers deemed suitable are then typically sent to a minimum of two independent expert reviewers to assess the scientific quality of the paper. It means that the identities of the authors are concealed from the reviewers, and vice versa. To facilitate this, please include the following separately: Title page (with author details): This should include the title, authors' names, affiliations, a complete address for the corresponding author including an e-mail address, running title, conflicts of interest, funding, acknowledgement, and author contribution. Blinded manuscript (no author details): The main body of the paper (including the references, figures, tables and any acknowledgements) should not include any identifying information, such as the authors' names or affiliations. The Editor is responsible for the final decision regarding acceptance or rejection of articles. The Editor's decision is final.

Open Access Policy

This journal provides immediate open access to its content on the principle that making research freely available to the public supports a greater global exchange of knowledge.

Heart Science Journal Secreteriat

Department of Cardiology and Vascular Medicine Universitas Brawijaya
dr. Saiful Anwar General Hospital - ICVCU 3rd Floor
Jl. Jaksa Agung Soeprapto No. 2, Malang, Indonesia - 65121
Tel/Fax: (+62341) 346 818

Editorial Board

Editor-in-chief:
Mohammad Saifur Rohman
Indonesia

Deputy Editor-in-chief:
Yoga Waranugraha
Indonesia

Jonny Karunia Fajar
Indonesia

Editorial Board Members:

Djanggan Sargowo
Indonesia

Indra Prasetya
Indonesia

Cholid Tri Tjahjono
Indonesia

Valerinna Yogibuana Swastika Putri, Indonesia

Sasmojo Widito
Indonesia

Dyah Wulan Anggrahini
Indonesia

Heny Martini
Indonesia

Saskia D Handari
Indonesia

Setyasih Anjarwani
Indonesia

Dwi Adi Nugroho
Indonesia

Budi Satrijo
Indonesia

Mifetika Lukitasari
Indonesia

Novi Kurnianingsih
Indonesia

Imam Suseno Bayuadi
Indonesia

Ardian Rizal
Indonesia

Koernia Kusuma Wardhana, Indonesia

Anna Fuji Rahimah
Indonesia

Artono Isharanto
Indonesia

International Editorial Board Members:

Salvatore Di Somma
Italy

Delvac Oceandy
United Kingdom

Gindo Tampubolon
United Kingdom

Asri Maharani
United Kingdom

Layout Editor :

Bunga Bella Pratiwi
Indonesia

Dion Setiawan
Indonesia

Alif Jayanti
Indonesia

Shalahuddin Suryo Baskoro
Indonesia

p-ISSN 2721 - 9984
e-ISSN 2721 - 9976

Heart Science Journal

Official Open Access Journal of Brawijaya Cardiovascular Research Center
Volume 5 • Issue 2 • April 2024 • page 1–91 DOI: http://dx.doi.org/10.21776/ub.hsj.2024.005.2

Table of Contents

Editorial

- Advancing Scholarship: HSJ Attains Scopus Indexing – Embarking on A New Scientific Journey 1
  Jonny Karunia Fajar
- The Current Strategy in Managing Congenital and Structural Heart Disease: Find and Treat them Appropriately 3
  Radityo Prakoso

Review Article

- Recognizing Total Anomalous Pulmonary Venous Drainage (TAPVD) from Natural History to the Supportive Imaging Modalities 5
  Fahreza Caesario, Valerinna Yogibuana Swastika Putri
- Clinical Features and Multimodality Diagnostic Tools of Pulmonary Hypertension 14
  Lukitasari Ayu Galuh Ardhi, Anna Fuji Rahimah, Heny Martini, Ardian Rizal
- Echocardiography Features in Patient Rheumatic Mitral Stenosis 23
  Nur Kaputrin Dwigustiningrum, Anna Fuji Rahimah, Wella Karolina, Heny Martini
- Cardioprotective Effect of Remote Ischemic Preconditioning: From Bench to Bedside 31
  Imam Mi'raj Suprayoga, Setyasih Anjarwani
- Sudden Cardiac Death in Young Age, What Should We Know? 38
  Icmi Dian Rochmawati, Ardian Rizal, Valerinna Yogibuana Swastika Putri, Indra Prasetya

Original Articles

- Impact of Strict and Lenient Heart Rate Control on Six-Minute Walk Test and Quality of Life in Atrial-Fibrillation Patients with Rheumatic Mitral Stenosis : Randomized Control Trial 44
  Nur Kaputrin Dwigustiningrum, Valerinna Yogibuana Swastika Putri, Ardian Rizal, Mohammad Saifur Rohman, Anna Fuji Rahimah, Adhika Prastya Wikananda, Yoga Waranugraha, Tri Astiawati, Fitranti Laitupa
- Effects of the Low-Dose Colchicine Regimen on Left Ventricular Adverse Remodeling and Systolic Function in Acute Myocardial Infarction Patients With Anterior ST Segment Elevation Undergoing Primary Percutaneous Coronary Intervention: A Randomized Controlled Trial 51
  Fahreza Caesario, Indra Prasetya, Mohammad Saifur Rohman, Budi Satrijo, Setyasih Anjarwani
- The Relationship Between Cha2ds2-Vasc Scores and The Degree of TIMI Flow in Patients with Acute St-Segment Elevation Myocardial Infarction Who Underwent Primary Percutaneous Coronary Intervention at Dr. Saiful Anwar Malang 57
  Muhammad Bayu Aji Saputra Sudarno, Sasmojo Widito, Setyasih Anjarwani, Novi Kurnianingsih, Evit Ruspiono

Case Reports

- How to Recognize and Overcome Pulmonary Hypertension Crisis During Patent Ductus Arteriosus Closure by Device in Adult 64
  Lukitasari Ayu Galuh Ardhi, Heny Martini
- Managing a Challenging Case: Transesophageal Echocardiography-Guided Transcatheter Closure of a large Secundum Atrial Septal Defect in a Pregnant Woman 67
  Emil Fathoni, Heny Martini, Anna Fuji Rahimah, Valerinna Yogibuana Swastika Putri
- Management of Pregnant Women with Atrial Septal Defect and Pulmonary Hypertension: A Case Report 72
  Arif Wicaksono, Heny Martini, Ardian Rizal, Anna Fuji Rahimah
- Navigating Complex Cardiovascular Pathologies: A Case Report on Aortic Arch Replacement in a Middle-Aged Male with Stanford A DeBakery I Aortic Dissection 77
  Muhammad Firdaus, Saskia Dyah Handari, Yan Efrata Sembiring
- Cracking The Case of The Cryptic Coronary: Diagnostic Strategies for Anomalous RCA Originating from LAD 82
  Pratiwi Indrihapsari, Budi Satrijo, Anna Fuji Rahimah
- Recurrent Orthodromic SVT AVRT with Multiple Accessory Pathway in WPW syndrome: Ablate All or Not? 86
  Indra Jabbar Aziz, Ardian Rizal

Contents list available at www.heartscience.ub.ac.id

Heart Science Journal

Journal Homepage : www.heartscience.ub.ac.id

Editorial

Advancing Scholarship: HSJ Attains Scopus Indexing – Embarking on A New Scientific Journey

Jonny Karunia Fajar[1*]

[1]Brawijaya Internal Medicine Research Center, Department of Internal Medicine, Faculty of Medicine, Universitas Brawijaya, Malang, Indonesia

ARTICLE INFO

Keyword :
Cardiovascular;
Heart Science Journal;
Indexing;
Scopus.

ABSTRACT

Following the inclusion of Heart Science Journal (HSJ) in the Scopus index, we present this announcement outlining our forward trajectory and strategies aimed at elevating the quality of HSJ. Since the outset of 2024, HSJ has been formally indexed in Scopus, marking a significant milestone in our journey. We extend profound appreciation to our authors, editorial team, and reviewers for their diligent efforts and steadfast dedication, pivotal in realizing this accomplishment. In our ongoing pursuit of enhancing journal quality, we extend a global invitation to authors to contribute their research endeavors to HSJ. In essence, HSJ embarks on a new chapter within Scopus, and we extend a cordial invitation to scientists worldwide to partake in this collaborative endeavor.

Introduction

The online journal platform, serving as an electronic repository and communication medium for scientific discourse, has undergone a remarkable evolution since the 1990s.[1] The contemporary landscape is marked by a proliferation of millions of such platforms worldwide, reflecting an exponential growth trajectory. Diverging from traditional library repositories, these digital platforms exhibit an unprecedented capacity to engage with and cater to the needs of the global scientific community at large.[2] This expanded accessibility transcends geographical and institutional boundaries, democratizing access to scholarly knowledge and facilitating collaboration on a global scale. Moreover, the advent of journal platforms has ushered in a new era of transparency in scientific communication, thereby fostering the equitable dissemination of knowledge across diverse socio-cultural contexts. By providing a centralized hub for the aggregation and dissemination of scholarly outputs, these platforms enhance the efficiency of information exchange and catalyze interdisciplinary collaboration.[3] Against this backdrop of innovation and progress, the establishment of Heart Science Journal (HSJ) by the Brawijaya Cardiovascular Research Center in early 2020 represents a seminal contribution to the ongoing evolution of scientific communication. This initiative underscores a commitment to harnessing the transformative potential of digital platforms to advance scientific inquiry and promote the dissemination of cardiovascular research findings to a global audience.

HSJ, established as a journal platform under the auspices of the esteemed Brawijaya Cardiovascular Research Center, ecompasses a broad spectrum of cardiovascular research domains. Encompassing clinical cardiology, interventional cardiology, intensive and acute cardiovascular care, vascular disease, echocardiography, pediatric cardiology, cardiovascular imaging, arrhythmia, cardiovascular prevention and rehabilitation, cardiovascular surgery, and pertinent animal studies, HSJ serves as an expansive repository for cutting-edge research contributions in the cardiovascular field. Positioned as a preeminent journal platform, our paramount objective is to attain indexing in Scopus, symbolizing acknowledgment and visibility within the global scholarly arena. This discourse elucidates the narrative surrounding our journal's successful integration into the Scopus index and articulates our future outlook and anticipations for the journal.

HSJ has been included in the Scopus indexing

Since the year 2024, the inclusion of HSJ within the Scopus indexing framework[4] has elicited a profound sense of satisfaction. This notable achievement, however, was the culmination of a prolonged and arduous journey. From its inception, HSJ has been steadfast in its commitment to upholding the highest standards of scholarly excellence. The endeavor to secure inclusion in the prestigious Scopus database was initiated in 2021, marking the commencement of a rigorous process of refinement and enhancement. In pursuit of this goal, a comprehensive array of measures was implemented to elevate various facets of the journal's operations. These efforts encompassed systematic improvements spanning website infrastructure, optimization of article quality, streamlining of editorial procedures, refinement of peer review protocols, and meticulous post-peer review adjustments. Concurrently, strategic revisions were made to journal policies to fortify the quality assurance framework. The collective dedication and tireless endeavors of the HSJ team bore fruit in early 2024 with the momentous announcement

* Corresponding author at: Brawijaya Internal Medicine Research Center, Department of Internal Medicine, Universitas Brawijaya, Malang, Indonesia
E-mail address: gembyok@gmail.com (J. F. Karunia).

https://doi.org/10.21776/ub/hsj.2024.005.02.1
Received 8 March 2024; Received in revised form 13 March 2024; Accepted 20 March 2024.
Available online 28 April 2024

of its acceptance for Scopus indexing.[4] This watershed moment stands as a testament to the unwavering commitment of HSJ to continuous improvement and scholarly advancement. It serves as a catalyst for further endeavors aimed at enriching the academic landscape and fostering the dissemination of high-quality research.

We express our deepest gratitude to our editorial team, reviewers, and authors for their unwavering dedication and hard work, which has culminated in the remarkable achievement of our journal being indexed in Scopus. Their collective efforts and commitment have played an indispensable role in realizing this significant milestone. It is undeniable that without the crucial contributions of every member of the HSJ team, this achievement may not have been possible. This accomplishment stands as a testament to the collaborative spirit and shared commitment to excellence that defines our journal's ethos. We extend our heartfelt appreciation to each individual involved in this journey, and we look forward to continuing our collective pursuit of scholarly excellence in the field of cardiovascular research.

The Future Trajectory of HSJ

Scopus, recognized as the foremost global authority in journal indexing, represents a coveted accolade pursued by numerous scholarly publications worldwide.[5] However, the pursuit of Scopus indexing is not devoid of challenges, with many indexed journals facing the risk of discontinuation.[6] This dichotomy underscores a landscape characterized by intense competition among journals striving for inclusion within the Scopus database. Against this backdrop, the recent integration of HSJ into the Scopus indexing framework signifies a significant achievement, emblematic of our commitment to facilitating the dissemination of high-quality research findings. In light of this milestone, we extend a universal invitation to researchers to submit their most exemplary scholarly endeavors to HSJ. Our commitment transcends mere solicitation, as we pledge steadfast adherence to rigorous peer review protocols, meticulously aligned with the foundational principles governing scholarly publication ethics and standards. Furthermore, we affirm the expertise and credibility of our editorial board and peer reviewers, ensuring comprehensive and authoritative evaluation of submissions spanning diverse disciplinary realms. Through these concerted endeavors, we aim to cultivate a scholarly milieu characterized by excellence and integrity, thereby fostering confidence among researchers in the quality and rigor of publications featured within our journal.

Conclusion

Since early 2024, HSJ has been indexed in Scopus. We extend our heartfelt gratitude to the dedicated efforts of our editorial team, reviewers, and authors whose contributions have been instrumental in achieving this accomplishment. With Scopus indexing, we aim to further enhance the visibility and impact of research published in HSJ. We invite researchers and scholars from around the globe to submit their research findings to HSJ, thereby fostering a collaborative and inclusive platform for the advancement of cardiovascular science.

Conflict of Interest

There is no conflict of interest.

References

1. Laakso M, Welling P, Bukvova H, Nyman L, Bjork BC, Hedlund T. The development of open access journal publishing from 1993 to 2009. PLoS One 2011;6:e20961.
2. Tao D, Demiris G, Graves RS, Sievert M. Transition from in library use of resources to outside library use: the impact of the Internet on information seeking behavior of medical students and faculty. AMIA Annu Symp Proc 2003;2003:1027.
3. Engeszer RJ, Sarli CC. Libraries and open access support: new roles in the digital publishing era. Mo Med 2014;111:404-7.
4. Title on scopus. Elsevier, 2024. (Accessed 16 February 2024, 2024, at https://www.elsevier.com/products/scopus.)
5. Sullo E. Scopus. J Med Libr Assoc 2007;95:367-8.
6. Cortegiani A, Ippolito M, Ingoglia G, Manca A, Cugusi L, Severin A, et al. Citations and metrics of journals discontinued from Scopus for publication concerns: the GhoS(t)copus Project. F1000Res 2020;9:415.

Heart Sci J 2024; 5(2): 3-4

Contents list available at www.heartscience.ub.ac.id

Heart Science Journal

Journal Homepage : www.heartscience.ub.ac.id

Editorial

The Current Strategy in Managing Congenital and Structural Heart Disease: Find and Treat Them Appropriately

Radityo Prakoso[1*]

[1]Division of Pediatric Cardiology and Congenital Heart Disease, Department of Cardiology and Vascular Medicine, National Cardiovascular Centre Harapan Kita, Universitas Indonesia, Jakarta, Indonesia

ARTICLE INFO

Keyword :
Fetal Intervention;
Fontan;
Non-Fluoroscopy;
Percutaneous;
Reverse Potts;
Rheumatic Heart Disease;
RVOT Stenting.

ABSTRACT

Significant progress has been made in diagnosing and treating congenital heart defects (CHDs) over the past five decades. Notable advancements include pulse oximetry screening for critical CHDs in newborns and percutaneous, catheter-based procedures, improving outcomes even in developing nations. Recent studies demonstrate favorable outcomes with device closure of acyanotic CHDs, with non-fluoroscopy techniques adopted to minimize radiation risks. Positive results are observed with right ventricular outflow tract (RVOT) stent palliation for late-presenting cyanotic congenital heart diseases such as tetralogy of Fallot (TOF). Novel interventions like reverse Potts shunt anastomosis show promise in managing pediatric pulmonary arterial hypertension (PAH), while prophylactic treatments effectively reduce postoperative arrhythmias. Fontan procedure significantly enhances survival rates for individuals with single functional ventricles, although challenges arise with aging populations. In developed countries, fetal cardiac interventions utilizing advanced imaging techniques allow for early detection and preventive interventions, reducing secondary complications.

Over the past five decades, significant progress has been made in diagnosing and treating congenital heart defects (CHDs). Notable advancements include the introduction of pulse oximetry screening for critical CHDs in newborns prior to hospital discharge, alongside traditional diagnostic methods such as history-taking, physical examination, chest X-rays, and electrocardiograms. The utilization of percutaneous, catheter-based procedures and advanced surgical techniques has greatly improved outcomes, even in developing nations.[1-3]

Recent studies have demonstrated favorable outcomes with device closure of acyanotic CHDs, including atrial septal defect (ASD), ventricular septal defect (VSD), and patent ductus arteriosus (PDA).[4-7] Concerns over radiation exposure, especially in children and pregnant women, have led to the adoption of non-fluoroscopy techniques for defect closure, with comparable efficacy and safety to traditional methods. In our effort to mitigate radiation exposure during transcatheter closure procedures for congenital heart defects, we have implemented a policy promoting non-fluoroscopy techniques, even in challenging cases such as multiple ventricular septal defects (VSDs) and in pregnant women with atrial septal defect (ASD) with pulmonary hypertension.[4,5] This strategic shift aims to minimize the potential risks associated with radiation exposure, particularly for vulnerable populations. In one study demonstrated by Siagian et al.[6], echocardiography-guided closure of patent ductus arteriosus (PDA) is a viable alternative to fluoroscopy-guided procedures. Their study, involving 30 patients who underwent non-fluoroscopy closure, revealed that echocardiography-guided closure is comparable in efficacy to fluoroscopy-guided closure, despite potential limitations in visualization. Importantly, the procedural time for echocardiography-guided PDA closure did not differ significantly from fluoroscopy-guided closure, indicating that reliance solely on echocardiography did not compromise procedural efficiency.

Another problem in developing country is rheumatic heart disease (RHD), often leading to mitral stenosis (MS). Percutaneous balloon mitral valvotomy (PBMV) has emerged as a preferred treatment over surgical options due to its superior outcomes and shorter hospital stays. However, challenges persist, particularly in special populations such as pregnant women and those with arrhythmias like atrial fibrillation.[8] Late presentations cases in cyanotic congenital heart disease such as tetralogy of Fallot (TOF) are also common in developing countries, posing complex challenges. Recent studies suggest positive outcomes with right ventricular outflow tract (RVOT) stent palliation, leading to improvements in oxygen saturation and ventricular function. Despite advancements in diagnostic technologies and a deeper comprehension of the ailment compared to previous centuries, instances of delayed presentations persist. Late presentations are particularly prevalent in developing countries, exacerbating the complexity of the issues. Traditionally, patients with uncorrected Fallot physiology who present late were solely managed conservatively with medication, especially when significant desaturation and diminished ventricular function were present. We demonstrated that there was a significant improvement in patients' saturation, rising from an initial mean of 58.56% ± 19.03% to 91.03% ± 8.98% ($p < 0.001$), along with an increase in their left ventricular ejection fraction (LVEF) from 64.00% ±

* Corresponding author at: Department of Cardiology and Vascular Medicine, National Cardiovascular Centre Harapan Kita, Universitas Indonesia, Jakarta, Indonesia
E-mail address: karajanh70@gmail.com (R. Prakoso).

https://doi.org/10.21776/ub/hsj.2024.005.02.2
Received 10 March 2024; Received in revised form 13 March 2024; Accepted 15 March 2024.
Available online 28 April 2024

18.21% to 75.09% ± 12.98% (p = 0.001). Notably, three patients experienced substantial enhancements in their LVEF, with values rising from 31% to 55%, 31% to 67%, and 26% to 50%. The median duration of hospital stay was 8 days (range: 2-35 days), with a median intensive care unit (ICU) stay of 2 days (range: 0-30 days). The median interval from right ventricular outflow tract (RVOT) stent palliation to total repair was 3 months (range: 1-12 months).[3,9]

Pediatric pulmonary arterial hypertension (PAH) remains a progressive disease with limited treatment options. Novel interventions, such as the reverse Potts shunt anastomosis, show promise in converting severe PAH to a more manageable condition.[10] Junctional Ectopic Tachycardia (JET) is a common postoperative arrhythmia, particularly following congenital heart surgery. Prophylactic treatments, including dexmedetomidine, amiodarone, and magnesium sulfate, have shown efficacy in reducing JET incidence, with dexmedetomidine potentially offering additional benefits.[11] Fontan procedure remains a cornerstone treatment for individuals with single functional ventricles, boasting enhanced survival rates over the years. Following the inception of the Fontan technique, the 10-year survival rate post-surgery has surged from a mere 50% to its present 90%. This procedure has significantly elevated survival prospects for individuals born with single ventricles. Nonetheless, as this population ages, the physiological challenges become more apparent. Bosentan has exhibited promise in enhancing exercise tolerance and overall quality of life among Fontan patients, although additional research is warranted to refine treatment approaches.[12]

In developed countries, fetal cardiac intervention and surgery have become increasingly common. With advanced fetal imaging techniques like echocardiography and magnetic resonance imaging, CHDs can often be detected as early as the 12th week of gestation. Early intervention during fetal development can prevent secondary cardiac complications, such as ventricular hypoplasia. Fetal interventions, particularly for conditions like fetal aortic stenosis and pulmonary atresia with an intact ventricular septum, have shown promise.[13,14]

Conflict of Interest

There is no conflict of interest.

References

1. Baumgartner H, Backer JD, Babu-Narayan SV, et al. 2020 ESC guidelines for the management of adult congenital heart disease. *Eur Heart J.* 2021; 42: 563-645. doi: 10.1093/eurheartj/ehaa554

2. Stout KK, Daniels CJ, Aboulhosn JA, et al. 2018 AHA/ACC guideline for the management of adults with congenital heart disease: a report of the American College of Cardiology/American Heart Association task force on clinical practice guidelines. *Circulation.* 2019;139:e698–e800. doi: 10.1161/CIR.0000000000000603

3. Prakoso R, Kurniawati Y, Siagian SN, Sembiring AA, Sakti DDA, Mendel B, Pratiwi I, Lelya O, Lilyasari O. Right ventricular outflow tract stenting for late presenter unrepaired Fallot physiology: a single-center experience. Front. Cardiovasc. Med. 2024;11:1340570. doi: 10.3389/fcvm.2024.1340570

4. Prakoso R, Ariani R, Mendel B, Lilyasari O. Transoesophageal echocardiography-guided balloon-assisted percutaneous closure of a large secundum atrial septal defect in a pregnant woman: a case report. Eur Heart J Case Rep. 2024 Jan 6;8(1):ytae014. doi: 10.1093/ehjcr/ytae014. PMID: 38274706; PMCID: PMC10810588.

5. Siagian SN, Prakoso R, Mendel B, Hazami Z, Putri VYS, Zulfahmi, Sakti DDA, Kuncoro AS. Transesophageal echocardiography-guided percutaneous closure of multiple muscular ventricular septal defects with pulmonary hypertension using single device: A case report. Front Cardiovasc Med. 2023 Mar 23;10:1093563. doi: 10.3389/fcvm.2023.1093563. PMID: 37034333; PMCID: PMC10076841.

6. Siagian SN, Prakoso R, Putra BE, Kurniawati Y, Lelya O, Sembiring AA, Atmosudigdo IS, Roebiono PS, Rahajoe AU, Harimurti GM, Mendel B, Christianto C, Setiawan M, Lilyasari O. Echocardiography-Guided Percutaneous Patent Ductus Arteriosus Closure: 1-Year Single Center Experience in Indonesia. Front Cardiovasc Med. 2022 May 23;9:885140. doi: 10.3389/fcvm.2022.885140. PMID: 35677684; PMCID: PMC9167953.

7. Mendel B, Amin BF, Prakoso R. Potency of non-fluoroscopy guided patent ductus arteriosus closure: a case report. SN Compr Clin Med 2021; 3: 2665-72

8. Habib F, Mendel B, Fauzan R, Nasution AN. Revisiting percutaneous balloon mitral valvotomy technique and safety in various population: an evidence-based case report and literature review. Front Cardiovasc Med. 2024 Jan 26;11:1334444. doi: 10.3389/fcvm.2024.1334444. PMID: 38343874; PMCID: PMC10853446.

9. Prakoso R, Agita Sembiring A, Dwisepto Aulia Sakti D, Mendel B, Lilyasari O. Double stenting in 19-year-old patient with tetralogy of Fallot with prior fractured stent. J Am Coll Cardiol Case Rep. 2022;4(20):1375–8. doi:10.1016/j.jaccas.2022.07.043

10. Mendel B, Christianto C, Angellia P, Holiyono I, Prakoso R, Siagian SN. Reversed Potts Shunt Outcome in Suprasystemic Pulmonary Arterial Hypertension: A Systematic Review and Meta-Analysis. Curr Cardiol Rev. 2022;18(6):e090522204486. doi: 10.2174/1573403X18666220509203335. PMID: 35538823; PMCID: PMC9893152.

11. Mendel B, Christianto C, Setiawan M, Prakoso R, Siagian SN. A Comparative Effectiveness Systematic Review and Meta-analysis of Drugs for the Prophylaxis of Junctional Ectopic Tachycardia. Curr Cardiol Rev. 2022;18(1):e030621193817. doi: 10.2174/1573403X17666210603113430. PMID: 34082685; PMCID: PMC9241111.

12. Mendel B, Christianto, Setiawan M, Siagian SN, Prakoso R. Pharmacology Management in Improving Exercise Capacity of Patients with Fontan Circulation: A Systematic Review and Meta-analysis. Curr Cardiol Rev. 2022;18(5):34-49. doi: 10.2174/1573403X18666220404101610. PMID: 35379155; PMCID: PMC9896416.

13. Mendel B, Kohar K, Amirah S, Vidya AP, Utama KE, Prakoso R, Siagian SN. The outcomes of fetal aortic valvuloplasty in critical aortic stenosis: A systematic review and meta-analysis. Int J Cardiol. 2023 Jul 1;382:106-111. doi: 10.1016/j.ijcard.2023.03.050. Epub 2023 Mar 29. PMID: 36996909.

14. Mendel B, Kohar K, Yumnanisha DA, Djiu RJ, Winarta J, Prakoso R, et al. Impact of fetal pulmonary valvuloplasty in in-utero critical pulmonary stenosis: A systematic review and meta-analysis. Int J Cardiol CHD. 2024; 15(2024): 100485

Contents list available at www.heartscience.ub.ac.id

Heart Science Journal

Journal Homepage : www.heartscience.ub.ac.id

Review Article

Recognizing Total Anomalous Pulmonary Venous Drainage (TAPVD) from Natural History to the Supportive Imaging Modalities

Fahreza Caesario[1*], Valerinna Yogibuana Swastika Putri[2]

[1]Brawijaya Cardiovascular Research Center, Department of Cardiology and Vascular Medicine, Faculty of Medicine, Universitas Brawijaya, Malang, Indonesia.
[2]Department of Cardiology and Vascular Medicine, Faculty of Medicine, Universitas Brawijaya, Malang, Indonesia.

ARTICLE INFO

Keyword :
Congenital Heart Disease;
TAPVD;
Venous System Anomalies.

ABSTRACT

Congenital Heart Disease (CHD) prevalence was 8 until 9 for each thousand live births, and among all of the CHD, there is in one of condition that involved the malformation of the venous system that called Total Anomalous Pulmonary Venous Drainage (TAPVD). TAPVD can be found and to be diagnosed in all ages, not only in the childhood era. Adult individuals with TAPVD are susceptible to being misdiagnosed as having a significant secundum atrial septal defect if the condition is not known or suspected. A systematic history taking, physical examination, and another supportive imaging modalities is needed to ensure this structural anomaly.

1. Introduction

Congenital Heart Disease (CHD) prevalence was 8 until 9 for each thousand live births. According to estimates, cardiovascular defects play a role in 35% of infant mortality resulting from congenital malformations.[1] Among all of the CHD, there is only one condition that involved the malformation of the venous system that called Total Anomalous Pulmonary Venous Drainage (TAPVD) with the other last word is Connection (TAPVC) or Return (TAPVR). The incidence is rare and contribute 0.7 – 1.5% of all CHDs.[2] In Indonesia, data from Harapan Kita National Heart Center (PJN-HK), during 2006 there were 8 cases (5 males and 3 females) or around 0.7% of the total CHD cases.[3]

False connections between the four pulmonary veins and the systemic vein anatomy are the disease's primary defining feature, not to their natural estuary which is the left atrium. Beside it cause the pathological mixing of intracardiac blood, the complication also could be a serious problem and fatal such as the pulmonary vein stenosis.[4] TAPVD can be found and yet to be diagnosed in all ages, not only in the childhood era. Adult individuals with TAPVD are susceptible to being misdiagnosed as having a significant secundum atrial septal defect if the condition is not known or suspected.[5] This article review will describe and explain how to recognize and diagnose TAPVD from the natural history until the eligible supporting examination.

2. Definition

Wilson described TAPVD in the 17th century, a heart shape in which the superior vena cava interacts with a branch created by the two veins leaving the lungs. It comprises 25% of New England Regional Infant Cardiac Program patients.[6,7] According to another source, Friedkowsky initially described TAPVD in 1868, although the condition was not recognized until 1942.[3]

TAPVD refers to the absence of direct vein-to-atrium connection between the pulmonary veins (PV) and the left atrium (LA).[8] Patients with TAPVD may have aberrant veins that empty directly into the right atrium (RA) of the heart or through another systemic venous return channels.[9] Frequently obstructed systemic veins link the pulmonary veins to the right atrium. Deoxygenated and oxygenated blood mix as a result in the right atrium.[8]

Incidence and Etiology

TAPVD accounts for 1% to 1.5% of all congenital heart abnormalities, with a 4:1 male-to-female ratio for the infracardiac subtype, while the other forms are distributed uniformly between boys and girls.[10] The New England Regional Infant Cardiac Program ranks TAPVD as the twelfth most common congenital heart abnormality, affecting one in 17,000 live births. The Baltimore-Washington Infant Study found TAPVD in 1.5% of cardiovascular anomalies and one in 14,700 live births.[11] The patient's chance of surviving into adulthood is fewer than 7%, and it typically happens in supracardiac type without pulmonary venous blockage.[12] Four cases of untreated TAPVD detected after the age of 60 have been reported; three of them received effective surgery.[13] A report from China also represent adult female patient with asymptomatic TAPVD until her 46th year because of palpitations with dyspneu on effort (DOE) caused by atrial arrythmia.[14]

TAPVD is a cardiovascular anomaly in Holt-Oram, Klippel-Feil, phocomelia, and Schacermann syndrome. Like many lesions, familial

* Corresponding author at: Brawijaya Cardiovascular Research Center, Department of Cardiology and Vascular Medicine, Faculty of Medicine, Universitas Brawijaya, Malang, Indonesia.
E-mail address: fahrezacaesario@gmail.com (F. Caesario).

https://doi.org/10.21776/ub/hsj.2024.005.02.3
Received 26 July 2023; Received in revised form 28 July 2023; Accepted 9 August 2023.
Available online 28 April 2024

clustering occurs, and one report supports autosomal dominant inheritance. The Baltimore-Washington Infant Study suggests mother teratogen exposure in the first three months of pregnancy. According to a 2004 reanalysis of that dataset, mother exposures were inconclusive while paternal lead exposure before conception was completely aberrant.[11] 30% of TAPVD patients have heterotaxy syndrome, according to hospital postnatal surgical repair research. Right atrial isomerism (RAI) often occurs when the LA for PV connection is not functioning. Whole-exome sequencing and linkage mapping using polymorphic microsatellite markers have revealed ACVRL1, SGCD, 4p13-q12, ANKRD1, and other probable disease-driven genes. This genetic etiology of TAPVD is still popular.[9]

Embriology

Understanding the anatomical anomalies requires understanding of the pulmonary venous development (Fig. 1). The first embryonic organ to develop is the fetal cardiovascular system at six weeks gestation. The dual cardinal veins, umbilical veins, and vitelline veins fuse and degenerate during systemic venous circulation development, which is more difficult than pulmonary venous development.[9]

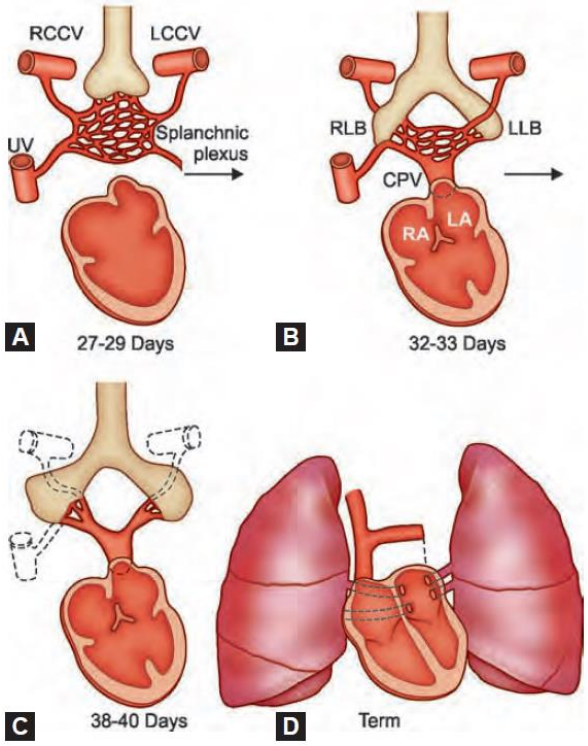

Figure 1. Development of pulmonary veins : (A) The splanchnic plexus, or foregut vascular plexus, entwines with the primordial lung lobes or buds during 27–29 days of gestation. (B) At the end of the first month of pregnancy, the common pulmonary vein connects the pulmonary venous plexus to the sinoatrial region of the heart; (C) Then, the splanchnic and pulmonary plexuses involute; and (D) The left atrium and the CPV coalesce, allowing the pulmonary veins to connect to the left atrium directly and individually.[8]

The atresia or failure of the common pulmonary vein to enter the left atrium is the underlying cause of TAPVD. (Fig. 2) Persistent cardinal or umbilico-vitelline vein connections cause most TAPVD. After primordial connections are lost, common pulmonary vein atresia might leave the pulmonary veins in a blind alley. Pulmonary venous hypertension pressure is often unrelieved due to poor paravertebral and splanchnic plexus-pulmonary vein connections.[15]

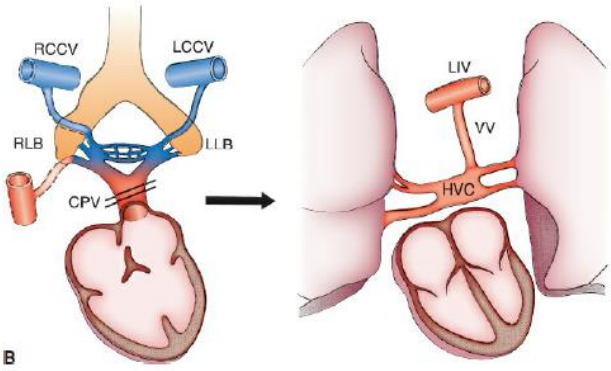

Figure 2. Embryologic basis of TAPVD : this pathology occurs when the pulmonary venous plexus does not normally communicate with the common pulmonary vein before regression of connections with the splanchnic venous system.[16]

Anatomy and Classification

Various pulmonary vein drainage abnormalities can cause substantial clinical complaints. Understanding the nomenclature of pulmonary vein abnormalities is crucial. A closed mitral valve and an intact inter-atrial septum cause aberrant venous drainage into the systemic veins. When the pulmonary veins enter the left atrium physically, then this should not be regarded as an anomaly of the pulmonary vein. [11]

If the pulmonary vein drains somewhere other than the left atrium, it is abnormal. Morphology of left atrium and left-sided atrium must be distinguished. All four pulmonary veins enter the superior side of the right atrium with the morphology of right atrial appendage, which may be on the left. Thus, pulmonary venous drainage is always abnormal in right atrial isomerism, independent of heart connection.[11]

Several categorization methods have been presented to describe the various kinds of TAPVD. According to the classification method proposed by Darling et al., TAPVD is categorized based on the anatomical site of the abnormal connection.[8] Darling's classification, first introduced in 1957, and classified TAPVD into four categories (Fig. 3) according to the sites where the abnormal connection occurs.[9]

Smith in 1961, proposed an additional categorization, which may be separated into two distinct categories : supradiaphragmatic without pulmonary venous obstruction, and infradiaphragmatic with pulmonary venous obstruction.[17] These two categories can be distinguished by the existence of venous blockage and the relationship between the aberrant drainage anastomosis and the diaphragm.[9]

Supracardiac, cardiac, infracardiac, and mixed are Darling's four categories. Most cases are supracardiac. In 45-55% of cases of total anomalous pulmonary venous drainage (TAPVD), the confluent artery drains into the innominate vein or the right or left SVC. The pulmonary veins (PV) are horizontally connected to the right atrium (RA) either via the coronary sinus (CS) or at the posterior wall of the RA in this cardiac type. 20%–30% of TAPVD patients have cardiac type. In cardiovascular anatomy, the infracardiac type occurs when the pulmonary veins (PVs) converge to form a vertically oriented structure that joins the portal vein or one of its branches, such as the ductus venosus, hepatic vein, or inferior vena cava (IVC), caudally. 13%–25% of these events occur. Fewer than 10% of people have the mixed subtype, which drains right and left pulmonary tributaries at two or more levels.[9] According to a 15-year cohort research conducted in Taiwan, the prevalence rates for the four kinds are as follows: Type I accounts for 42.3%, Type II 39.8%, Type III 12.8%, and Type IV 5.1%.[18]

Due to pulmonary venous return pathway obstruction, most TAPVD patients with supracardiac, cardiac, and infracardiac types will develop pulmonary hypertension. Whether ASD or PFO, TAPVD individuals have an inter-atrial link. Most inter-atrial connection have adequate hemodynamic flow.[10]

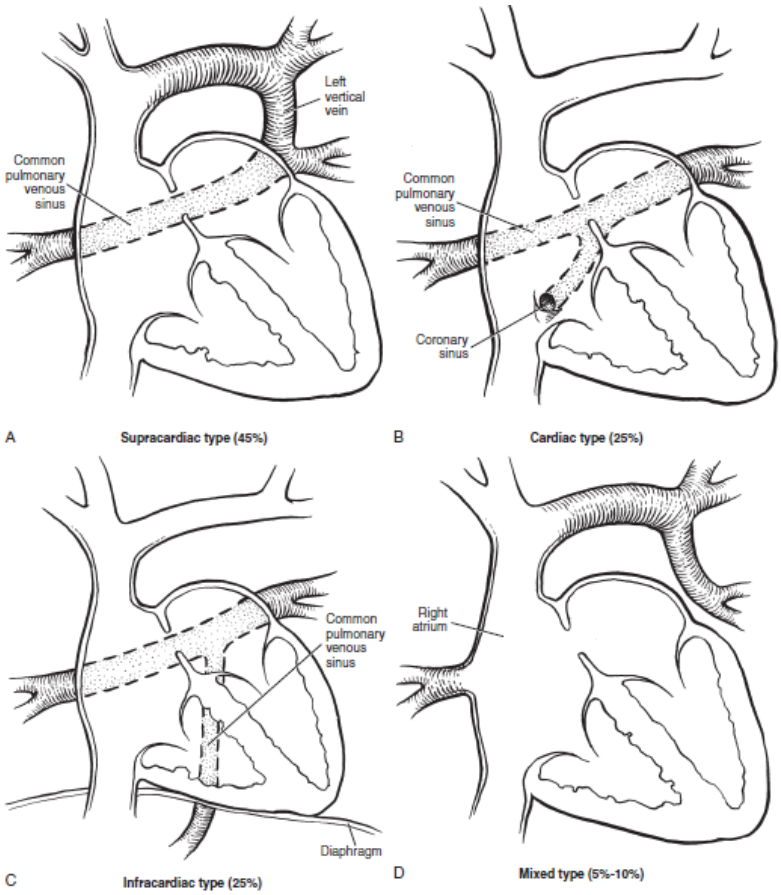

Figure 3. Types of TAPVD: (A) Supracardiac TAPVD (Type I); (B) Cardiac TAPVD (Type II); (C) Infracardiac TAPVD (Type III); (D) Mixed TAPVD (Type IV).[6]

TAPVD has been linked to transposition of the great arteries (TGA), tetralogy of Fallot, univentricular, truncus arteriosus, tricuspid atresia, hypoplastic left heart syndrome (HLHS), pulmonary atresia, and coarctation of the aorta.[16]A 40-years French study studied heart lesions in 180 TAPVD patients and found that 43% supracardiac, 27% intracardiac, and 17% infracardiac. 33 patients (18.3%) had cardiac lesions, including ventricular septal defects (15), abnormal systemic venous return (5), cor triatriatum (3), aortic coarctations (2), coronary anomalies (2), and 6 additional cardiac anomalies.[19]

- Supracardiac Type TAPVD (Type I)

The left vertical vein drains into the left brachiocephalic vein in supracardiac TAPVD. Superior vena cava-azygos vein couplings are rare.[6] The four pulmonary veins converge in the horizontal vein posterior to the left atrium. The horizontal vein's vertical vein ascends through the left para-vertebral cleft and meets the left brachiocephalic vein to drain into the superior vena cava. This anatomy is snowman-like.[11]

Supracardiac TAPVD's abnormality channel occludes based on vertical vein placement. Vertical veins crossing the left pulmonary artery anteriorly rarely blocked. When the vertical vein crosses the left pulmonary artery and left bronchus, the vertical venous canal narrows, narrowing the bronchopulmonary gap.[12] In supracardiac TAPVD, the pulmonary veins connect straight to the SVC. Rarely, supracardiac TAPVD obstructs. ASD survival requires a right-to-left shunt.[8]

- Cardiac Type TAPVD (Type II)

The right atrium's coronary sinus drains to pulmonary veins in cardiac TAPVD. Persistent Thebesian valves can cause pulmonary vein-coronary sinus blockage.[11] Obstruction is rare in the literature, although 42.8% of 7 cardiac type TAPVD patients in Turky had pulmonary vein pathway obstruction. Obstructive cardiac TAPVD was second in incidence after infracardiac.[20] A direct connection from the pulmonary vein to the right atrium is rare, except in cases of right atrial isomerism.[11]

- Infracardiac Type TAPVD (Type III)

Pulmonary veins discharge into the portal vein, ductus venosus, hepatic vein, or inferior vena cava in infracardiac TAPVD. The esophageal gap lets the common pulmonary vein to cross the diaphragm.[10] Portal veins drain into the pulmonary veins. Pulmonary veins draining into the portal venous system nearly always cause closed ductus venosus occlusion. Blood enters systemic veins through liver tissue when the ductus venosus shuts.[8] The highest incidence of obstruction is in this TAPVD type, for about 78%.[21] For instance, blocked vertical vein drainage causes acute lung congestion and significant respiratory distress that resists traditional medical treatment.[22] Due to high portal venous pressures, the infracardiac type may cause a fusiform or saccular portal aneurism.[21]

- Mixed Type TAPVD (Type IV)

The rarest type, it occurs less than 5% of the time. It causes other non-cardiac problems. The mixed type often has many obstructions and other heart structural problems. The most common mixed connections connect the right pulmonary veins to the right atrium or coronary sinus and the left to a vertical vein that goes to the left innominate vein.[8]

Patophysiology

All venous blood—systemic and pulmonary—goes to the right atrium. TAPVD patients need right-left heart chamber connectivity to survive. Inter-atrial communication is essential in this scenario. Prenatally, systemic and pulmonary veins flow slightly more to the right atrium because to reduced lung blood flow. Thus, intra-atrial flow stimulation is modest.[16]

Inter-atrial flow restricts blood entering the left atrium, limiting systemic output. As the baby grows, pulmonary blood flow increases. Right atrial pressure increases congestive pulmonary venous pressure. Patent ASDs and PFOs improve interatrial communication. Mixed venous blood allocation depends on atria and ventricle compliance and pulmonary and systemic circulatory system resistance in this physiological state. Pulmonary vein blockage greatly influences pulmonary vascular cross-section.[16]

Inter-atrial communication sends blood from the right to the left atrium. This occurs because the left atrium's pressure is low and its volume depends on right atrial blood flow. In TAPVD with an infracardiac connection, the inferior vena cava oxygenates the right atrium. Due to inferior blood flow, this blood bypasses the right ventricle and enters the left atrium. Systemic arteries are oxygenated more than pulmonary arteries in this stage. The supracardiac kind of TAPVD drains oxygenated veins into the superior vena cava, boosting blood flow to the right ventricle through the tricuspid valve.[11+]

- TAPVD Without Pulmonary Vein Obstruction

The similar resistance of the vascular cross-sections in both circulatory systems balances blood flow between the pulmonary and systemic circulations in neonates. The pulmonary vascular bed develops in the first week, lowering pulmonary vascular resistance. Mixed blood flows into the pulmonary circulation. Pulmonary blood flow is usually 3–5 times systemic blood flow, which is normal.[15]

The differential distribution of well-saturated pulmonary blood and desaturated systemic venous blood allows the right atrial to reach 90% oxygen saturation. The right atrium receives 3–5 well-saturated lungs blood every unit of desaturated systemic venous blood. Atrium mixing maximizes saturation. The right atrium, pulmonary artery, left atrium, left ventricle, and aorta should have equal oxygen saturation. Right ventricular hypertrophy and pulmonary artery dilatation usually progress. Inter-atrial communication in TAPVD patients without pulmonary venous obstruction affects pulmonary blood flow, pressure, and resistance. Pulmonary arteriole medial hypertrophy and intimal proliferation worsen pulmonary hypertension in the 30s and 40s[16]

- TAPVD With Pulmonary Vein Obstruction

The pulmonary vascular system receives pressure from blocked pulmonary veins. An imbalance between capillary hydrostatic pressure and blood osmotic pressure causes pulmonary edema. Physiological processes prevent pulmonary edema. These mechanisms include increased pulmonary lymphatic flow, bypass pulmonary venous channels, and reflexive pulmonary arteriole constriction. Pulmonary hypertension, left ventricular hypertension, and right heart failure can result from pulmonary arteriole constriction.[16]

Systemic artery oxygen saturation can drop 20-30%. Tissue hypoxemia and metabolic acidosis occur from decreased systemic oxygen saturation and output. Small pulmonary veins and arteries change with pulmonary vein occlusion, increasing peripheral vascular resistance.[15]

Clinical Manifestations

Clinical Manifestations in TAPVD Without Pulmonary Vein Obstruction

Birth is usually symptomless. The Northern Great Plains Registry of Congenital Heart Disease found that 56% of 74 TAPVD patients without pulmonary vein obstruction exhibited symptoms in the first month and the rest after one year. His first symptoms are tachypnea and trouble swallowing. These babies are malnourished and have frequent respiratory infections. 6 months old cardio-respiratory failure.[16]

Cyanosis may not be clinically noticeable. Patients with heart failure symptoms and survivors who develop pulmonary vascular alterations may have a distinct disease. TAPVD patients without pulmonary vein blockage often experience congestive heart failure.[10]

Due to volume overload, the conspicuous right heart often heaves. Cardiac impulse peaks at the xiphoid process and lower left sternal border. Multiple cardiac sounds—sometimes quadruple or quintuple rhythms—are another sign.[10]

The first cardiac sound is intense and clear, often accompanied by an ejection click in early systole. Breathing does not affect the second cardiac sound's broad split. Pulmonary component of second heart sound is stronger. The apex always has the third heart sound. Seniors may have a fourth heart sound.[16]

Grade 2 to 3/6 systolic cardiac murmurs are most intense in the pulmonary auscultation zone (parasternal 2 upper left). A tricuspid valve systolic murmur indicates regurgitation. A tricuspid diastolic murmur indicates relative stenosis. The left innominate vein is linked to total anomalous pulmonary venous drainage (TAPVD) of the supracardiac subtype, which causes a venous hum. Unlike the physiological venous hum, this murmur does not get louder during diastole and stays the same regardless of location or jugular vein pressure. Hepatomegaly and bilateral leg edema indicate right heart failure affecting other organs on the physical exam.[16]

Clinical Manifestations in TAPVD with Pulmonary Vein Obstruction

In supracardiac and infracardiac TAPVD, the left vertical vein is entrapped in the bronchopulmonary slit structure and the ductus venosus shuts, driving infracardiac blood flow to the liver first. The Northern Great Plains Registry of Congenital Heart Disease found 43 TAPVD cases with pulmonary vein obstruction. 72% have symptoms. TAPVD patients with pulmonary venous blockage experienced no symptoms for 12 hours, unlike neonates with respiratory distress syndrome. Dyspnea, problems when eating, and cardiorespiratory failure precede symptoms.[16]

Cyanosis and severe shortness of breath are common in 2–4.5-month-old TAPVD patients with pulmonary vein blockage. When the anomalous connection is below the diaphragm (infracardiac), straining or swallowing can worsen cyanosis and shortness of breath due to impaired pulmonary venous blood flow due to increased intra-abdominal pressure or stretching the esophagus to clamp the hiatus-penetrated pulmonary veins.[16]

Compared with the severe and life-threatening symptoms, the physical cardiovascular findings are minimal. Cardiac enlargement was not seen in the absence of significant right heart heaves. The second heart sound is usually separate, and the pulmonary component is amplified. Fine moist rales are found at the bases of the lungs. Hepatomegaly does not appear and edema of the limbs is very rare.[16]

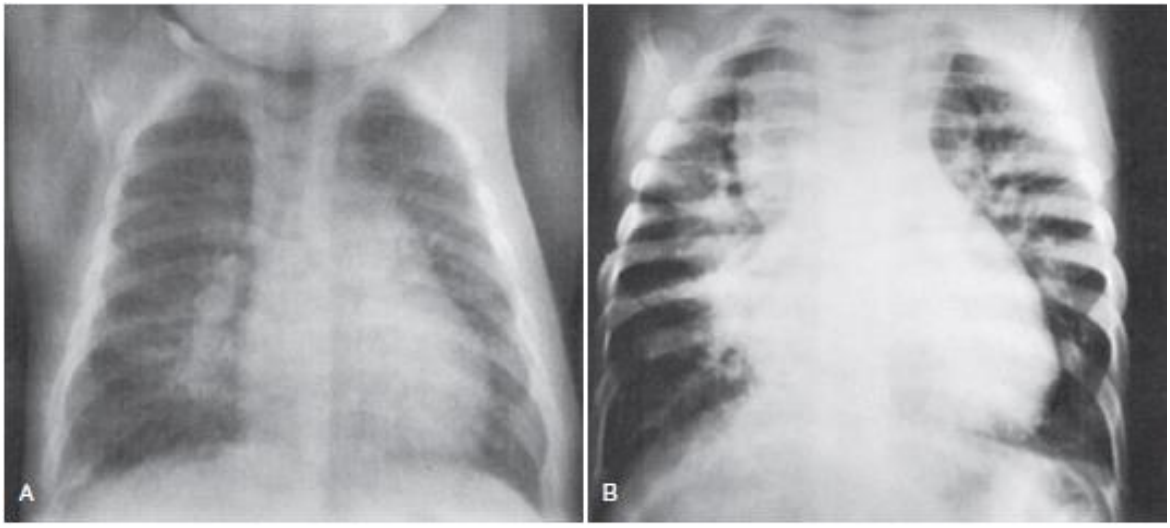

Figure 4. Chest radiographs of patients TAPVD; (A) with pulmonary obstruction (common pulmonary venous obstruction is evident as a diffuse haziness or, in its severe forms, a “ground glass” appearance); (B) without pulmonary obstruction (TAPVC to the left brachiocephalic vein have a characteristic “figure-ofeight” or “snowman” configuration on the chest radiograph).[6]

Electrocardiography

Investigation outcomes may vary amongst TAPVD patients with and without pulmonary vein blockage. TAPVD without pulmonary vein obstruction causes a tall P wave in lead II due to right atrium dilatation and right cardiac axis shift. Incomplete right bundle branch obstruction causes volume overload and right cardiac hypertrophy.[15] TAPVD with pulmonary venous blockage seldom causes right atrium hypertrophy. Tall R waves can be seen in larger right heart images.[10]

Chest X-Ray

Lung markings in TAPVD without pulmonary vein occlusion indicate higher pulmonary blood flow. Pulmonary arteries dominate the right atrium and right ventricle. No left heart enlargement. TAPVD types also exhibit unique traits. TAPVD cardiac X-rays show a figure 8 or snowman shape with a supracardiac connection draining from the left innominate vein. The vertical vein, left inferior border, left inferior vena cava, and right superior border comprise this image (Fig. 4B).[10] TAPVD with pulmonary vein blockage seldom enlarges the heart. Pulmonary edema is evident in the lung fields. Chest X-rays are unreliable because they resemble pneumonia or hyaline membrane disease. (Fig. 4A).[16]

Trans Thoracal Echocardiography (TTE)

Delineating the pulmonary venous connections to the left atrium (LA) requires clear two-dimensional imaging from many imaging windows. Spectral and color Doppler imaging shows LA flow from each pulmonary vein. Right-sided volume, especially without interatrial connection, suggests APVC.[23]

In newborns, subcostal frontal and sagittal images show pulmonary vein connections beautifully. These images help evaluate the atrial septum because the sound plane is perpendicular to it. Leftward angulation on PSLA pictures shows how one or both left pulmonary veins connect to the LA. The cardiac border's posterior color flow enquiry shows these flows. The apical four-chamber figure shows how the right inferior and left inferior pulmonary veins are connected. When angulated anteriorly, the right upper vein connects to the left atrium dome. This depiction requires traveling away from the atrioventricular valve plane. The "crab" image helps identify all pulmonary veins that link to the left atrium. All transthoracic echocardiograms should contain this view. In normal children, this image shows the pulmonary veins well. Adult echocardiography labs rarely gain this perspective. (Fig. 5).[23] In TAPVD cases, echocardiography is used (1) to diagnose, (2) to describe and determine the size of the pulmonary veins individually, (3) to ensure that they are in a single venous confluence and not separate, (4) to describe and determine the size of the confluence and its relation to the left atrium, (5) to describe the left vertical vein and its relation to surrounding structures, and (6) to determine whether there is a confluence.[9]

TAPVD often shows right ventricle overvoltage. Right heart structures are dilated, the right atrium is larger, and the atrium septum protrudes left. Right ventricle bulges and compresses left ventricle, reducing its capacity. Pulmonary arteries dilate.[9]

In general, the venous canals of the supracardiac type of TAPVD are best viewed from the precordial side.[16] The most common connection of this type is with the left superior vena cava, with further features of drainage leading to a dilated left innominate vein and right superior vein. If you find this type, it can be described with a short-axis suprasternal view. Color flow mapping is a tool that helps in explaining the direction of flow from the left superior vena cava (Fig. 6A).[23]

The subcostal aspect of the venous canal is ideal for infracardiac TAPVD (Fig. 6B). Cardiac type TAPVD (Fig. 6C) involves dilated coronary sinuses seen from the subcostal, long parasternal, or apical 4-chamber sides. A coronary sinus-connected pulmonary vein is the key to this diagnosis.[16] In TAPVD patients, the mixed form is most common, with the left lung's pulmonary vein draining into the left superior vena cava and the other into the coronary sinus. These structures must be evaluated.[10]

In cases of TAPVD without pulmonary vein obstruction, it is important to doppler detection to trace each pulmonary vein, the connection of the pulmonary veins, and their insertion into the right cardiac structures for signs of obstruction (Fig. 7).[16] The low-velocity flows in the pulmonary veins will make vision easier if the Doppler scale is lowered. Therefore, a combination of color Doppler and pulsed and continuous wave spectral Doppler is used to assess pulmonary vein blockage.[15]

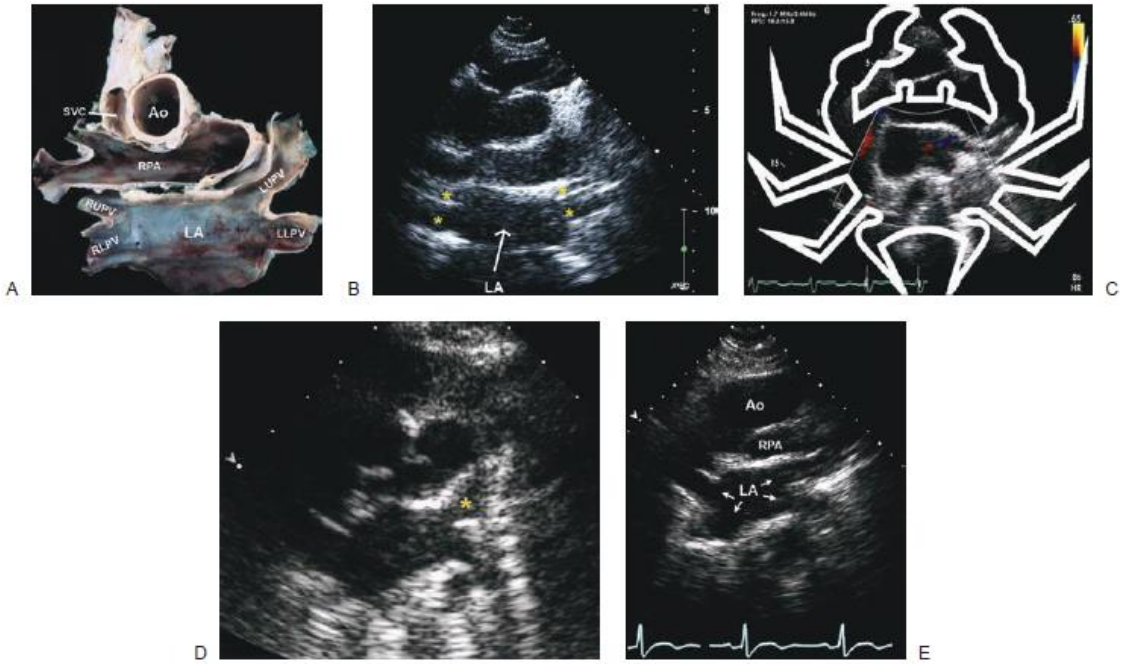

Figure 5. Crab views. (A) Pathology sample. (B) Four pulmonary veins were seen in two-dimensional echocardiography. (C) A suprasternal short-axis image includes a "crab" schematic overlay. (D) A suprasternal short-axis image reveals the left atrial appendage instead of the left upper pulmonary vein, indicating an imaging interpretation error. (E) The "crab" perspective is correct.[23]

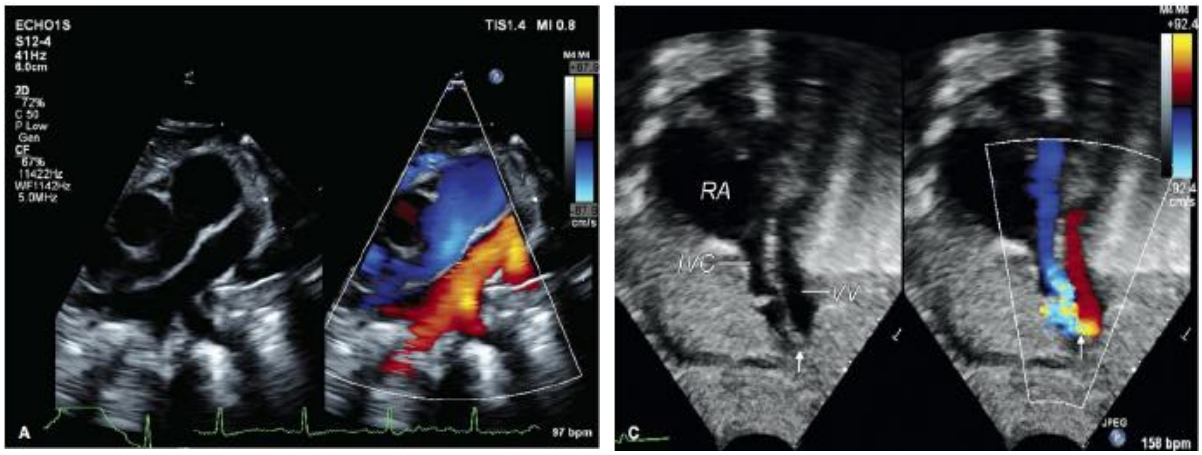

(A) (B)

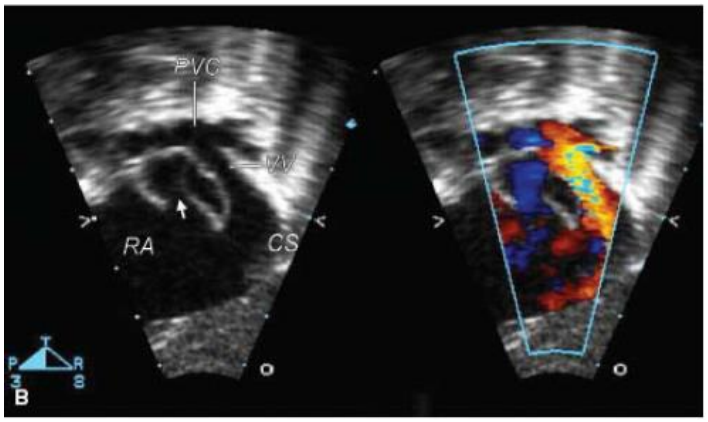

(C)

Figure 6. (A) Supracardiac, (B) Infracardiac, and (C) Cardiac type TAPVD.[16]

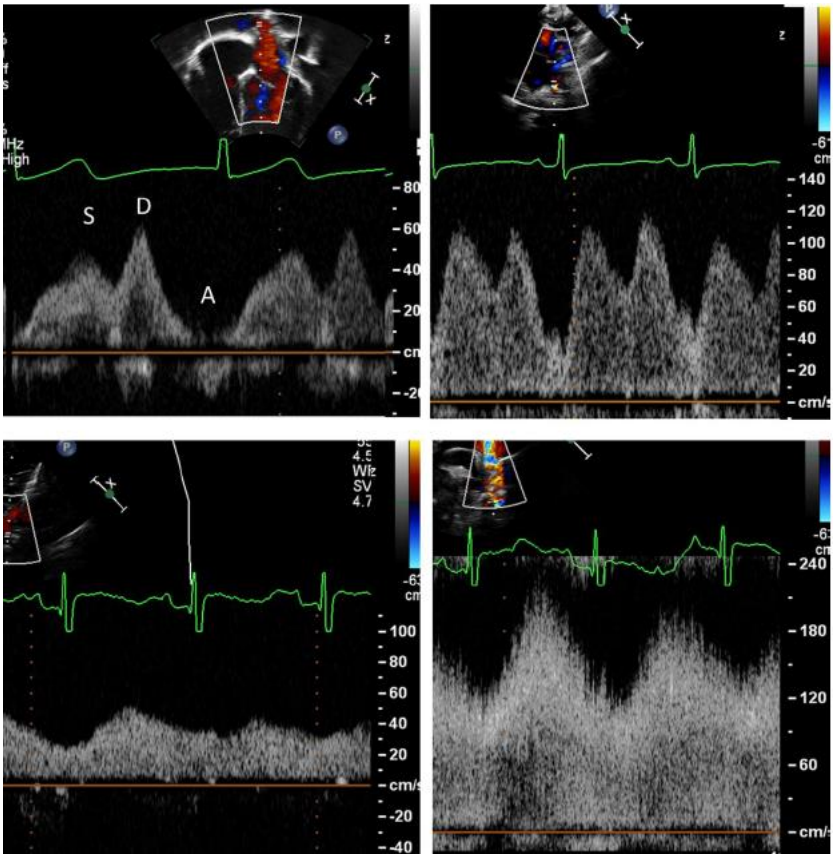

Figure 7. Transthoracic imaging pulmonary venous spectral Doppler patterns are evaluated. (A) Normal right upper-pulmonary vein apical Doppler pictures. (B) High parasternal short-axis pictures demonstrate high-flow, unobstructed pulmonary venous patterns. (C) Pulse-wave Doppler demonstrates a decrease in cardiac cycle phasicity and no baseline or a-wave reversal in this high parasternal short-axis view of the left lower-pulmonary vein. (D) Suprasternal notch pulse wave Dopplers indicate high velocity and turbulence at the vertical vein-innominate connection, indicating obstruction.[15]

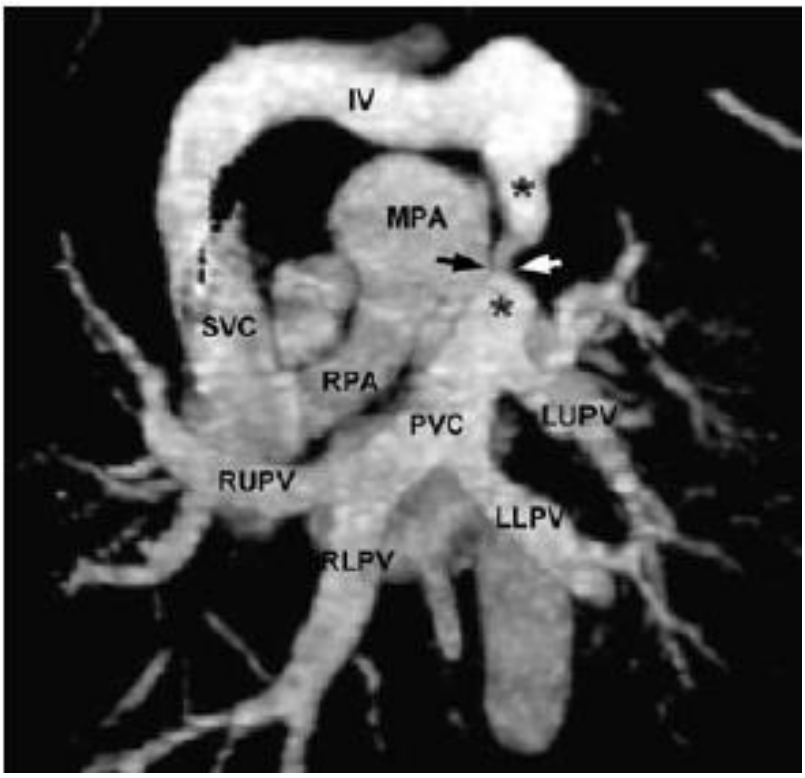

Figure 8. Supracardiac TAPVD obstruction. A CT scan's subvolume maximum intensity coronal projection shows obstruction of the vertical vein (arrowheads) connecting the pulmonary venous connector to the innominate vein (asterisks).[25]

Magnetic Resonance Imaging (MRI) And Computerized Tomography (CT)

In general, the use of MRI as an initial evaluation in newborns is not really necessary, because diagnostics with echocardiography are accurate, ready anywhere, and can also be used portable. In older TAPVD patients, MRI shows greater accuracy compared to echocardiography.[16]

Because some cases are difficult to diagnose using echocardiography and the morbidity associated with cardiac catheterization in critically ill patients, cardiac MRI and CT are important diagnostic tools for establishing the diagnosis of TAPVD (Fig. 8). When compared with the use of echocardiography and cardiac catheterization, several studies have demonstrated the accuracy of the use of MRI and CT in the diagnosis of TAPVD.[24]

Cardiac Catheterization

An angiogram obtained from contrast injection through the pulmonary artery and pulmonary vein defines the shape of the malformation, determines the location of its drainage, and can often locate the location of pulmonary venous obstruction. However, this procedure cannot be performed on critically ill neonates.[6]

As the connection goes to the left vertical vein, the common pulmonary vein and vertical vein can also be seen. As the anomalous connection drains into the coronary sinus, it appears as an opaque, oval shape on the left side of the spine in the contour of the right atrium. In the infracardiac type, the descending veins can be seen.[6]

3. Conclusion

TAPVD is a rare CHD that could involved any ages and need carefulness to establish the diagnosis because of many other cardiac abnormalities could associated with it. A systematic history taking, physical examination, and another supportive imaging modalities is needed to ensure this structural anomaly. Further understanding of imaging modalities could help cardiologist to differentiate every type of TAPVD and reveal the obstruction degrees.

4. Declaration

4.1 Ethics Approval and Consent to participate
Not applicable.

4.2. Consent for publication
Not applicable.

4.3 Availibility of data and materials
Data used in our study were presented in the main text.

4.4 Competing interests
Not applicable.

4.5 Funding Source
Not applicable.

4.6 Authors contributions
Idea/concept: FC. Design: FC. Control/supervision: VYSP. Data collection/processing: FC, VYSP. Analysis/interpretation: FC. Literature review: FC. Writing the article: FC. Critical review: VYSP. All authors have critically reviewed and approved the final draft and are possible for the content and similarity index of the manuscript.

4.7 Acknowledgements
We thank to Brawijaya Cardiovascular Research Center

References

1. Ossa Galvis MM, Bhakta RT, Tarmahomed A, Mendez MD. *Cyanotic Heart Disease.*; 2023.
2. Kao CC, Hsieh CC, Cheng PJ, Chiang CH, Huang SY. Total Anomalous Pulmonary Venous Connection: From Embryology to a Prenatal Ultrasound Diagnostic Update. *J Med Ultrasound*. 2017;25(3):130-137. doi:10.1016/j.jmu.2017.08.002
3. Raharjo S, Roebiono P, Wahidji V, Rahajoe A. Total Anomalous Pulmonary Venous Drainage. *Indonesian Journal of Cardiology*. 1970;28(6). doi:10.30701/ijc.v28i6.211
4. Lemaire A, DiFilippo S, Parienti JJ, et al. Total Anomalous Pulmonary Venous Connection: A 40 years' Experience Analysis. *Thorac Cardiovasc Surg*. 2016;65(01):009-017. doi:10.1055/s-0036-1588007
5. Talwar S, Choudhary SK, Reddy S, et al. Total anomalous pulmonary venous drainage beyond childhood. *Interact Cardiovasc Thorac Surg*. 2008;7(6):1058-1061. doi:10.1510/icvts.2008.186734
6. Kouchoukos NT, Blackstone EH, Hanley FL, Kirklin JK. Total Anomalous Pulmonary Venous Connection. In: *Kirklin/Barrat-Boyes Cardiac Surgery*. Vol 2. 4th ed. Elsevier; 2013:1182-2107.
7. Wilson J. XIII. A description of a very unusual formation of the human heart. *Philos Trans R Soc Lond*. 1798;88:346-356. doi:10.1098/rstl.1798.0014
8. Nyayadhish P, Kumar S. Anomalies of Pulmonary Veins. In: Vijayalakshmi I, Rao PS, Chugh R, Perloff JK, eds. *A Comprehensive Approach to Congenital Heart Diseases*. 1st ed. Jaypee Brothers Medical Publishers; 2013:224-242.
9. Kao CC, Hsieh CC, Cheng PJ, Chiang CH, Huang SY. Total Anomalous Pulmonary Venous Connection: From Embryology to a Prenatal Ultrasound Diagnostic Update. *J Med Ultrasound*. 2017;25(3):130-137. doi:10.1016/j.jmu.2017.08.002
10. Park MK, Salamat M. Cyanotic Congenital Heart Defects (Total Anomalous Pulmonary Venous Return). In: *PARK'S PEDIATRIC CARDIOLOGY FOR PRACTITIONERS*. 7th ed. Elsevier; 2014:186-188.
11. Vanderlaan RD, Anderson RH, Shirali G, Spicer DE, Hlavacek AM, Caldarone CA. Pulmonary Venous Abnormalities. In: *Anderson's Pediatric Cardiology*. 4th ed. Elsevier; 2010:497-522.
12. Talib N, Sayuti KA, Abdullah MS, Mohd Zain MR. Beating the odds: a rare case of supracardiac total anomalous pulmonary venous return (TAPVR) in an adult patient. *BMJ Case Rep*. Published online March 5, 2018:bcr-2017-221074. doi:10.1136/bcr-2017-221074
13. Abdullayev FZ, Bagirov IM, Kazimzade NJ, Shikhiyeva LS. Repair of total anomalous pulmonary venous return (TAPVR) with pulmonary artery (PA) Stenosis in adult. *J Cardiothorac Surg*. 2015;10(S1):A70. doi:10.1186/1749-8090-10-S1-A70
14. Tang J, Wu Z, He J, et al. Case Report: A Huge Calabash Heart: A Rare Case of Supracardiac Total Anomalous Pulmonary Venous Return. *Front Cardiovasc Med*. 2022;9. doi:10.3389/fcvm.2022.942808
15. Files MD, Morray B. Total Anomalous Pulmonary Venous Connection: Preoperative Anatomy, Physiology, Imaging, and Interventional Management of Postoperative Pulmonary Venous Obstruction. *Semin Cardiothorac Vasc Anesth*. 2017;21(2):123-131. doi:10.1177/1089253216672442
16. Brown DW, Geva T. Anomalies of the Pulmonary Veins. In: *MOSS & ADAMS' HEART DISEASE IN INFANTS, CHILDREN, AND ADOLESCENTS INCLUDING THE FETUS AND YOUNG ADULT*. Vol 1 and 2. 10th ed. Wolters kluwer; 2013.

17. SMITH B. Total Anomalous Pulmonary Venous Return. *American Journal of Diseases of Children*. 1961;101(1):41. doi:10.1001/archpedi.1961.04020020043008

18. Fu CM, Wang JK, Lu CW, et al. Total Anomalous Pulmonary Venous Connection: 15 Years' Experience of a Tertiary Care Center in Taiwan. *Pediatr Neonatol*. 2012;53(3):164-170. doi:10.1016/j.pedneo.2012.04.002

19. Lemaire A, DiFilippo S, Parienti JJ, et al. Total Anomalous Pulmonary Venous Connection: A 40 years' Experience Analysis. *Thorac Cardiovasc Surg*. 2016;65(01):009-017. doi:10.1055/s-0036-1588007

20. Erek E. Incidence and treatment of pulmonary vein stenosis after repair of total anomalous pulmonary venous connection. *The Turkish Journal of Thoracic and Cardiovascular Surgery*. 2019;27(4):471-477. doi:10.5606/tgkdc.dergisi.2019.17303

21. Aluja Jaramillo F, Hernandez C, Garzón JP, Sánchez Herrera AP, Velasco Morales ML. Infracardiac type total anomalous pulmonary venous return with obstruction and dilatation of portal vein. *Radiol Case Rep*. 2017;12(2):229-232. doi:10.1016/j.radcr.2017.01.010

22. Al-Mutairi M, Aselan A, Al-Muhaya M, Abo-Haded H. Obstructed infracardiac total anomalous pulmonary venous connection: The challenge of palliative stenting for the stenotic vertical vein. *Pediatr Investig*. 2020;4(2):141-144. doi:10.1002/ped4.12204

23. Cetta F, Ammash NM. Anomalies of the Pulmonary and Systemic Venous Connections. In: Eidem BW, ed. *Echocardiography in Pediatric and Adult Congenital Heart Disease*. 2nd ed. Wolters Kluwer Health; 2015:91-110.

24. Xiang Y, Cheng G, Jin K, Zhang X, Yang Y. Computed tomography findings and preoperative risk factors for mortality of total anomalous pulmonary venous connection. *Int J Cardiovasc Imaging*. 2018;34(12):1969-1975. doi:10.1007/s10554-018-1405-2

25. Corno AF, Festa GP. Anomalous pulmonary venous connections. In: *Congenital Heart Defects Decision Making for Cardiac Surgery CT-Scan and MRI*. Vol 3. Jonas, Richard. Steinkopff Verlag; 2009.

Heart Sci J 2024; 5(2): 14-22

Contents list available at www.heartscience.ub.ac.id

Heart Science Journal

Journal Homepage : www.heartscience.ub.ac.id

Review Article

Clinical Features and Multimodality Diagnostic Tools of Pulmonary Hypertension

Lukitasari Ayu Galuh Ardhi[1*], Anna Fuji Rahimah[2], Heny Martini[2], Ardian Rizal[2]

[1]Brawijaya Cardiovascular Research Center, Department of Cardiology and Vascular Medicine, Faculty of Medicine, Universitas Brawijaya, Malang, Indonesia.
[2]Department of Cardiology and Vascular Medicine, Faculty of Medicine, Universitas Brawijaya, Malang, Indonesia.

ARTICLE INFO

Keyword :
Clinical Risk Scoring;
Pulmonary Hypertension;
Right Heart Catheterization.

ABSTRACT

Pulmonary hypertension (PH) is defined as an increase in mean pulmonary arterial pressure (mPAP) above normal (> 20 mmHg) and an increase in pulmonary vascular resistance (pulmonary vascular resistance / PVR) above normal in resting settings. The pathophysiology of PH involves remodeling of the pulmonary vessels, from the main pulmonary arteries, lobar arteries, segmental arteries, distal arteries, pulmonary arterioles, capillaries to the postcapillary pulmonary veins. In general, the epidemiological figures for PH are not known with certainty. The United Kingdom reported a PH prevalence of 97 cases per one million people, with a female-to-male ratio of 1.8. The diagnostic strategy for PH focuses primarily on two issues. The primary objective is to improve the early detection of PH and expedite the transfer of patients at high risk for PAH, CTEPH, or other forms of severe PH to a PH center. The second objective is to identify the underlying disease, including left heart disease (Group 2 PH) and lung disease (Group 3 PH), as well as comorbidities, in order to assure proper classification, risk assessment, and therapy. The gold standard for detecting and categorizing pulmonary hypertension is right heart catheterization (RHC). Clinical scoring in the form of shortness of breath without any obvious cause accompanied by physical examination, ECG and Thorax X-ray images which depict an enlarged right heart have good specificity and sensitivity for the diagnosis of pulmonary hypertension in patients with congenital heart disease. A high right ventricular pressure, mean PAP, and BNP values during observation, as well as heart size on chest X-ray can be predictors of a poorer prognosis in this population.

1. Introduction

Definition of Pulmonary Hypertension

Pulmonary hypertension (PH) is a pathological dysfunction of the pulmonary arteries that can be induced by respiratory and circulatory issues and can occur in a wide range of clinical settings. Pulmonary hypertension (PH) is defined as an increase in mean pulmonary arterial pressure (mPAP) above normal (> 20 mmHg) and an increase in pulmonary vascular resistance (PVR) above normal in resting conditions.

Right heart catheterization (RHC) identifies pulmonary hypertension as an increase in resting mean pulmonary artery pressure (mPAP) of more than 20 mm Hg. At repose, the mean mPAP is 14.3 mm Hg, with a normal upper limit of approximately 20 mm Hg. However, an increase in mPAP >20 mmHg alone cannot be used to determine the specific clinical conditions underlying the pathophysiological process of pulmonary hypertension. This is due to the fact that an increase in mPAP can result from a variety of factors, including increased cardiac output, left-to-right cardiac shunt, increased pulmonary artery wedge pressure (PAWP) in left heart illness, hyperviscosity conditions, and pulmonary vascular disease. PVD is caused by structural changes/ arterioles/remodeling of the distal pulmonary arteries. Thus, integrating pulmonary vascular resistance (PVR) characteristics in the diagnosis of pulmonary hypertension, in addition to mPAP, can present a distinct pathophysiological picture and be more clinically significant. The PVR value is the result of calculations from the formula: (mPAP-PAWP)/CO, so that the PVR assessment can distinguish increases in mPAP due to PVD (pre-capillary) or due to increased PAWP or increased CO (post-capillary) or a combination of both. So hemodynamically, based on these three parameters, namely mPAP, PVR and PAWP, the definition of PH is divided into three, namely: isolated postcapillary PH, precapillary PH and a combination of pre and post capillary PH.[1]

Pathophysiology of Pulmonary Hypertension

The pathophysiology of PH involves remodeling of the pulmonary vessels, from the main pulmonary arteries, lobar arteries, segmental arteries, distal arteries, pulmonary arterioles, capillaries to the postcapillary pulmonary veins. The process of lesion remodeling takes place gradually and in various degrees of lesion severity[2]. In the arterial system, the remodeling process includes the following:[2]

* Corresponding author at: Brawijaya Cardiovascular Research Center, Department of Cardiology and Vascular Medicine, Faculty of Medicine, Universitas Brawijaya, Malang, Indonesia.
E-mail address: galuhardhi@yahoo.com (L.A.G. Ardhi).

https://doi.org/10.21776/ub/hsj.2024.005.02.4
Received 14 July 2023; Received in revised form 2 August 2023; Accepted 4 September 2023.
Available online 28 April 2024

Table 1. Pathophysiology of Pulmonary Hypertension in Each Artery[20].

Pulmonary Vessel	Pathophysiology
Main pulmonary artery (elastic)	Stiffening, organized thrombus in chronic thromboembolic pulmonary hypertension (CTEPH)
Lobar artery (elastic)	Stiffening, organized thrombus on CTEPH
Segmental (elastic) arteries	Stiffening, organized thrombus on CTEPH
Distal (muscular) artery (500μm-70μm in diameter)	Vasoconstriction, tunica media hypertrophy/hyperplasia, intimal and adventitial fibrosis, insitu thrombotic lesions, plexiform lesions
Pulmonary arterioles (70 μm – 20 μm in diameter)	Vasoconstriction, loss/decreased arteriolar density, obliteration of thrombotic lesions, abnormal musculature, perivascular inflammation
Capillary	Loss of capillary density
Venules and pulmonary veins (postcapillary)	Medial/muscular hyperplasia, intimal fibrosis, perivenular inflammation, chronically increased postcapillary pressure (in group II pulmonary hypertension), lung parenchymal destruction and inflammation (in group III pulmonary hypertension)

Table 2. Haemodynamic Definitions of Pulmonary Hypertension

Definition	Haeomodiynamic Characteristics
PH	mPAP >20 mmHg
	mPAP >20 mmHg
Pre-capillary PH	PAWP ≤15 mmHg
	PVR >2 WU
	mPAP >20 mmHg
IpcPH	PAWP >15 mmHg
	PVR ≤2 WU
	mPAP >20 mmHg
CpcPH	PAWP >15 mmHg
	PVR >2 WU
Exercise PH	mPAP/CO slope between rest and exercise >3mmHg/L/min

- Accumulation of abnormal cells in the endothelial and intimal layers (intima fibrosis, thrombotic lesions and plexiform lesions), pulmonary artery smooth muscle (smooth muscle hypertrophy/hyperplasia and fibroblast infiltration), and adventitial lining (adventitial fibrosis).[2]
- Reduction or loss of precapillary pulmonary arterioles density, perivascular infiltration by excessive inflammatory cells (mast cells, B and T lymphocytes, macrophages, dendritic cells, and so on).[2]

Epidemiology of Pulmonary Hypertension

The United Kingdom reported a prevalence of PH of 97 cases per 100,000 people, with a female-to-male ratio of 1. According to extensive registry data, PH owing to left heart disease, or PH group II, has the highest prevalence when compared to other types of PH. Pulmonary artery hypertension (PAH) or PH group I has the lowest estimated prevalence of 15 cases/1,000,000 adult population and the lowest estimated incidence of 2 cases/1,000,000 adult population. 4 cases/1,000,000/year of adult population4. In Europe, the prevalence of PAH ranges from 15-60 cases/1,000,000 population and with an incidence of 5-10 cases/1,000,000/year. In Indonesia, neither PH nor PAH has well-documented prevalence and incidence data. According to a registry from an Indonesian cardiac referral center hospital, the highest frequency and incidence of PAH in adults is attributable to congenital heart disease. Recent data show an increased incidence of PAH in the adult age group, with a mean age at diagnosis between 50-65 years.[3] Group II and group III pulmonary hypertension have an incidence and prevalence related to the underlying disease, namely chronic lung disease and left heart diseaseThere is no conclusive evidence on the incidence and prevalence of PH in this population. 2 cases/1,000,000 population and the incidence reaches 0. National data in Indonesia has not been well documented, so the prevalence and incidence rates are not known.[1,2]

Classification of Pulmonary Hypertension

The 6th World Symposia on Pulmonary Hypertension classified pulmonary hypertension into five categories. This categorization seeks to categorize clinical disorders based on etiology, clinical presentation, hemodynamic features, and therapy response.[1] While hemodynamics is an essential aspect of PH classification, the final diagnosis and categorization should reflect the clinical context as a whole and take all test results into account. PVR and pulmonary artery wedge pressure (PAWP) must be incorporated into the diagnosis of precapillary PH in order to distinguish between elevated PAP due to PVD and elevated PAP due to LHD, increased pulmonary blood flow, or increased intrathoracic pressure.[4]

Patients with PAH are characterized hemodynamically by precapillary PH in the absence of other precapillary PH causes, such as CTEPH and PH related to pulmonary disease. Precapillary and postcapillary components in all PH categories may contribute to an increase in PAP. Certain disorders, particularly in the elderly, may put people at risk for PH. The hypothesized major cause of high pulmonary pressure should be used to determine the first classification.[5]

Hemodynamically, postcapillary pH is defined as PAWP >15 mmHg and mPAP >20 mmHg. PVR was utilized to distinguish between individuals with high precapillary pH (PVR >2 WU - combination of postcapillary and precapillary PH [CpcPH]) and those without (PVR 2 WU - isolated postcapillary PH [IpcPH]).[1]

Existence of patients with high mPAP (>20 mmHg) but low PVR (2 WU) and PAWP (15 mmHg). Frequently, these individuals have a high pulmonary blood flow and pH, but do not meet the precapillary or postcapillary PH requirements. This is referred to as "unclassified PH" in the medical community. Unclassified PH patients may have congenital heart defects (CHD), liver illness, pulmonary disease, lung disease, or hyperthyroidism, all of which explain increased mPAP. Clinical monitoring of these individuals is frequently advised. If pulmonary blood flow rises, the cause should be determined.[1]

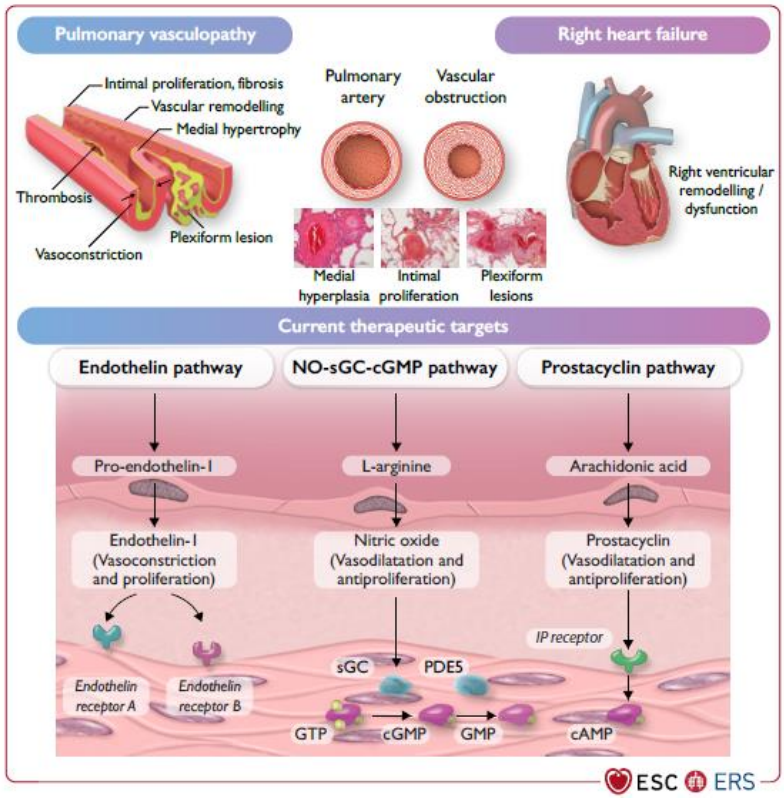

Figure 1. Pathophysiology and Therapeutic Agents in Pulmonary Artery Hypertension

Since PH groups represent different clinical conditions based on clinical classification, additional clinically relevant hemodynamic thresholds (e.g., in the case of PVR) for individual PH groups may exist in addition to the general threshold discussed in the corresponding section. The training PH has been reinstated with a mPAP/cardiac output (CO) gradient between rest and exercise, defined as >3 mmHg/L/min. The inclination of mPAP / CO is significantly age-dependent, with the typical upper limit in the supine position being between 1.6 and 3.3 mmHg/L/min. The mPAP/CO.3 mmHg/L/min tendency in 60-year-olds may not be physiological, and it may be unusual in healthy 60-year-old people. A pathological increase in pulmonary pressure during exercise is associated with poor prognosis in individuals 18 with sports dyspnea and other cardiovascular disorders. An abnormal hemodynamic response to exercise is characterized by an increase in the propensity for mPAP/CO, but it is unable to differentiate between precapillary and postcapillary causes.PAWP/CO gradients of 2 mmHg/L/min can discriminate between precapillary PH2 and postcapillary training.

The primary objective of PH clinical categorization is to describe clinical disorders associated with PH based on associated neurological bases, clinical presentation, haemodynamic characteristics, and therapeutic therapy.[6]

Group 1: Pulmonary Arterial Hypertension (PAH)

1. Idiopathic PAH
2. Inherited PAHs
3. PAH due to drugs and toxins
4. PAHs associated with:
   A. Connective tissue disease
   B. Human Immunodeficiency Virus (HIV) infection
   C. Portal hypertension
   D. Congenital heart disease
   E. Schistosomiasis
5. PAHs that respond to the use of calcium channel blockers
6. PAH stands for pulmonary venous occlusive disease and/or pulmonary capillary hemangiomatosis.
7. PH is persistent in neonates

The preponderance of PAH symptoms are non-specific and result from right ventricular failure. Pulmonary Artery Hypertension (PAH) is a kind of group 1 hypertension distinguished by three diagnostic criteria on RHC examination: mPAP > 20 mmHg, PVR 3, and PAWP 15 mmHg Wood units. Patients with PAH should be evaluated on a regular and comprehensive basis. This is because no one characteristic can give enough information to establish a diagnosis or prognosis. The assessment of the prognosis of PAH patients is critical in disease management.[7]

The diagnostic gold standard for PAH is a right cardiac catheterization (RHC). PAH diagnostic criteria must include mPAP greater than 20 mmHg, PAWP greater than 15 mmHg, and PVR greater than 3 WU.[1]

Group 2: Pulmonary hypertension caused by left heart disease (PH-LDH)

1. PH due to heart failure with preserved LVEF
2. PH due to heart failure with reduced LVEF
3. Heart valve disease
4. Congenital/acquired cardiovascular conditions leading to post-capillary PH

Pulmonary hypertension caused by anomalies of the left heart, such as valvular heart disease and congenital heart disease, is known as PH-LHD. The passive transfer of pressure backward from the left ventricular filling pressure (Vki) causes pulmonary hypertension induced by left heart malfunction. VKI diastolic function primarily influences VKI filling pressure, with an increase in end-diastolic pressure in individuals with left heart failure. Other causes of left heart illness include pulmonary venous congestion, pulmonary vascular vasoconstriction, reduced availability of Nitric Oxide, increased endothelin response, and pulmonary vascular remodeling. This condition may lead mPAP to grow more than PAWP, resulting in an increase in Vki afterload and Vka inability to perform its tasks. This activates PH-LHD.[8]

The difference in hemodynamic features between precapillary and postcapillary PH is used to define PH-LHD. The transpulmonary pressure gradient (TPG), which may be computed as the difference between mPAP and PAWP, is used to distinguish between passive (TPG less than 12 mmHg) and reactive (TPG greater than 12 mmHg) PH. All of the mPAP components, including resistance, flow, and left heart filling pressure, have an effect on the transpulmonary pressure gradient. The Diastolic Pressure Gradient (DPG), which is the Diastolic PAP minus the mean PAWP, is the best diagnostic for identifying pulmonary vascular disease. Normal persons have a DPG of 1-4 mm Hg, whereas patients with heart disease (excluding those with shunting) have a DPG of 5 mm Hg in most circumstances.[9]

A three-step approach is recommended for identifying the differential diagnoses of PH-LHD (especially HFpEF) and PAH is identification of clinical manifestations suggestive of PH-LHD, determining pre-test probabilities for PH-LHD, and hemodynamic characterization.[8]

Group 3: Pulmonary hypertension due to pulmonary disease and/or hypoxia

1. Obstructive lung disease
2. Restrictive lung disease
3. Other lung disease with a mixture of obstructive/restrictive
4. Hypoxia without pulmonary disease
5. Pulmonary developmental disease

Pulmonary hypertension caused by hypoxia and/or lung disease, also known as PH group III, is found in a variety of lung diseases and chronic hypoxic conditions, including (1) chronic obstructive pulmonary disease, (2) pulmonary interstitial disease, (3) other restrictive and obstructive lung diseases, (4) sleep-disordered breathing, (5) alveolar hypoventilation disease, (6) chronic high altitude exposure, and (7) developmental lung disease. Shortness of breath, weakness, fatigue, angina, and fainting are frequent symptoms of worsening right ventricular failure, which are aggravated by physical activity. Other symptoms include hemoptosis due to bronchial artery hypertrophy, hoarseness due to recurrent laryngeal nerve suppression, wheezing due to airway compression, and angina due to cardiac ischemia induced by left main coronary artery compression. Several signs were detected during physical examination, including left parasternal lift, pulmonary component in sound, heart 2 (P2) hardness, RV third heart sound, pansystolic murmur in tricuspid regurgitation, and diastolic murmur in pulmonary regurgitation.

Elevated jugular venous pressure, hepatomegaly, peripheral edema, ascites, cold acral, and clubbing fingers are other physical examination findings, all of which are symptoms of the underlying disease.[10] A chest X-ray revealed central pulmonary artery dilation, right atrial and ventricular hypertrophy, pulmonary venous congestion, and signs of the underlying illness. Depending on the underlying condition, blood gas analysis (AGD) and pulmonary function tests (TFP) revealed reduced lung diffusion capacity for carbon monoxide (DLCO) (45% prediction), decreased residual volume, PaO2 and PaCO2 levels. 4 m/s, and right atrial pressure. Computed tomography (high-resolution, contrast enhanced) of the chest reveals enlargement of the pulmonary artery or right ventricle, and can identify pulmonary disease that causes PH. Blood tests: BNP or NT-proBNP biomarkers and immunological parameters for underlying lung disease.

Group 4: Pulmonary hypertension caused by pulmonary artery obstruction

1. Chronic thromboembolic pulmonary hypertension
2. Other pulmonary artery obstruction

CTEPH is a chronic thromboembolic disease and pulmonary vascular remodeling caused by thromboembolism, impaired fibrinolytic factors, endothelial dysfunction, and defects in angiogenesis. In addition, the 2018 World Symposium Pulmonary Hypertension (WSPH) introduced the term Chronic Thromboembolic Disease (CTED), which has symptoms and perfusion defects similar to CTEPH but without PH.[11]

There is apparently insufficient evidence to support routine CTEPH screening in individuals with a history of acute pulmonary embolism. This is because many CTEPH patients have no prior history of pulmonary embolism. CTEPH, mPAP > 20 mmHg, pulmonary artery wedge pressure (PAWP) 15 mmHg, and perfusion abnormalities observed on V/Q scan or CTEPH specific findings on multidetector CT angiography are all risk factors for CTEPH.[11] Normal V/Q Scan results are proven to exclude CTEPH with a specificity of 94-100% and a sensitivity of 90-100%. The main characteristic of CTEPH from a V/Q scan is the finding of a V/Q mismatch in which there is normal ventilation accompanied by perfusion defects in the proximal, segmental, and subsegmental pulmonary vessels. Recent studies now show that CT pulmonary angiography (CTPA) has a fairly high sensitivity and specificity where CTPA can detect thromboembolic events in the lobar segment with a sensitivity of 97-100%, a specificity of 95-100% and segmental with a sensitivity of 86-100%, a specificity of 93-99 %. However, recent data show that CTPA can replace pulmonary angiography in detecting CTEPH. The sensitivity of pulmonary angiography varies from 66% in the lobar segment to 76% in the subsegmental area. Therefore, in patients with CTEPH, Doppler vascular examination of the extremities can be performed to look for thrombus sources that can increase the risk of thromboembolism.[12]

Group 5 : Pulmonary hypertension with unclear mechanism and/or multifactorial

1. Hematological Disorders
2. Systemic and metabolic disorders
3. Other disorders
4. Complex congenital heart disease

Eisenmenger syndrome, PAH associated with a left-to-right shunt, PAH with minimal anomalies, and PAH subsequent to defect correction are the four types of pulmonary hypertension caused by congenital cardiac disease. Significant intra and extra-cardiac difficulties that begin with a systemic-to-pulmonary shunt and evolve over time into a pulmonary-to-systemic shunt or bidirectional flow are known as a pulmonary-to-systemic shunt or bidirectional flow. Pneumovascular resistance frequently decreases shortly after birth as right ventricular compliance increases, resulting in increased pulmonary blood flow and systemic-to-pulmonary shunt. The pulmonary vascular resistance rises with time, leading the shunt to revert to a pulmonary to systemic shunt in the ventricles or great arteries. SE is diagnosed through the use of a medical history, physical examination, lung function tests, arterial blood gas analysis, imaging (especially echocardiography), and laboratory testing (including total blood cell count, serum iron, hematocrit, infectious infection, and NT prophylaxis). Right heart catheterization can, in general, determine pulmonary pressure and calculate the pulmonary/systemic flow ratio, pulmonary vascular resistance, and systemic and pulmonary resistance ratio, which are required for diagnostic decisions and decisions such as initiating and continuing vasodilator therapy. PAH anomalies linked with systemic to pulmonary shunt, defined as a rise in mean pulmonary artery pressure (PAP) >20 mmHg and an increase in pulmonary vascular resistance (PVR) >3 WU, in accordance with other pre-capillary PH criteria, are one of the causes of PAH with CHD. Eisenmenger syndrome includes all intra- and extracardiac abnormalities that begin as systemic-to-pulmonary shunts and progress to highly elevated PVR and reverse (pulmonary-to-systemic) or bidirectional shunting. PVR is minimally to moderately increased in PAH patients with prevalent systemic-to-pulmonary shunts, and systemic-to-pulmonary shunting is still prevalent, despite the absence of cyanosis at rest.[1] Corrected PAH abnormalities in CHD associated with systemic to pulmonary shunts are mentioned if found without shunt reversal, with mild to moderate degrees of cyanosis and erythrocytosis. PVR is slightly to moderately raised, there is still a systemic to pulmonary shunt, and no cyanosis is present at rest. Medical history, physical examination, lung function, arterial blood gas analysis, various laboratory tests (including total blood cell count, serum iron level, hematocrit, infectious illness screening, and NT-pro-BNP measurement), and imaging (particularly echocardiography) are all part of the diagnostic process.

Determinants of prognosis (estimated 1-year mortality)	Low risk (<5%)	Intermediate risk (5–20%)	High risk (>20%)
Clinical observations and modifiable variables			
Signs of right HF	Absent	Absent	Present
Progression of symptoms and clinical manifestations	No	Slow	Rapid
Syncope	No	Occasional syncope[a]	Repeated syncope[b]
WHO-FC	I, II	III	IV
6MWD[c]	>440 m	165–440 m	<165 m
CPET	Peak VO_2 >15 mL/min/kg (>65% pred.) VE/VCO_2 slope <36	Peak VO_2 11–15 mL/min/kg (35–65% pred.) VE/VCO_2 slope 36–44	Peak VO_2 <11 mL/min/kg (<35% pred.) VE/VCO_2 slope >44
Biomarkers: BNP or NT-proBNP[d]	BNP <50 ng/L NT-proBNP <300 ng/L	BNP 50–800 ng/L NT-proBNP 300–1100 ng/L	BNP >800 ng/L NT-proBNP >1100 ng/L
Echocardiography	RA area <18 cm^2 TAPSE/sPAP >0.32 mm/mmHg No pericardial effusion	RA area 18–26 cm^2 TAPSE/sPAP 0.19–0.32 mm/mmHg Minimal pericardial effusion	RA area >26 cm^2 TAPSE/sPAP <0.19 mm/mmHg Moderate or large pericardial effusion
cMRI[e]	RVEF >54% SVI >40 mL/m^2 RVESVI <42 mL/m^2	RVEF 37–54% SVI 26–40 mL/m^2 RVESVI 42–54 mL/m^2	RVEF <37% SVI <26 mL/m^2 RVESVI >54 mL/m^2
Haemodynamics	RAP <8 mmHg CI ≥2.5 $L/min/m^2$ SVI >38 mL/m^2 SvO_2 >65%	RAP 8–14 mmHg CI 2.0–2.4 $L/min/m^2$ SVI 31–38 mL/m^2 SvO_2 60–65%	RAP >14 mmHg CI <2.0 $L/min/m^2$ SVI <31 mL/m^2 SvO_2 <60%

Figure 2. Risk Assessment in Pulmonary Artery Hypertension

2. Diagnosis of Pulmonary Hypertension

Clinical Manifestation

The diagnostic strategy for PH focuses on two primary issues. The primary objective is to improve the early detection of PH and ensure that patients with a high risk of PAH, CTEPH, or other forms of severe PH are sent to a PH center without delay. The second objective is to identify the underlying disease, namely left heart disease (Group 2 PH) and lung disease (Group 3 PH), as well as comorbidities, in order to assure proper classification, risk assessment, and treatment. Symptoms of PH include activity-related shortness of breath, weakness, fatigue, chest discomfort, dizziness or syncope, and occasional coughing. Progressive indications of right heart failure (edema, ascites, abdominal distension) occur as the illness progresses. Other typical PH symptoms include hemoptysis, hoarseness/Ortner's syndrome (unilateral paralysis of the vocal cords), and arrhythmias.[7]

Symptoms of the initial phase in patients with pulmonary hypertension are as follows:

- Overwhelmed with activity
- Weak, easily tired
- Shortness when bending forward (bendopnea)
- Palpitations
- Hemoptysis
- Abdominal distention or nausea induced by activity/exercise
- Weight increase as a result of fluid retention
- Syncope (during sports/activities and after)

While the advanced phase symptoms of pulmonary hypertension include the following:

- Chest pain during activity
- Hoarseness/hoarseness (dysphonia)
- Shortness of breath, coughing, Wheezing, lower respiratory tract infection and atelectasis[4].

Physical Examination

Physical examination may reveal an enhanced second heart sound (component P2), elevated right ventricle, jugular venous distention, hepatojugular reflux, ascites, hepatomegaly and/or splenomegaly, edema, tricuspid/pulmonary valve regurgitation murmurs, and S3 gallop. The history and physical examination can be used to identify diseases related with PH1.[7]

Electrocardiography (ECG)

ECG abnormalities are common at high ph levels. However, the absence of abnormalities on the ECG does not preclude a PH diagnosis. ECG abnormalities that can be found include P lung, right axis abnormality, right ventricular hypertrophy, right ventricular tone, right bundle branch block, and QTc lengthening. Prolongation of QTc and expansion of the QRS complex indicate the severity of the disease. Atrial flutter and atrial fibrillation are examples of advanced supraventricular arrhythmias. Therefore, pulmonary hypertension may be suspected if the patient's ECG results meet any of the following criteria:[13]

- P pulmonal (P > 0.24 mV di lead II)
- Right Axis Deviation / sagittal (QRS axis > 90° or indeterminant)
- RV Hypertrophy (R/S > 1, with R > 0.5 mV di V1; R di V1 + S di lead V5 > 1 mV)
- *Right bundle branch block*—complete or incomplete (qR or rSR patterns in V1)
- RV Strain (ST depression/T-wave inversion in the right pre-cordial V1–4 and inferior II, III, aVF leads) → in *advanced* PH
- Prolonged QTc interval (unspesific)

Chest X-Ray

X-ray chest abnormalities seen in PAH patients include dilation (trim) of the central pulmonary artery and a reduction in peripheral vascularity. In certain situations, advanced PH includes right atrial and ventricular enlargement. Not only do chest X-rays reveal an increase or decrease in the arteriovenous ratio, but they also aid in the differential diagnosis of pulmonary hypertension when symptoms of lung illness (PH group 3) or pulmonary venous congestion due to left heart disease (PH group 2) are present. A standard ECG and chest X-ray cannot exclude the presence of PH.[14]

Laboratory and Immunology

Blood tests serve minimal significance in establishing a diagnosis of PH, but they do assist distinguish between forms of PH and assess whether additional organ problems exist. Impaired thyroid function often coexists with PAH, and should be considered if sudden clinical changes occur. Impaired liver function indicates congestion or drug side effects. Brain natriuretic peptide (BNP) and N-terminal pro-

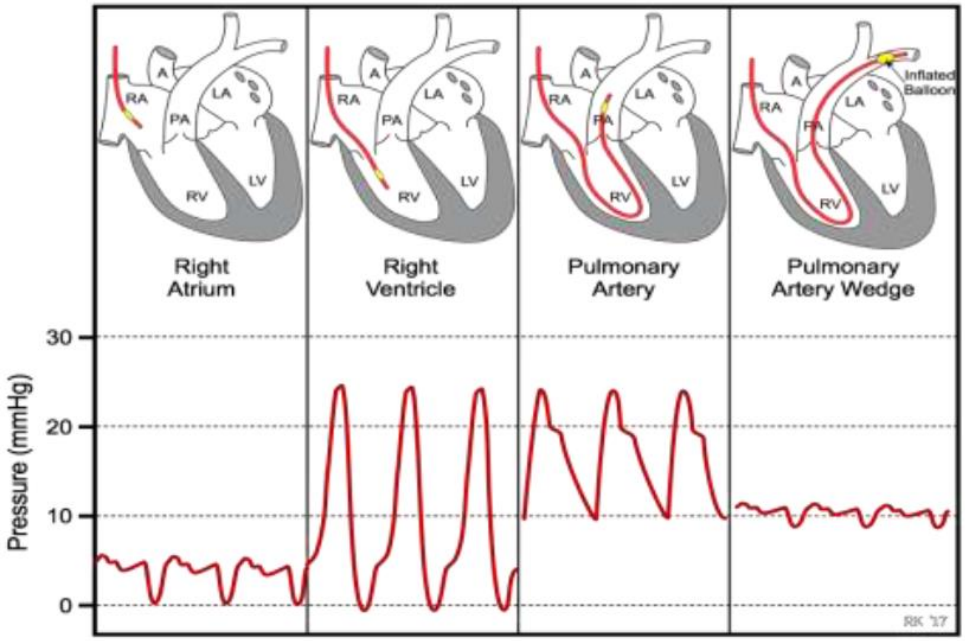

Figure 3. Intracardiac Pressure in Right Heart Catheterization

Table 3. Signs of Pulmonary Hypertension on Radiographic Examination

Signs of Pulmonary Hypertension and its disorders	Sign of LHD/pulmonary congestion	Signs of Lung Disease
Right heart enlargement	Central air space opacification	Flattening of diaphragm (COPD/emphysema)
PA enlargement (including aneurysmal dilatation)	Interlobular septal thickening 'Kerley B' lines	Hyperlucency (COPD/ Emphysema)
Pruning of the peripheral vessels	Pleural effusions	Lung volume loss (fibrotic lung disease)
Water-bottle' shape of cardiac silhouette	Left atrial enlargement (including splayed carina) Left ventricular dilation	Reticular opacification (fibrotic lung disease)

BNP (NT-proBNP) levels that are elevated are indicative of right ventricular overload and are associated with a poor prognosis.[15]

Screening for hepatitis, HIV, and connective tissue diseases should also be checked regularly. Elevated levels of antinuclear antibodies (ANA) are often found, even with low titers (1:80). Patients with connective tissue disease who have thrombophilia or chronic thromboembolic PH (CTEPH) should be tested for coagulopathy and thrombophilia parameters such as anticardiolipin antibodies, lupus anticoagulant, and anti-2-glycoprotein antibodies.[7]

Lung Function Test and Blood Gas Analysis

During evaluations of pulmonary function, total lung capacity and carbon monoxide diffusing capacity (DLCO) should be measured. The majority of PAH patients have a minor restrictive component. Significantly reduced DLCO (<60% prediction) or severe hypoxaemia on exertion suggests venous occlusive disease/hemangiomatosis of the pulmonary capillaries.[12]

Cardiopulmonary Exercise Test

This cardiopulmonary exercise test is a hemodynamic measuring test that is non-invasive. This training test was able to detect the severity of exercise limits, determine the degree of relative hypoperfusion of the lungs to the systemic circulation, and assess responsiveness to therapy in 11 individuals with PH. This cardiopulmonary exercise test can also help determine the cause of exercise limitation in patients with shortness of breath with no known cause. This examination should not be routinely performed in patients who are at risk for PAH but are asymptomatic, but can be used to assess exercise capacity in patients who have been diagnosed with PAH and determine the prognosis.[12]

Transthoracic Echocardiography

Despite being the most significant non-invasive assessment, right cardiac catheterization is used to make the definitive diagnosis of PH26. Transthoracic echocardiography is used to determine PH probability by combining multiple parameters, such as tricuspid regurgitation rate (TR Vmax) and, in addition to right ventricular size, interventricular septal function, inferior respiratory cycle variation (IVC), right atrial systolic region, systolic flow rate to early diastolic pulmonary reflux rate (PVAcc) and pulmonary artery diameter.

Lung ventilation/perfusion scan (V/Q lung scan)

CTEPH is diagnosed through the use of a V/Q lung scan. This test's benign results rule out a diagnosis of CTEPH. The V/Q lung scan is used to screen PH patients for CTEPH. V/Q scans with low or normal probability override CTEPH (90-100% sensitivity, 94-100% specificity.[16]

Computed Tomography

CT imaging raises the probability of PH if there is right ventricular, right atrial, and pulmonary artery dilatation (29 mm in diameter) or a pulmonary artery/ascending aorta diameter ratio of 1.

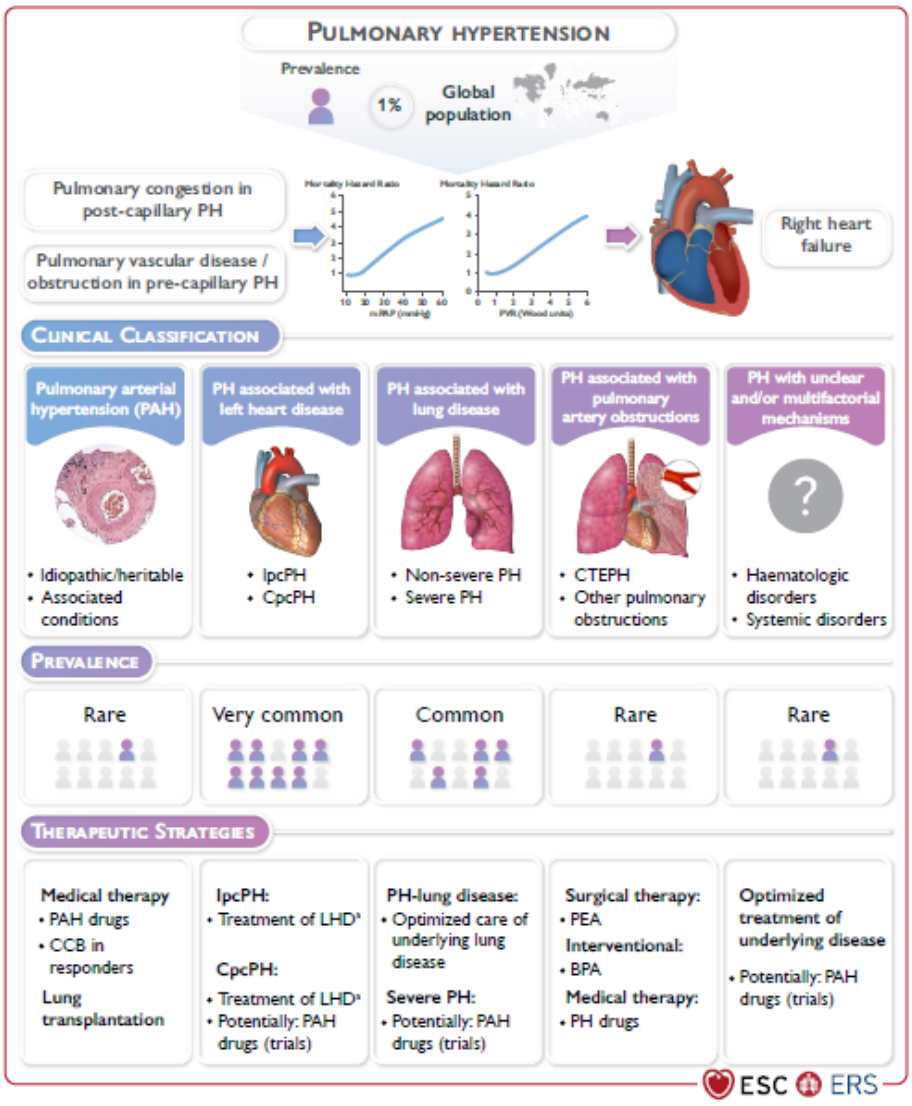

Figure 4. Central Illustration of Pulmonary Hypertension Classification

Table 4. Normal Value of Pressure and Saturation of Each Heart Chamber in Right and Left Heart Catheterization

Location	Normal Pressure (mmHg)	Average	SaO2
Right atrium	1-8	3	75%
Right Ventricle			75%
Peak systolic	15-30	25	
End diastolic	1-7	4	
Pulmonary artery			75%
Peak systolic	15-30	25	
End diastolic	4-12	9	
Mean	9-19	15	
Pulmonary capillary wedge pressure (PCWP)	4-12	9	100%
Left Atrium	2-12	8	100%
Left Ventricle			100%
Peak systolic	90-140	130	
End diastolic	5-12	8	
Aorta			100%
Peak systolic	90-140	130	
End diastolic	60-90	70	
Mean	70-105	85	
Vascular Resistance	Normal Range (Woods unit)		
Systemic Vascular Resistance (SVR)	9-20		
Pulmonary Vascular Resistance	0.5-1.5		

It is possible to use a high-resolution CT scan of the chest without contrast. To identify PH caused by lung disease (PH group 3) from PAH (PH group 1), detect pulmonary parenchymal disease.[7]

Interstitial edema, extensive central ground-glass opacification, and interlobular septal thickening are visible on PVOD CT scans. More than a third of PAH patients have the appearance of pulverized glass. pulmonary capillary hemangiomatosis is characterized by bilateral diffuse hypertrophy of interlobular septa and a small nodular opacity with no defined border. CTEPH can be diagnosed on pulmonary CT angiography with gross obstruction of the pulmonary artery or irregular intima.[3]

Right Heart Catheterization/RHC

Right heart catheterization (RHC) is the gold standard for diagnosing and classifying pulmonary hypertension. Some patients undergo right heart catheterization (RHC) in order to diagnose PAH and CTEPH, evaluate the severity of hemodynamic abnormalities, and assess vasoreactivity. Left heart catheterization and/or coronary angiography may be performed concurrently if there is angina, risk factors for coronary heart disease, or heart failure with a normal EF or systolic and/or diastolic dysfunction on TTE.[17]

Pressure measurements on PA, PA wedge, RV, and RA should be taken in RHC. Stepwise oxygen saturation assessment is conducted in individuals with pulmonary artery saturation more than 75% and if a left-to-right shunt is suspected. The direct Fick technique or thermodilution should be used to assess cardiac output (cardiac output or CO). Two additional parameters obtained from RHC are the transpulmonary pressure gradient (TPG) and the pulmonary vascular resistance (PVR). During RHC, pulmonary vasoreactivity tests are administered to identify patients with IPAH, HPAH, or drug-induced PAH who could benefit from high-dose calcium channel blocking medication.

Cardiac magnetic resonance (CMR) can help in the examination of RV size, function, morphology, stroke volume, CO, RV mass, and pulmonary artery distention, in addition to the previously described tests. CMR has a high predictive value for detecting PH in individuals with suspected PH2 if late gadolinium enhancement, reduced pulmonary artery distensibility, and retrograde flow are present. Multiple blood tests were conducted to determine the numerous causes and effects of PH. Hematology, routine blood chemistry, and thyroid function testing should be conducted on all patients, as well as specific serological tests to detect connective tissue disease, hepatitis, and HIV. Individuals with suspected HPAH underwent genetic testing, including Bone morphogenetic protein receptor type II (BMPR2) mutation screening and genetic counseling. If no BMPR2 mutations are detected in individuals with HPAH, IPAH over 40 years old, or PAH with a family history of the illness, ACVRL1 and ENG gene screening should be conducted. Meanwhile, individuals with familial pulmonary venous obstruction were tested for EIF2AK4 mutations.[18]

Algorithm for Diagnosing Pulmonary Hypertension

Suspicion

- Usually found/suspected at first-level health facilities, with atypical symptoms.
- All patients with dyspnea for no apparent reason should be considered for pulmonary hypertension screening.
- Initial examination includes: Anamnesis, Physical Examination, ECG, NTproBNP examination, and O2 Saturation

Detection

- Supporting Examinations: ECG, Echocardiography, Blood Gas Analysis, CT-Scan, Exercise Test, Pulmonary Function Test.

Confirmation

- *Right Heart Catheterization/*RHC

Clinical scoring in the form of shortness of breath without obvious cause, accompanied by physical examination, ECG, and Thorax X-ray images showing an enlarged right heart, possesses high sensitivity and specificity for identifying congenital heart disease patients with pulmonary hypertension.

Prognosis of Pulmonary Hypertension

In the recent decade, the influence of a number of novel therapeutic drugs and intensive treatment regimens has resulted in an improvement in the prognosis of children with PAH. Selection of effective therapy in children with PAH is difficult due to the complicated etiology and relative scarcity of evidence. IPAH illness progression has evolved during the last two decades, beginning with the discovery of prostacyclin. Yung et al. (2004) reported that a 10-year survival rate in the modern era was 78%. The REVEAL study (2012) reported 5-year survival for IPAH 74% and PAH-PJB 71%. There is a new article in March 2021 about a retrospective cohort multicentre study in Japan in children with IPAH, showing that high right ventricular pressure, mean PAP, and BNP values during observation, as well as heart size on chest X-ray can be predictors of a poorer prognosis in this population.[19]

Patients with left heart disease who have pulmonary hypertension have a poor prognosis. Even with medication, the prognosis for the development of PH in pulmonary interstitial disease is bleak. Thus evaluation for lung transplantation is suggested for this group of patients. In general, PH caused by chronic lung illness has a bad prognosis. When compared to Idiopathic Pulmonary Artery Hypertension, IPF patients with PH have a poorer prognosis. Patients with restrictive lung disease or severe obstructive who also have severe PH (mPAP 55mmHg) have a high mortality rate and a bad prognosis.

6. Declaration

6.1 Ethics Approval and Consent to participate
Not applicable.

6.2. Consent for publication
Not applicable.

6.3 Availibility of data and materials
Data used in our study were presented in the main text.

6.4 Competing interests
Not applicable.

6.5 Funding Source
Not applicable.

6.6 Authors contributions
Idea/concept: LUK. Design: LUK. Control/supervision: AF, HM, AR. Data collection/processing: LUK. Analysis/interpretation: LUK. Literature review: LUK. Writing the article: LUK. Critical review: AF, HM, AR. All authors have critically reviewed and approved the final draft and are possible for the content and similarity index of the manuscript.

6.7 Acknowledgements
We thank to Brawijaya Cardiovascular Research Center

References

1. Humbert M, Kovacs G, Hoeper MM, et al. 2022 ESC/ERS Guidelines for the diagnosis and treatment of pulmonary hypertension [published correction appears in Eur Heart J. 2023 Apr 17;44(15):1312]. *Eur Heart J.* 2022;43(38):3618-3731. doi:10.1093/eurheartj/ehac237.

2. Lan NSH, Massam BD, Kulkarni SS, Lang CC. Pulmonary Arterial Hypertension: Pathophysiology and Treatment. *Diseases*. 2018;6(2):38. Published 2018 May 16. doi:10.3390/diseases6020038

3. Alakhfash AA, Alqwaiee A, Alakhfash GA, Alhajjaj A, Almesned AA. Pulmonary hypertension associated with congenital heart disease; clinical decision scenario. *Respir Med Case Rep*. 2020;31:101286. Published 2020 Nov 11. doi:10.1016/j.rmcr.2020.101286

4. Maron BA. Revised Definition of Pulmonary Hypertension and Approach to Management: A Clinical Primer. *J Am Heart Assoc*. 2023;12(8):e029024. doi:10.1161/JAHA.122.029024.

5. Reinero C, Visser LC, Kellihan HB, et al. ACVIM consensus statement guidelines for the diagnosis, classification, treatment, and monitoring of pulmonary hypertension in dogs. *J Vet Intern Med*. 2020;34(2):549-573. doi:10.1111/jvim.15725.

6. Simonneau G, Montani D, Celermajer DS, et al. Haemodynamic definitions and updated clinical classification of pulmonary hypertension. *Eur Respir J*. 2019;53(1):1801913. Published 2019 Jan 24. doi:10.1183/13993003.01913-2018.

7. Perhimpunan Dokter Spesialis Kardiovaskular Indonesia. *Pedoman Diagnosis Dan Tatalaksana Hipertensi Pulmonal*.; 2021.

8. Fayyaz AU, Edwards WD, Maleszewski JJ, et al. Global Pulmonary Vascular Remodeling in Pulmonary Hypertension Associated With Heart Failure and Preserved or Reduced Ejection Fraction. *Circulation*. 2018;137(17):1796-1810. doi:10.1161/CIRCULATIONAHA.117.031608

9. Vachiéry JL, Tedford RJ, Rosenkranz S, et al. Pulmonary hypertension due to left heart disease. *Eur Respir J*. 2019;53(1):1801897. Published 2019 Jan 24. doi:10.1183/13993003.01897-2018.

10. Fein DG, Zaidi AN, Sulica R. Pulmonary Hypertension Due to Common Respiratory Conditions: Classification, Evaluation and Management Strategies. *J Clin Med*. 2016;5(9):75. Published 2016 Aug 26. doi:10.3390/jcm5090075

11. Martin KA, Cuttica MJ. Chronic thromboembolic pulmonary hypertension: anticoagulation and beyond. *Hematology Am Soc Hematol Educ Program*. 2021;2021(1):478-484. doi:10.1182/hematology.2021000282

12. Czerner CP, Schoenfeld C, Cebotari S, et al. Perioperative CTEPH patient monitoring with 2D phase-contrast MRI reflects clinical, cardiac and pulmonary perfusion changes after pulmonary endarterectomy. *PLoS One*. 2020;15(9):e0238171. Published 2020 Sep 14. doi:10.1371/journal.pone.0238171

13. Hendriks PM, Kauling RM, Geenen LW, et al. Role of the electrocardiogram in the risk stratification of pulmonary hypertension. *Heart*. 2023;109(3):208-215. Published 2023 Jan 11. doi:10.1136/heartjnl-2022-321475

14. Nareswari T, Prihharsanti CHN, Sukmaningytyas H, Ningrum FH, Satoto B, Santoso AG. A review of chest X-ray in pulmonary hypertension: correlation of right descending pulmonary artery diameter with mean pulmonary artery pressure. *Bali Med J*. 2021;10(1):467-469.doi:10.15562/bmj.v10i1.2243

15. Lewis RA, Durrington C, Condliffe R, Kiely DG. BNP/NT-proBNP in pulmonary arterial hypertension: time for point-of-care testing?. *Eur Respir Rev*. 2020;29(156):200009. Published 2020 May 15. doi:10.1183/16000617.0009-2020.

16. Alduraibi A, Fathala A. Normal ventilation/perfusion lung scan in patients with extensive chronic thromboembolism pulmonary hypertension: A case report. *Radiol Case Rep*. 2019;14(4):510-513. Published 2019 Feb 16. doi:10.1016/j.radcr.2019.01.022.

17. Lambert L, Michalek P, Burgetova A. The diagnostic performance of CT pulmonary angiography in the detection of chronic thromboembolic pulmonary hypertension-systematic review and meta-analysis. *Eur Radiol*. 2022;32(11):7927-7935. doi:10.1007/s00330-022-08804-5

18. Lambert L, Michalek P, Burgetova A. The diagnostic performance of CT pulmonary angiography in the detection of chronic thromboembolic pulmonary hypertension-systematic review and meta-analysis. *Eur Radiol*. 2022;32(11):7927-7935. doi:10.1007/s00330-022-08804-5.

19. Pascall E, Tulloh RM. Pulmonary hypertension in congenital heart disease. *Future Cardiol*. 2018;14(4):343-353. doi:10.2217/fca-2017-0065.

20. Williams B, Mancia G, Spiering W, et al. 2018 ESC/ESH Guidelines for the management of arterial hypertension [published correction appears in Eur Heart J. 2019 Feb 1;40(5):475]. *Eur Heart J*. 2018;39(33):3021-3104. doi:10.1093/eurheartj/ehy339.

Contents list available at www.heartscience.ub.ac.id

Heart Science Journal

Journal Homepage : www.heartscience.ub.ac.id

Review Article

Echocardiographic Features in Patient Rheumatic Mitral Stenosis

Nur Kaputrin Dwigustiningrum[1*], Anna Fuji Rahimah[2], Wella Karolina[2], Heny Martini[2]

[1]Brawijaya Cardiovascular Research Center, Department of Cardiology and Vascular Medicine, Faculty of Medicine, Universitas Brawijaya, Malang, Indonesia.
[2]Department of Cardiology and Vascular Medicine, Faculty of Medicine, Universitas Brawijaya, Malang, Indonesia.

ARTICLE INFO

Keyword :
Echocardiography;
Rheumatic Heart Disease;
Mitral Stenosis.

ABSTRACT

Rheumatic mitral stenosis (RMS) is a progressive valvular heart disease that can lead to significant morbidity and mortality, especially in developing countries. Echocardiography plays a crucial role in the diagnosis, assessment, and management of patients with RMS. This study aims to review the utility echocardiography feature in patient RMS. We discuss the key echocardiographic parameters used for assessment and severity of RMS, and associated valvular abnormalities. Additionally, we explore the role of multimodality imaging, such as transesophageal echocardiography in enhancing the diagnostic accuracy and therapeutic decision-making in RMS. A thorough understanding of echocardiographic findings in RMS is essential for clinicians involved in the care of these patients, as it aids in risk stratification, treatment planning, and monitoring of disease progression. Integrating echocardiography is a widely used non-invasive method for comprehensive assessment, monitoring disease progression and evaluating treatment efficacy, ensuring optimal management for patient with RMS.

1. Introduction

Rheumatic mitral stenosis is a cardiovascular condition characterized by the narrowing of the mitral valve opening due to rheumatic fever. It is a prevalent cause of heart disease in many developing countries. Echocardiography, a non-invasive imaging technique, plays a crucial role in assessing and screening patients with rheumatic mitral stenosis.[1] Echocardiography assessment allows healthcare professionals to evaluate the severity of mitral stenosis, assess associated complications, and determine the most appropriate management strategies. By utilizing ultrasound waves, echocardiography provides detailed information about the structure and function of the heart, enabling accurate diagnosis and effective treatment planning.[2]

Echocardiography various parameters are evaluated, including valve morphology, valve area, pressure gradients, and left atrial size. These measurements aid in determining the severity of mitral stenosis and assist in making informed decisions regarding treatment options, such as medical therapy, balloon valvuloplasty, or surgical intervention.[3] These findings aid in risk stratification and guide the management of patients with rheumatic mitral stenosis.[4] Additionally, Furthermore, echocardiographic follow-up allows for monitoring disease progression and evaluating treatment efficacy, ensuring optimal patient care.[5] The advantage during an echocardiographic examination real-time imaging, allowing healthcare providers to visualize blood flow across the mitral valve and detect any abnormalities, such as regurgitation or thrombus formation.

Echocardiography plays a vital role in the assessment and management of patients with rheumatic mitral stenosis. This non-invasive imaging modality provides valuable information regarding the severity of the condition, associated complications, and treatment options. By utilizing echocardiography, healthcare professionals can effectively manage patients with rheumatic mitral stenosis, leading to improved patient outcomes and quality of life.[6]

2. Discussion

Definition of Rheumatic Mitral Stenosis

Rheumatic heart disease (RHD) occurs as a consequence of acute rheumatic fever (ARF), which develops when the body's immune system reacts to an infection caused by Streptococcus pyogenes (group A Streptococcus bacteria), commonly known as a throat infection.[7] The mitral valve is the most frequently affected valve, followed by the aortic valve, tricuspid valve (TV), and rarely the pulmonary valve. Scarred or damaged mitral valves due to RHD undergo alterations in the endothelial cells, making them more susceptible to colonization by circulating bacteria on the valve surface. The survival of these adherent bacteria eventually leads to the formation of infected vegetation.[8]

The development of RHD after ARF episodes is not universal and depends on factors such as the presence, type, or severity of valvular disease. When RHD involves the mitral valve, it can lead to congestive heart failure due to mitral stenosis (MS) and mitral regurgitation (MR).

* Corresponding author at: Brawijaya Cardiovascular Research Center, Department of Cardiology and Vascular Medicine, Faculty of Medicine, Universitas Brawijaya, Malang, Indonesia.
E-mail address: kaputrin@gmail.com (N.K. Dwigustiningrum).

https://doi.org/10.21776/ub/hsj.2024.005.02.5
Received 2 August 2023; Received in revised form 4 September 2023; Accepted 4 September 2023.
Available online 28 April 2024

In some cases, the aortic valve may also be affected.[7] MS is characterized by a narrowing of the valve orifice, leading to obstruction of blood flow to the left ventricle, and it is most commonly caused by rheumatic fever.[8]

Epidemiology of Rheumatic Mitral Stenosis

Rheumatic Mitral Stenosis presents a significant global health burden, affecting approximately 33 million people worldwide, with the majority of cases (80%) found in low- and middle-income countries (LMICs). It is responsible for about 275,000 deaths annually, with 95% occurring in LMICs. Among the complications associated with Rheumatic Mitral Stenosis, Atrial Fibrillation (AF) stands out as a major cause of morbidity and mortality in affected patients.[9]

The results of a recent meta-analysis by Noubiap et al showed that the prevalence of AF in rheumatic mitral stenosis was 32.8%, with the most severe valve abnormality rate being the mitral valve compared to the aortic valve (30.4% vs 6.3%). The frequency of AF is higher in mixed mitral valve disease than isolated stenosis or isolated regurgitation.[9] In Indonesia, there is still no definite prevalence data. Although it is estimated that the number of mitral stenosis is still large, data at Moehammad Hoesin Hospital Palembang for five years (1990-1994) shows that 13.94% of cases are related to heart valve disease. Rheumatic mitral stenosis appears to be more common in women, with the majority of cases at Dr. M. Djamil Padang in 2012-2016 occurred in women (72.3%).[4]

Anatomic and Pathophysiology of Mitral Valve

The mitral complex, which consists of the mitral annulus, mitral leaflets, chordae tendineae, and the LV wall with papillary muscles, [4] plays a crucial role in the left side of the cardiac system, from the left atrium to the left ventricle. The main hemodynamic abnormality in mitral stenosis is the obstruction of left ventricular inflow at the level of the mitral valve level due to limited mitral valve opening caused by abnormal mitral valve apparatus. This leads to increase pressure of left atrial, LA remodeling, and elevated pressure of pulmonary venous, resulting in symptoms like dyspnea and hemoptysis, as well as elevation pressure of pulmonary artery pressure elevation. In severe cases, pulmonary edema may occur when pulmonary venous pressure exceeds plasma oncotic pressure. Chronic pulmonary arterial hypertension may develop due to changes in the pulmonary arterioles, leading to dysfunction of right ventricular and congestive heart failure.[10]

The commissures, cusps, chordae, or a mix of these structures are only a few of the mitral valve apparatus components that might be abnormally affected by mitral stenosis. The rheumatic process causes commissural thickening and fusion, which limits leaflet movement and causes the mitral opening to become narrowing in shape. The subvalvular apparatus is frequently involved, and the mitral chordae can fuse, shorten, fibrosis, and calcify, which can cause mitral regurgitation. Streptococcal M proteins share epitopes with myosin and valve endothelium, and this molecular mimicry is thought to have a role in the development of rheumatic carditis. Cross-reactive antibodies that result cause the valve to be damaged, and turbulant blood flow via the stenotic valve adds to its thickening and calcification.[10]

Rheumatic carditis affects the mitral and other heart valves as well as the myocardium. Isolated mitral stenosis occurs in about a quarter to forty percent of patients, with as many as forty percent experiencing mitral stenosis and mitral regurgitation. The aortic and tricuspid valves may be involved in up to twenty-five percent of patients with rheumatic carditis, and left ventricular dysfunction may occur due to myocardial involvement directly or valvular dysfunction.[10]

Clinical Presentation and Diagnostic Challenges

An accurate and comprehensive examination involved the patient's medical history, symptoms, and physical examination (including auscultation) is essential in diagnosing rheumatic mitral stenosis (RMS). Typically, exertional dyspnea is the initial symptom, which progressively worsens as the valve damage advances. Heart failure symptoms develop over time as the valve lesions progress. Due to the gradual nature of the disease, some patients may not recognize their symptoms, especially in endemic regions where advanced valve damage can occur at a younger age. While some patients may be diagnosed after experiencing an episode of acute rheumatic fever (ARF), others, particularly in low- and middle-income countries (LMICs), may present without any prior symptoms or memory of ARF. The diagnosis of RMS is often made during clinical examination, where pathological heart murmurs are detected. In some cases, the first signs of RMS may appear during pregnancy or after complications like acute heart failure, atrial arrhythmia, embolic events, or infective endocarditis (IE). Most patients exhibit heart failure symptoms at the time of diagnosis, often detected through pathological heart murmurs during auscultation.[2]

Electrocardiography and chest radiographs are valuable initial assessment tools, revealing signs of left atrial or left ventricular enlargement and ventricular strain. More severe cases may show atrial fibrillation. Chest radiographs may also indicate an enlarged left atrium or left ventricle and signs of pulmonary venous congestion in advanced stages.[2]

Echocardiography plays a significant role in evaluating valve anatomy and hemodynamic consequences in RMS patients, eliminating the need for invasive catheterization procedures. Various echocardiographic screening methods can determine the severity of MS, guiding further management decisions, including medical therapy or the timing and type of intervention, based on prognostic factors and clinical findings.[4]

Echocardiographic Assessment of Rheumatic Mitral Stenosis

Table 1A. Anatomic/Morphological Parameters in the Echocardiographic Assessment of Mitral Stenosis.[3]

Valvular Findings	Associated Finding
• Extent and pattern of commissural fusion	• Left atrial size
• Degree and extent of valve thickening and calcification	• Presence of thrombi and/or spontaneous echo contrast (“smoke”) in the left atrium and/or appendage
• Degree of subvalvular abnormalities	• Right ventricular and atrial size
• Severity of valve narrowing (valve area and transvalvular gradient)	• Other co-existent abnormalities (e.g. multivalvular disease)

Table 1B. Classification of Mitral Stenosis Severity.[3]

	Progressive		
	Mild	Moderate	Severe
Valve area (cm^2)	>2.5	2.5-1.6	≤1.5
Pressure half-time (miliseconds)	<100	100-149	≥150
Mean gradient (mmHg)	<5	5-9	≥10
Systolic pulmonary artery pressure (mmHg)	<30	30-49	≥50

As an initial assessment of somebody with known or suspected RMS, a thorough Transthoracic Echocardiogram (TTE) with 2-dimensional (2D) imaging and Doppler interrogation is the standard diagnostic procedure. The TTE offers important supplementary information, such as an evaluation of other valve lesions and the effect of the valve obstruction on heart chambers and extraordinary vessels.

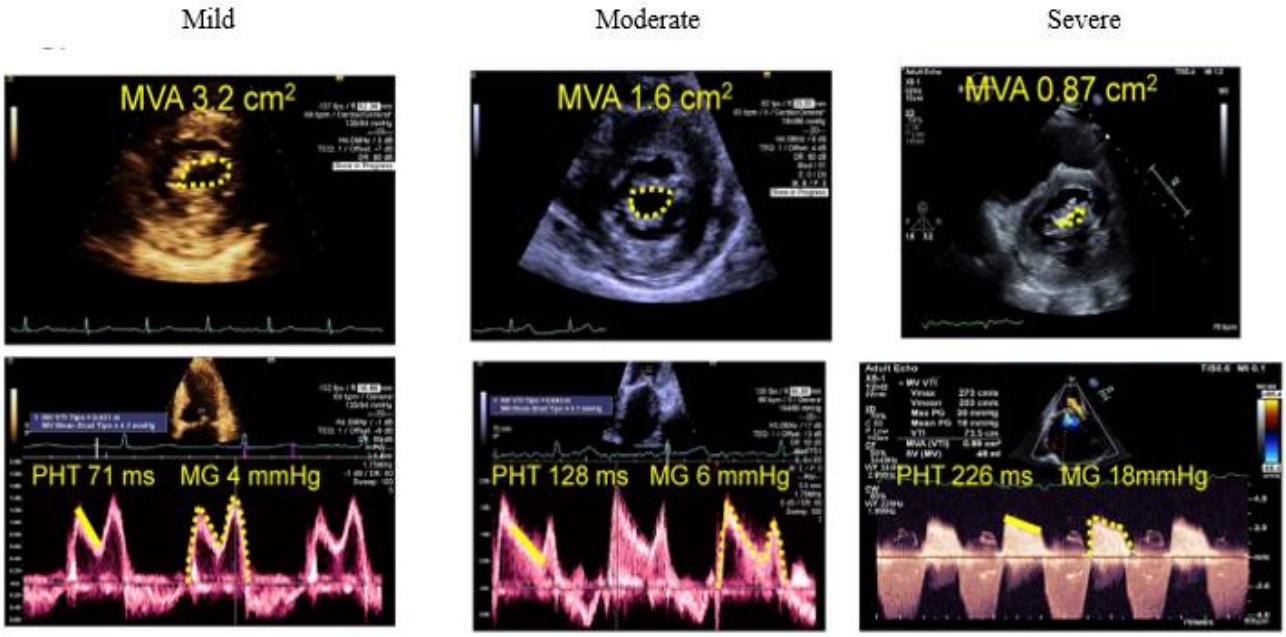

Figure 1. Stages of mitral stenosis by echocardiographic parameters. MVA, Mitral Valve Area; PHT, Pressure Half-Time; MG, Mean Gradient

Through TTE, it is possible to accurately assess the anatomy, etiology, co-occurring valve illness, and related anomalies including aortic dilatation. Due to the intrinsic measurement variability for these parameters, which is present in the linear dimensions, 2D and 3D volumes, and ejection fraction (LVEF) of the left ventricle (LV), it is crucial to take successive studies into account for sound conclusions. Doppler echocardiography provides a painless and precise.[8]

A comprehensive evaluation of valve morphology and related anomalies is necessary for anatomic evaluation of MS (Table 1A). The anterior mitral leaflet develops a distinctive "hockey-stick" or "doming" appearance during diastole as a result of the rheumatic involvement of the MV, which also manifests specific morphological features such as commissural fusion, leaflet thickening (with or without calcification), restricted leaflet motion, and chordal thickening and shortening. (Figure 2).[3]

Two-dimensional (2D) and three-dimensional (3D) echocardiography can be used from different view to assess the thickness and calcification of the mitral leaflets. While the restricted motion of the posterior mitral leaflet and commissural fusion, the primary obstruction mechanism, are best understood in short-axis orientations, showing a small central oval orifice with a distinctive "fish-mouth" appearance, diastolic doming of the anterior leaflet is best seen in long-axis views.[3]

Due to MV thickening and commissural fusion, the mitral valve area (MVA) is gradually decreasing. A common symptom of chronic severe mitral stenosis (MS) is calcification of the annulus and valve. MVA is a significant indicator of severity, with values greater than 2.5 cm^2 indicating asymptomatic patients, MVA between 1.5 and 2.5 cm^2 suggesting mild symptoms, and MVA less than 1.5 cm^2 indicating severe MS (table 1B). However, due to the progressive nature of MS, no single index value should be used to determine the severity of the disease. To take into consideration the anatomic and hemodynamic effects of MS, a thorough assessment of MS severity should use a multi-parametric approach that takes into account valve area, pressure half-time (PHT), transmitral mean pressure gradient, and pulmonary pressures.[3]

If a rheumatic process can be established in cases where the diagnosis of rheumatic MS is unclear by verifying commissural fusion in the parasternal short-axis view. Commissural fusion is a distinctive hallmark of rheumatic MS. It's crucial to distinguish between annular calcification and rheumatic MS since the former rarely results in considerable stenosis unless the calcification extensively affects the leaflets' basal regions, whilst the latter mostly affects the leaflets' tips and margins. It is advised to average at least five measurements for individuals with atrial fibrillation (AF) and irregular heartbeats in order to precisely determine pressure gradients and valve area while avoiding severe cycle lengths.[3]

Echocardiography-Guided Therapeutic Decision-Making

Echocardiography plays a crucial role in the evaluation of mitral valve (MV) anatomy, helping to identify the most suitable treatment option for patients. It allows for the assessment of various morphological features, including leaflet mobility, thickness, calcification, subvalvular fusion, and commissural fusion. Different scoring systems are utilized to describe the extent of MV disease, evaluate eligibility for balloon mitral valvuloplasty (BMV), and predict the success and potential complications following the procedure. While no individual scoring system has proven to be superior to others, the Wilkins score, also known as the "splitability score," is widely used and validated. This score assesses parameters such as leaflet thickness, leaflet calcification, leaflet mobility, and subvalvular apparatus involvement on a 1 to 4 scale, with a maximum total score of 16. An inverse relationship exists between the total splitability score and BMV success, with a cutoff of <8 indicating better short and long-term results.[11] This indicates that a mitral valve with a sufficiently pliable score is more likely to respond well to balloon dilatation.[14] While the The Wilkins score has been widely used because of its simplicity and predictability of patients with a successful versus unsuccessful outcome based on increased valve area, but it has limitations. Assessment of individual components remains semi-quantitative and adjusts for observer subjectivity, making it less reliable in classifying patients with scores in the middle range. Moreover, the Wilkins score does not assess commissure morphology, and consequently, is not successful for evaluating postprocedural mitral regurgitation (MR), which is an important predictor of long-term outcome. [12]

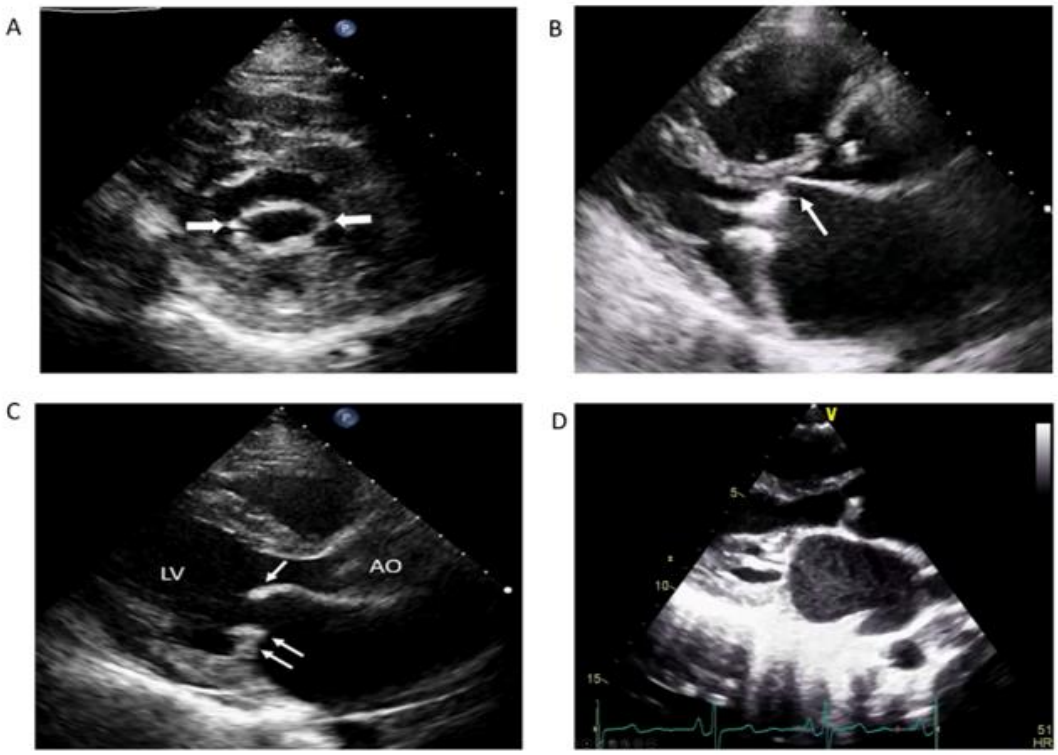

Figure 2. 2D echocardiography findings of MS. (A) Bi-comissural fusion (arrows) of a rheumatic valve in parasternak short-axis view. (B) Thickened and calcified mitral valve leaflets seen in parasternal long-axis view, with diastolic doming of the anterior leaflet (arrow). (C) Thickenend and doming mitrala nterior leaflet (single white arrow) and restricted motion odf posterior leaflet (double arrows) in parasternal long-axis view. (D) Chordal thickening and calcification seen in parasternal long-axis view.

Commissural calcification has been found to be a strong indicator of unfavorable results and severe MR after BMV. In order to predict patient outcomes after BMV, it is advised to employ a commissure score based on commissural morphology as a supplement to the Wilkins score. In contrast to calcified commissures that are resistant to splitting, highly fused, non-calcified commissures are more likely to split when given a high score. Echocardiography also enables the assessment of other valves and the determination of hemodynamic severity in coexisting lesions. BMV is not contraindicated in the presence of aortic regurgitation (AR) grade 2 or less and haemodynamically insignificant aortic stenosis (AS).

Similar to considerable tricuspid valve regurgitation (TR), which is often attributable to right ventricular and tricuspid annular dilatation brought on by chronic pulmonary hypertension (PH), severe TR is frequently seen in patients with severe MS. Although the existence of such a functional TR is not a contraindication for BMV, it is a crucial technical factor, especially in situations where the RA is dilated.[11]

The management of rheumatic mitral stenosis is shown in Figure 3. Echocardiographic imaging plays a crucial role in excluding contraindications to balloon mitral valvuloplasty (BMV).[11] Aortic valve disease, severe combined tricuspid stenosis and regurgitation requiring surgery, left atrial thrombus, more than mild mitral regurgitation (MR), severe or bi-commissural calcification, absence of commissural fusion, and significant concomitant aortic valve disease may all contraindicate BMV. Concomitant coronary artery disease (CAD) may also require bypass surgery.[13]

Table 2. Assessment of mitral valve anatomy according to the Wilkins score.[12]

Grade	Mobility	Thickening	Calcification	Subvalvular thickening
1	Highly mobile valve with only leaflet tips restricted	Leaflet near normal in thickness (4-5 mm)	A single area of increased echo brightness	Minimal thickening just below the mitral leaflets
2	Leaflet mid and base	Midleaflets normal, considerable thickening of margins (5-8 mm)	Scattered areas of brightness confined to leaflet margins	Thickening of chordal structures extending to one-third of the chordal length
3	Valve continues to move forward in diastole, mainly from the base	Thickening extending through the entire leaflet (5-8 mm)	Brightness extending into the mid-portions of the leaflets	Thinckening extended to distal third of the chords
4	No or minimal forward movement of the leaflets in diastole	Considerable thickening of all leaflet leaflet tissue (>8-10 mm)	Extensive brightness throughout much of the leaflet tissue	Extensive thickening and shortening of all chordal structures extending down to the papillary muscles

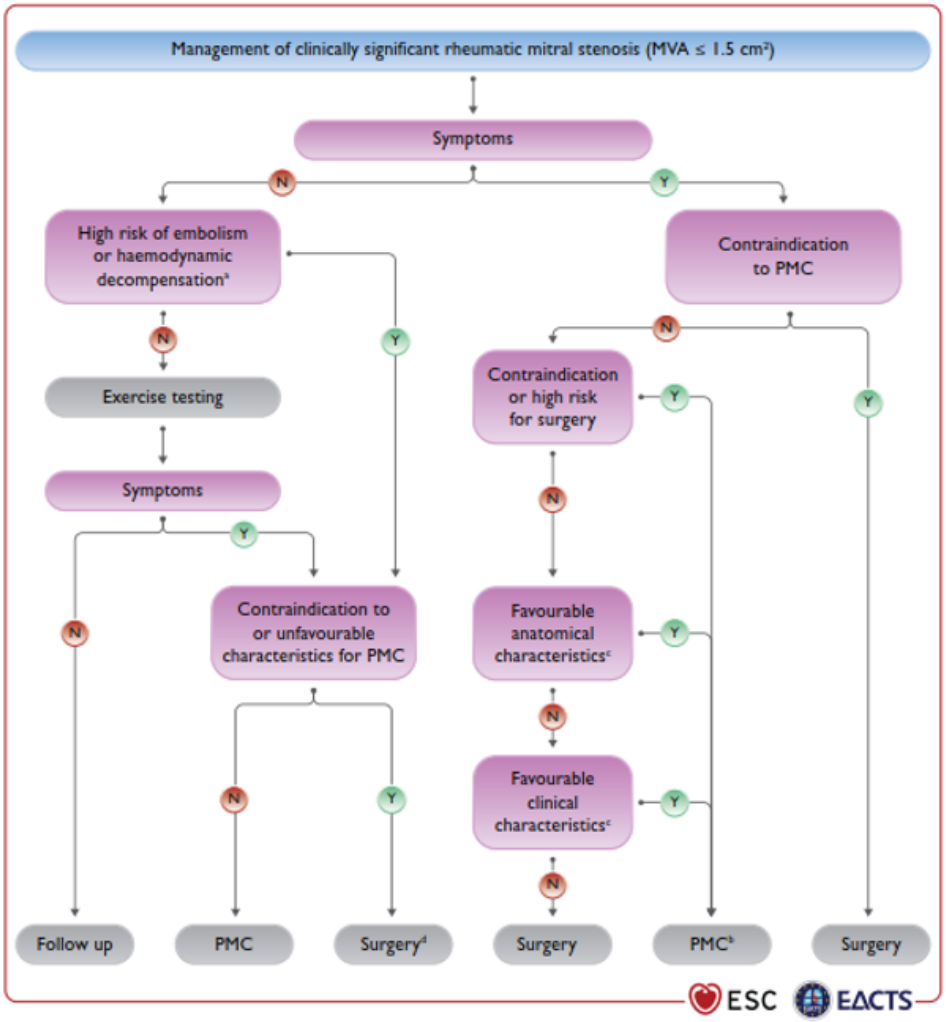

Figure 3. Management of clinically significant rheumatic mitral stenosis (MVA ≤1.5 cm²). AF = atrial fibrillation; LA = left atrium/left atrial; MVA = mitral valve area; NCS = non-cardiac surgery; PMC = Percutaneus mitral commissurotomy. [a]High thromboembolic risk: history of systemic embolism, dense spontaneus contrast in the LA, new-onset AF. High-risk of haemodynamic decompensation: systolic pulmonary pressure > 50 mmHg at rest, need for major NCS, desire for pregnancy. [b]Surgical commisurotomy may be considered by experienced surgical teams in patients with contraindications to PMC. [c]See recommendation on indications for PMC and mitral valve surgery in clinically significant mitral stenosis. [d]Surgery if symptoms occur for a low level of exercise and operative risk is low

Echocardiographic Guidance during Percutaneous Balloon Mitral Valvuloplasty (PBMV)

PBMV is considered a safe and effective treatment option for selected symptomatic patients with RMS. The pathogenesis of RMS, caused by rheumatic fever, leads to commissural fusion of the mitral valve, resulting in narrowing of the valve orifice and obstruction. To be effective, requires the presence of commissural fusion.[14] The procedure is typically guided by fluoroscopy and angiography; however, these imaging techniques have limitations, such as radiation exposure, two-dimensional projection of a three-dimensional organ, lack of accurate tissue differentiation, and the use of radiographic contrast agents. In contrast, echocardiography offers unique characteristics that make it an ideal technique for guiding percutaneous catheter-based procedures.[15]

Echocardiography's portability, real-time imaging, and accurate assessment of the target structure's anatomy and physiology make it well-suited for PBMV. Three-dimensional echocardiography is also used to provide accurate procedural guidance, early detection of problems, and close post-procedure patient follow-up, all of which contribute to a positive outcome.[15] The role of transesophageal echocardiography (TEE) in patients undergoing PBMV has expanded beyond its initial evaluation of left atrial thrombus to serve as an additional guiding tool during the procedure. TEE assists with septal puncture, early result evaluation, and complication detection, ultimately reducing the rate of complications resulting from transseptal catheterization and balloon valvuloplasty, as well as procedure and fluoroscopy times. Seong-Hoon Park et al reported transesophageal echocardiography (TEE) can be used effectively during balloon mitral valvuloplasty, and it may help to reduce the rate of complications resulting from transseptal catheterization and balloon valvuloplasty and to reduce procedure time and fluoroscopy time.[16] Yao Liu et al reported that PBMV could be successfully performed under only echocardiography guidance and appeared safe and effective while avoiding radiation and contrast agent use.[17] In some cases, interventionalists may find the multiple imaging planes of two-dimensional TEE unfamiliar, leading to potential misinterpretation. Three-dimensional images obtained with real-time three-dimensional TEE can resolve these misunderstandings due to their similarity to real anatomy, making them easier for interventional cardiologists to recognize.[15] Research has shown that three-dimensional echocardiography provides better accuracy and agreement with invasively determined mitral valve area (MVA) compared to conventional two-dimensional planimetry and is superior in assessing commissural opening.[14]

Transseptal (TS) puncture of the interatrial septum (IAS) is a common first step in several left-side percutaneous procedures, including PBMV. In patients with dilated atria or atypical IAS morphology, TEE or intracardiac echo guidance is especially beneficial. The optimal TS puncture site is in the posterior, more inferior portion of the fossa ovalis. The mid-esophageal short axis view at the level of the aortic valve (30°–60°) and the bicaval view (90°–110°) are the TEE views that are advised.[15] Particularly for patients with dilated atria or unusual interatrial septum (IAS) morphology, like a large atrial septal aneurysm, past IAS surgery, distortion from scoliosis, or previous pneumectomy, TEE or intracardiac echo guidance may be helpful. On TEE, a tent-like depression of the IAS can be used to identify the needle tip used for transseptal (TS) puncture. The anterior-posterior orientation is achieved with a short-axis view at the base (30°-45°), the superior-inferior orientation is observed on a long-axis view (90°-100°), and the height above the valve is best visualized in the 4-chamber view (0°). By simultaneously displaying anterior-posterior and superior-inferior orientations, X-plane imaging makes TS piercing easier. The PMBV catheter and balloon are placed across the mitral valve leaflets following TS puncture.[14]

It is important to evaluate potential complications including pericardial effusion and left-to-right shunt through the artificial atrial septal defect (ASD) caused by the TS puncture. Due to factors such atrial compliance, the existence of a newly generated ASD, and changes in hemodynamics affecting this measurement, the pressure half-time method for determining MVA becomes unreliable after PBMV.[14]

Successful PBMV is typically defined as an MVA of 1.5 cm^2 or more, or 1.0 cm^2 or more with MR (mitral regurgitation) 2+ or less, and the absence of complications. Several clinical, morphological, and hemodynamic parameters have been identified as predictors of outcome after PMBV. Predictors of outcome after PMBV are listed in Table 3, encompassing various clinical, morphological, and hemodynamic parameters. The peri-interventional role of echocardiography is summarized in Table 3.[14]

Table 3. Role of Echocardiography during Percutaneous Balloon Mitral Valve

Reassessment of mitral valve pathology before the procesure (MS and MR) and identification of contraindication
Guidance of transseptal puncture
Optimazation of transseptal puncture
Assessment of residual MS after PBMV
Assessment of MR severity after PBMV
Assessment of complication

Echocardiographic for Long-term Monitoring and Follow-up Strategies

Asymptomatic patient with RMS

Transthoracic echocardiography (TTE) and regular exams are essential monitoring of asymptomatic patients with rheumatic mitral stenosis (RMS). The purpose of follow-up is to prevent the severe RMS's irreversible effects, which can impact the ventricles and pulmonary circulation in particularly, which can develop without apparent symptoms. These individuals should have history and physical exams at least once a year. The type and severity of the valve lesion, the known pace of progression of the particular valve lesion, and its effects on the affected ventricle all affect how frequently 2D and Doppler echocardiography is repeated. For individuals with mild regurgitation who exhibit no changes during a 10- to 15-year period, the interval between follow-ups may be extended. The beginning of symptoms or any changes noticed during the physical examination should raise concerns about the cardiac response to the valve lesion in addition to routine periodic imaging, prompting a repeat TTE for additional investigation.[18]

Table 4. Frequency of Echocardiograms in Asymptomatic Patients with VHD and Normal LV Function.[11]

Stage	Mitral Stenosis
Progressive (Stage B)	Every 3-5y (MV are >1.5 cm^2)
Severe symptomatic (Stage C)	Every 1-2y (MV area 1.0-1.5 cm^2) Every year (MV area <1.0 cm^2)

Patients after underwent BMV

The most important parameter for predicting the success of balloon mitral valvuloplasty procedure is the improvement in mitral valve area. Various surrogate echocardiographic parameters have been proposed and validated against mitral valve area to assess the severity of mitral stenosis. The mitral valve area can be measured using planimetry, pressure half-time, continuity equation, and proximal isovelocity surface area methods. Several echocardiographic parameters are available to predict successful of BMV.[19]

After the procedure, mean Doppler gradients and planimetry are used in two-dimensional (2D) echocardiography to evaluate the post-procedure mitral valve area. MR severity and location are assessed by three-dimensional (3D) echocardiography, if it is available, to assess commissural opening. Echocardiography is also performed to find any residual atrial level shunts. Periodic checking of pulmonary artery pressures is essential after successful BMV, particularly in younger individuals, as it leads to a significant regression of pulmonary hypertension. BMV is a palliative treatment, and that all patients should have an echocardiogram within a year or earlier (if the findings are less than optimum). This follow-up is intended to keep an eye on any changes to the hemodynamics of the valves, the progression of lesions in other valves, the regression of pulmonary hypertension and tricuspid regurgitation, and mitral regurgitation (MR).[11]

Real-time 3D echocardiography has shown superior accuracy and agreement with invasively determined mitral valve area (MVA) compared to conventional 2D planimetry. Furthermore, real-time 3D echocardiography offers clearly view of the commissural opening, a strong predictor of long-term outcomes, linked to a larger MVA, lower gradients, and better functional outcomes. It is important to consider that measures of MVA and gradients made immediately following a procedure might be different from those made later, after left atrial remodeling and changes in left atrial wall compliance. Mitral gradients are also affected by changes in heart rate, thus it's important to carefully interpret comparative findings with this in mind. Left atrial pressure, mean mitral gradient, and pulmonary artery systolic pressure all markedly drop after percutaneous balloon mitral valvuloplasty (PBMV), and mitral valve area increases in line with these changes.[11]

Multimodality Imaging of Rheumatic Mitral Stenosis

Role of Transesophageal Echocardiography (TEE)

When patients have inadequate transthoracic acoustic windows, transesophageal echocardiography (TEE) is an essential tool for assessing mitral stenosis (MS). It is especially helpful to rule out thrombi in the left atrium (LA) and/or LA appendage and to evaluate the morphology of the mitral valve (MV) before to PBMV. Transthoracic echocardiography (TEE), with or without 3D capability, offers better visualization of morphological abnormalities. 3D TEE is especially valuable for evaluating commissural fusion and MV area by planimetry. By displaying the complete delineation of the LA appendage and the anatomy of the interatrial septum, it aids in the planning of PBMV. Because of the young age and higher number of female patients who may have late diagnosis during pregnancy, using 3D TEE during PBMV promotes safe trans-septal puncture, appropriate balloon orientation, and minimizes or eliminates the requirement for radiation exposure.[20]

Role of Stress Echocardiography

When imaging results and symptoms do not correlate, stress echocardiography, utilizing exercise or dobutamine, is helpful to determine the hemodynamic severity of MS.[2] It is recommended for asymptomatic people with severe MS seen on echocardiography or for symptomatic patients with mild or moderate MS found on echocardiography. It enables medical professionals to assess the true hemodynamic load of MS.[20] The increase in heart rate and cardiac output brought on by stress allows us to assess the hemodynamic behavior of the valvular blockage and its effects on the pulmonary circulation. By identifying any differences between resting echocardiographic data and symptoms, it also helps with risk classification in patients with moderate stenosis. Transmitral gradient, stroke volume, MVA, pulmonary artery systolic pressure (PASP), left ventricular (LV) and right ventricular (RV) function, and any changes in mitral regurgitation (MR) are a few of the echocardiographic measurements that need to be made during a stress test. Exertional dyspnea caused by the hemodynamic effects of MS may be explained by a rise in transmitral mean gradient of >15 mmHg with exercise or >18 mmHg with dobutamine infusion. This can help identify high-risk patients who might benefit from intervention. Another indicator of hemodynamically significant MS has been thought to be a stress-induced PASP >60 mmHg, although this indicator should be interpreted in the context of age and other diagnostic indices. Prognostic implications could also result from an early rise in PASP greater than 90% higher than its resting value.[2]

The measurement of pulmonary artery pressure during stress echocardiography (dobutamine or exercise) aids in determining the best course of treatment or additional measures. For determining MS severity and hemodynamic burden, exercise stress echocardiography, preferably performed while supine, is favored over pharmaceutical stress echocardiography. Exercise-induced symptom detection in asymptomatic patients with moderate-to-severe MS is one of its key applications. For individuals who are unable to exercise, dobutamine stress echocardiography is an option. Patients who have MV morphology that is favorable for PBMV and who are symptom-free but who have considerable objective limits on exercise may be candidates for PBMV. An MV area bigger than 1.5 cm2 with a transmitral mean gradient of more than 15 mm Hg and a pulmonary artery wedge pressure less than 25 mm Hg, or the pulmonary artery systolic pressure is greater than 60 mm Hg during exercise are requirements for considering PBMV.[20]

Cardiac Magnetic Resonance

If transthoracic echocardiography (TEE) is unfavorable or inconclusive, or if TEE is otherwise contraindicated, cardiac magnetic resonance (CMR) may be a helpful option. Restricted MV leaflets can be clearly seen on CMR, especially in the left ventricular outflow tract image. Strong correlation exists between the pressure half-time approach and direct planimetric assessment of the stenotic orifice area by CMR. On the basis of intrinsic tissue properties and anatomic appearance, CMR also provides observation of the morphology and thrombus of the LA appendage. Using phase-contrast imaging, one may determine MVA, pressure half-time, and velocities. Due to the low temporal precision of CMR, which could result in an underestimation of peak velocities, it does, however, require careful performance. Measurement of RV and LA remodeling as well as LA fibrosis detection are both possible with CMR. If both echocardiography and multi-detector computed tomography (MDCT) are inconclusive, CMR is considered the third-choice imaging modality.[20]

Invasive Assessment

When there is a mismatch between clinical complaints and echocardiographic findings, or as part of a planned catheter intervention, invasive examination may be required. In addition to information acquired from non-invasive testing, catheterization gives precise estimates of left atrial pressures (measured as pulmonary capillary wedge pressure), ventricular filling pressures, and cardiac output that can be used to help create a treatment plan. Patients with severe RMS and adequate valve morphology most frequently undergo PBMV, which has substantial advantages for them.[8]

Management Patient with RMS

Medical Management

When evaluating patients with Rheumatic Mitral Stenosis, it is crucial not to neglect standard guideline-directed medical therapy (GDMT) for cardiac risk factors such as hypertension, diabetes mellitus, and hyperlipidemia. Patients with Rheumatic Mitral Stenosis should adhere to heart-healthy lifestyle factors, which include regular exercise, a healthy diet, avoiding smoking, and maintaining a normal body weight, similar to the general population. If it is not possible or declined, the patient should continue with GDMT (Guideline-Directed Medical Therapy) for left ventricular systolic dysfunction. This includes medications like diuretics, angiotensin-converting enzyme (ACE) inhibitors, angiotensin receptor blockers (ARBs), beta-blockers, aldosterone antagonists, and/or sacubitril/valsartan. Biventricular pacing should also be considered as indicated in heart failure guidelines. Avoid abruptly reducing blood pressure when there are stenotic valve lesions. Additionally, appropriate patient groups should receive prophylaxis for rheumatic fever and infective endocarditis (IE). Maintaining optimal oral health is of utmost importance in preventing IE. Patients with valvular heart disease should also follow standard recommendations for influenza and pneumococcal vaccinations.[18]

Since medicine therapy has not been proven to be effective in slowing the disease's progression, the main goal of treatment is to cure underlying heart failure and left ventricular dysfunction in order to reduce symptoms. Patients with rheumatic heart disease frequently have atrial fibrillation (AF), which is a substantial source of morbidity and mortality. For AF patients, anticoagulation is advised to lower their risk of cardioembolic events. Although oral Vitamin K antagonists are the recommended treatment, both patients and healthcare professionals must deal with a number of difficulties with them.[21]

Interventional Management

Evidence on balloon mitral valvuloplasty (BMV) for Rheumatic Heart Disease continues to grow, and indications have expanded considerably over the past decade, now encompassing challenging and unfavorable mitral valve involvement. Percutaneous valve interventions are continuously evolving worldwide, with transcatheter aortic valve implantation being a notable example for aortic stenosis treatment. This success has sparked interest in using percutaneous valve interventions as a viable treatment option for both aortic and mitral diseases, including repeated interventions, which are common in Rheumatic Heart Disease.[21]

Patients with severe valvular heart disease (VHD) are typically the only ones who can benefit from surgical and transcatheter treatments. However, for patients at risk of Rheumatic Mitral Stenosis (RMS) or those with mild to moderate valve dysfunction, other essential aspects of management are equally important. These include accurate diagnosis, patient education, regular observation, and medical treatment. The presence of symptoms, the severity of RMS, the response of the left ventricle (LV) and/or right ventricle (RV) to volume or pressure overload caused by RMS, and the impact on the pulmonary or systemic circulation all play a role in the decision to intervene and the frequency of monitoring. Improved symptoms, longer survival, and reduced risk of consequences from RMS, including irreversible ventricular dysfunction, pulmonary hypertension, stroke, and atrial fibrillation (AF), are the ultimate goals of valvular intervention. Regular monitoring and early intervention when necessary can have a significant impact on the long-term outcomes and quality of life for patients with Rheumatic Mitral Stenosis.[18]

3. Conclusion

Rheumatic mitral stenosis is a condition where the mitral valve becomes narrowed due to scarring and fusion of the valve leaflets, resulting from rheumatic fever. Echocardiography assessment

plays a crucial role in patients with rheumatic mitral stenosis. Echocardiography, specifically transthoracic echocardiography (TTE), is a non-invasive imaging technique that provides detailed information about the structure of anatomic and hemodynamic of the affected valve lesion including the assessment and severity of rheumatic mitral valve stenosis. Echocardiography can also guided therapeutic decision-making, intraprocedural echocardiographic guidance during catheter-based and long-term monitoring and follow up strategies. Many echocardiographic parameters for predicting successful of BMV are available. By combining these echocardiographic findings, clinicians can determine the severity of mitral stenosis, guide treatment decisions, and monitor disease progression. Echocardiography is a valuable tool in the diagnosis, and management of patients with rheumatic mitral stenosis, providing essential information for appropriate patient care and intervention.

4. Declaration

4.1 Ethics Approval and Consent to participate
Not applicable.

4.2. Consent for publication
Not applicable.

4.3 Availibility of data and materials
Data used in our study were presented in the main text.

4.4 Competing interests
Not applicable.

4.5 Funding Source
Not applicable.

4.6 Authors contributions
Idea/concept: NKD. Design: NKD. Control/supervision: AF, WK, HM. Data collection/processing: NKD. Analysis/interpretation: NKD, AF. Literature review: NKD. Writing the article: NKD. Critical review: AF, WK, HM. All authors have critically reviewed and approved the final draft and are possible for the content and similarity index of the manuscript.

4.7 Acknowledgements
We thank to Brawijaya Cardiovascular Research Center

References

1. Peters F, Karthikeyan G, Abrams J, Muhwava L, Zühlke L. Rheumatic heart disease: Current status of diagnosis and therapy. *Cardiovasc Diagn Ther*. 2020;10(2):305-315. doi:10.21037/CDT.2019.10.07

2. Kumar RK, Antunes MJ, Beaton A, et al. Contemporary Diagnosis and Management of Rheumatic Heart Disease: Implications for Closing the Gap A Scientific Statement From the American Heart Association. *Circulation*. 2020;142(20):E337-E357. doi:10.1161/CIR.0000000000000921

3. Pandian NG, Kim JK, Arias-Godinez JA, et al. Recommendations for the Use of Echocardiography in the Evaluation of Rheumatic Heart Disease: A Report from the American Society of Echocardiography. *J Am Soc Echocardiogr*. 2023;36(1):3-28. doi:10.1016/j.echo.2022.10.009

4. Ong LT. An Overview of Pathogenesis, Complications and Management of Rheumatic Heart Disease. *Biomed J Sci Tech Res*. 2020;29(3):22392-22395. doi:10.26717/bjstr.2020.29.004793

5. Cheng Y-L, Lee C-Y, Huang Y-L, et al. We are IntechOpen , the world ' s leading publisher of Open Access books Built by scientists , for scientists TOP 1 %. *Intech*. 2016;11(tourism):13. https://www.intechopen.com/books/advanced-biometric-technologies/liveness-detection-in-biometrics

6. Reméanyi B, Wilson N, Steer A, et al. World Heart Federation criteria for echocardiographic diagnosis of rheumatic heart disease-an evidence-based guideline. *Nat Rev Cardiol*. 2012;9(5):297-309. doi:10.1038/nrcardio.2012.7

7. Mukti M, Erwin Sukandi, Ali Ghanie, Taufik Indrajaya, Syamsu Indra. Anatomical and Hemodynamic Evaluation of Mitral Stenosis Patients with Echocardiography. *Biosci Med J Biomed Transl Res*. 2021;5(4):1010-1028. doi:10.32539/bsm.v5i4.378

8. Shenthar J. Management of atrial fibrillation in rheumatic heart disease. *Hear Rhythm O2*. 2022;3(6Part B):752-759. doi:10.1016/j.hroo.2022.09.020

9. Ralph AP, Noonan S, Wade V, Currie BJ. *The 2020 Australian Guideline for Prevention, Diagnosis and Management of Acute Rheumatic Fever and Rheumatic Heart Disease*. Vol 214.; 2021. doi:10.5694/mja2.50851

10. Mathematics A. *済無No Title No Title No Title.*; 2016.

11. Sharma S, Kolekar SS. Role of Echocardiographic Imaging in Percutaneous Balloon Mitral Valvotomy. *Cardiovasc J*. 2015;7(2):128-136. doi:10.3329/cardio.v7i2.22261

12. Nunes MCP, Tan TC, Elmariah S, et al. The echo score revisited: Impact of incorporating commissural morphology and leaflet displacement to the prediction of outcome for patients undergoing percutaneous mitral valvuloplasty. *Circulation*. 2014;129(8):886-895. doi:10.1161/CIRCULATIONAHA.113.001252

13. Vahanian A, Beyersdorf F, Praz F, et al. 2021 ESC/EACTS Guidelines for the management of valvular heart disease. *Eur Heart J*. 2022;43(7):561-632. doi:10.1093/eurheartj/ehab395

14. Wunderlich NC, Beigel R, Siegel RJ. The Role of Echocardiography During Mitral Valve Percutaneous Interventions. *Cardiol Clin*. 2013;31(2):237-270. doi:10.1016/j.ccl.2013.03.003

15. Patrianakos AP, Zacharaki AA, Skalidis EI, Hamilos MI, Parthenakis FI, Vardas PE. The growing role of echocardiography in interventional cardiology: The present and the future. *Hell J Cardiol*. 2017;58(1):17-31. doi:10.1016/j.hjc.2017.01.008

16. Park SH, Kim MA, Hyon MS. The advantages of on-line transesophageal echocardiography guide during percutaneous balloon mitral valvuloplasty. *J Am Soc Echocardiogr*. 2000;13(1):26-34. doi:10.1016/S0894-7317(00)90039-7

17. Liu Y, Guo GL, Wen B, et al. Feasibility and effectiveness of percutaneous balloon mitral valvuloplasty under echocardiographic guidance only. *Echocardiography*. 2018;35(10):1507-1511. doi:10.1111/echo.14055

18. Otto CM, Nishimura RA, Bonow RO, et al. 2020 ACC/AHA Guideline for the Management of Patients With Valvular Heart Disease: A Report of the American College of Cardiology/American Heart Association Joint Committee on Clinical Practice Guidelines. *J Am Coll Cardiol*. 2021;77(4):e25-e197. doi:10.1016/j.jacc.2020.11.018

19. Ananthakrishna Pillai A, George G, Kottyen Thazhath H, Yerram S. Echocardiographic parameters for assessing successful balloon mitral valvuloplasty in juvenile age groups. *Cardiol Young*. 2016;26(7):1266-1273. doi:10.1017/S1047951115002243

20. Öz TK, Tok ÖÖ, Sade LE. New perspectives by imaging modalities for an old illness: Rheumatic mitral stenosis. *Anatol J Cardiol*. 2020;23(3):128-140. doi:10.14744/AnatolJCardiol.2020.01575

21. Rwebembera J, Nascimento BR, Minja NW, et al. Recent Advances in the Rheumatic Fever and Rheumatic Heart Disease Continuum. *Pathogens*. 2022;11(2):1-23. doi:10.3390/pathogens11020179

Contents list available at www.heartscience.ub.ac.id

Heart Science Journal

Journal Homepage : www.heartscience.ub.ac.id

Review Article

Cardioprotective Effect of Remote Ischemic Preconditioning: From Bench to Bedside

Imam Mi'raj Suprayoga[1*], Setyasih Anjarwani[2]

[1]Brawijaya Cardiovascular Research Center, Department of Cardiology and Vascular Medicine, Faculty of Medicine, Universitas Brawijaya, Malang, Indonesia.
[2]Department of Cardiology and Vascular Medicine, Faculty of Medicine, Universitas Brawijaya, Malang, Indonesia.

ARTICLE INFO

Keyword :
Cardioprotection;
Ischemic Preconditioning;
Remote Ischemic Preconditioning.

ABSTRACT

Remote ischemic preconditioning (rIPC) refers to a cardioprotective phenomenon in which short episodes of ischemia, followed by reperfusion, in one organ or tissue might provide future protection against ischemia/reperfusion damage in other organs, namely the heart. The process involves the activation of humoral, neural, or systemic communication channels, which in turn induce various intracellular signals inside the heart. The primary objective of this review is to provide a concise overview of the potential processes implicated in rIPC cardioprotection, as well as to elucidate current clinical studies aimed at establishing the effectiveness of these techniques in safeguarding the heart from detrimental ischemia/reperfusion injury. In this context, many variables contribute to the attenuation of subcellular processes of rIPC in patients, including advanced age, presence of comorbidities, medication use, and variations in anaesthetic protocols. These factors may account for the observed variability in outcomes across different clinical studies. Additional research, meticulously planned, is needed in order to enhance our comprehension of the pathways and mechanisms associated with both early and late rIPC. A comprehensive understanding of the various routes is crucial in facilitating the translation of medical advancements to the benefit of patients.

1. Introduction

Remote ischemic preconditioning (rIPC) refers to the occurrence in which short periods of ischemia and reperfusion, administered to a particular organ or tissue, provide protection to a distinct organ or cardiovascular region against subsequent bouts of ischemia and reperfusion.[1] The approach was elucidated by Przyklenk in the year 1993. The researchers administered anaesthesia to canines and conducted four instances of five-minute ischemia in the left circumflex coronary area. This was followed by a persistent ischemic insult lasting one hour in the left anterior descending coronary artery bed. In contrast to the control group of dogs who just had left anterior descending occlusion, the experimental group of animals that experienced short periods of circumflex occlusion prior to continuous left anterior descending occlusion exhibited a significant decrease in the extent of the myocardial infarction. Therefore, Przyklenk et al. expanded upon the notion of "Classic" ischemia preconditioning by demonstrating that several, short-term occlusions of a coronary artery provide protection not just to the specific region supplied by that artery, as proposed by Murry et al., but also to adjacent regions of the myocardium.[2] The term "regional ischemic preconditioning" was assigned to this intracardiac protection technique. This occurrence has presented the potential for the induction of protective mechanisms in distal tissue/organs via ischemia, a notion that has been corroborated by other researchers. A significant breakthrough in cardiac rIPC was achieved by the use of skeletal muscle as the ischemic stimulus. The application of a tourniquet to a limb has the potential to induce rIPC without the need for intrusive procedures. This procedure enables the extrapolation of rIPC to the clinical context of acute ischemia/reperfusion damage.[3]

This article aims to give a concise overview of the pathophysiological principles behind cardiac rIPC and to provide illustrative instances of potential therapeutic applications, while also providing a quick overview of the principal clinical studies conducted in this field.

2. Discussion

Mechanisms Implicated in Remote Ischemic Preonditioning

The cardioprotection provided by rIPC follows a similar pattern to that of "classic" preconditioning, occurring in two distinct periods. The first stage, also known as the "first window," has a duration of roughly four hours. On the other hand, the subsequent stage, referred to as the "second window" of protection, begins around 24 hours following the onset of ischemia and remains effective for a minimum of 48 hours. During the first stage, there are prompt chemical alterations occurring in the cardiomyocytes that result in a reduction in infarct size and mitigate the likelihood of reperfusion arrhythmias. The protein synthesis-dependent mechanism behind the second window of cardioprotection aligns with the alterations seen in cardiomyocyte gene expression and leukocyte activity during the post-myocardial ischemia interval.[4]

* Corresponding author at: Brawijaya Cardiovascular Research Center, Department of Cardiology and Vascular Medicine, Faculty of Medicine, Universitas Brawijaya, Malang, Indonesia.
E-mail address: imamsuprayoga@student.ub.ac.id (I.M. Suprayoga).

https://doi.org/10.21776/ub/hsj.2024.005.02.6
Received 15 November 2023; Received in revised form 4 December 2023; Accepted 10 December 2023.
Available online 28 April 2024

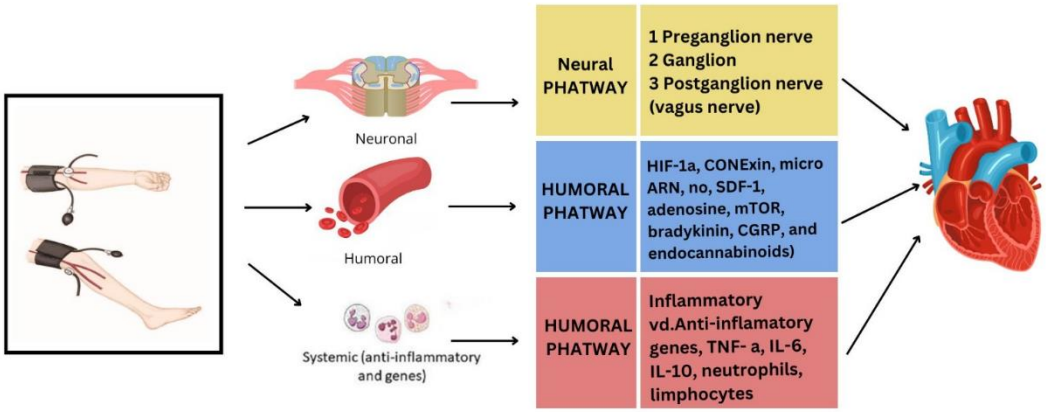

Figure 1. The signalling pathways behind rIPC cardioprotection. Intermittent limb ischemia and reperfusion have been shown to provide cardioprotection via many mechanisms, including neuronal, humoral, and systemic pathways. CGRP Calcitonin gene-related peptide, NO nitric oxide, ROS reactive oxygen species, ApoA1 apolipoprotein A-1, GLP-1 glucagon-like peptide-1, IL-10 Interleukin 10[8]

The precise pathophysiological mechanisms underlying remote ischemic preconditioning (rIPC) remain incompletely elucidated. However, these mechanisms can be categorised into three main components: (a) the liberation of the effector(s) within the distant ischemic tissue or organ; (b) the communication pathway connecting the remote territory to the myocardium; and (c) the initiation of a cardioprotective response, as depicted in Figure 1.[5]

The First Stage of Remote Ischemic Preconditioning

Episodes of transient ischemia followed by reperfusion induce the release of several chemical substances by the ischemic tissue or organ, as shown in Table 1. The presence and activity of different protective substances and processes may vary based on the anatomical site of the stimulus, such as the kidneys, mesentery, or skeletal muscles. Hence, the generalisation of results from one experimental approach to another is not feasible as a result of these variations. An exemplification of this phenomenon may be seen in the instance of hexamethonium, a pharmaceutical substance that functions as a ganglionic blocker. Previous studies have shown that hexamethonium has the ability to fully abolish the protective effects elicited by mesenteric ischemia, while leaving the protection generated by renal ischemia unaltered. The cardioprotection conferred by these mediators is attained by neuronal and/or humoral pathways, with substantiating data available for both mechanisms.[6]

The neural theory suggests that chemicals generated inside ischemic tissue or organs have a localised effect via sensory neural pathways, triggering various motor pathways that promote cardioprotection. Conversely, the humoral theory posits that the ischemia shock triggers the release of chemicals into the bloodstream, which subsequently reach the myocardium and provide a protective influence. Research has shown that in order to elicit the protective effect, reperfusion of the distant organ or tissue must occur prior to the initiation of coronary ischemia.[7]

The comprehensive understanding of the underlying processes of rIPC remains incomplete. Several investigations have shown that there are parallels in the underlying process between "classic" preconditioning and rIPC. As previously stated, the subject matter may be categorised into three distinct components: (a) the humoral pathway, (b) the neural pathway, and (c) the systemic pathway (refer to Figure 1). Nevertheless, the extent to which these pathways individually provide a protective impact on the target organ, as well as the potential involvement of crosstalk between them, remains little understood. It is plausible that these phenomena are not inherently incompatible and perhaps represent distinct aspects of the same pathophysiological sequence.[1]

Humoral Pathway

Multiple findings support the concept that the humoral factor transduces rIPC signals. Circulation carries protective chemicals throughout the body. They connect to receptors and start intracellular signalling pathways in the heart. Konstantinov et al. examined the humoral channel effects of remote limb preconditioning on denervated donor heart recipient pigs. Their investigation showed a significant reduction in infarct size, indicating humoral-mediated cardioprotection via rIPC. Dickson et al. showed that transferring blood from preconditioned rabbit hearts to a non-preconditioned isolated rabbit heart reduced infarct size. This research also showed that coronary effluent from a preconditioned ex vivo rabbit heart may boost a similar effect. Shimizu et al. found that plasma dialysate from a preconditioned rabbit and human blood applied remotely can protect the ex vivo rabbit heart from ischemia/reperfusion.[9]

Table 1. Different substances involved in the remote ischemic preconditioning mechanism[1]

Renal Ischemia	Adenosine Erythropoietin
Mesenteric Ischemia	Bradykinin Cannabinoids CGRP Opioids
Skeletal Muscle Ischemia	Adenisine Opioids NO Noradrenaline ROS ApoA-1 GLP-1 Stromal cell-derived factor-1a Prostanoitds IL-10 Glycine Exosomes and MicroRNAs

CGRP Calcitonin gene-related peptide, NO nitric oxide, ROS reactive oxygen species, ApoA1 apolipoprotein A-1, GLP-1 glucagon-like peptide-1, IL-10 Interleukin 10

The transfer of cardioprotection via plasma dialysate from one animal to another's heart shows humoral signalling. Several amino acids, cytokines, neuropeptides, and other chemicals, including as adenosine, Apo-A1, GLP-1, and nitrite, have been postulated as humoral components of rIPC.[1] In the heart, humoral factors activate intracellular signalling pathways that send cardioprotective signals to end-effectors. The intracellular routes are the nitric oxide synthase/protein kinase G route, the reperfusion injury salvage kinase pathway (RISK), and the survival activating factor enhancement (SAFE) pathway.[10]

The cardioprotective action of rIPC is likely mediated by humoral components that carry the protective signal from a distant tissue or organ to the target organ, namely the heart. These findings were reported in tests employing cardiac cross-perfusion with donor animal blood during rIPC. Peptides, endogenous opioids, endocannabinoids, endovanilloids, prostanoids, norepinephrine, adrenomedullin, leukotrienes, calcitonin gene-bound peptide, and exosome-bound miRNAs have been involved in this process.[11]

Weber et al. found that bilateral rIPC reduced kidney damage better than unilateral. This shows that conditioned tissue mass may affect protection. However, the best number of cycles, duration, and time of administration for ischemia/reperfusion remains unknown. In a mouse model of ischemia and reperfusion, Jhonsen et al. found that the number and length of cycles, not the number of limbs exposed, dictate the efficiency of rIPC. Additionally, their data imply that rIPC's protective effects fade 1.5 to 2 hours after stimulus removal.[12]

Therefore, the signalling pathway of rIPC is characterised by a high degree of complexity, including several components and the intricate interaction between distinct humoral factors and their respective targets. Understanding the minimum effective dosage required to produce positive outcomes of an intervention has significant therapeutic significance. This particular set of information has potential use in the optimisation of rIPC protocols.[1]

Neural Communication Pathway

Different experiments have revealed that an intact neural route is essential for transmitting protective signals from a distant organ or tissue to the target organ during rIPC. The limb utilised for preconditioning must have innervation since the protective benefits of transient ischemia of a lower limb are lost when the femoral nerve or spinal cord is cut. Bilateral cervical vagal section eliminated the protective advantage of rIPC, whereas subdiaphragmatic vagal section did not. This supports the idea that a parasympathetic vagal pathway is involved in action. Mastitskaya et al. found that rIPC's cardioprotective effects are influenced by vagus nerve dorsal motor nucleus neurons. As said, the vagus nerve's efferent route sends the cardioprotective signal to the heart. Acetylcholine activates muscarinic receptors to cause preconditioning (IPC). By inhibiting synaptic vesicle neurotransmitter absorption, nicotinic receptor antagonists and reserpine may eliminate rIPC.[13]

In contrast, Gho et al. have shown evidence that the temporary blockage of the anterior mesenteric artery results in cardioprotective effects, which may be negated by the administration of ganglionic blockers. This conclusion was substantiated by the hypothesis that rIPC triggers the secretion of many chemicals, including adenosine, bradykinin, and CGRP, in the distant organ or tissue, therefore activating sensory neurons. According to Liem et al., adenosine has been proposed to be involved in a neuronal circuit associated with cardioprotection. The researchers documented that the release of adenosine by the mesenteric artery during the preconditioning stimulus resulted in a significant reduction in the extent of the infarct. Furthermore, they observed that this effect was nullified when hexamethonium was administered.[14]

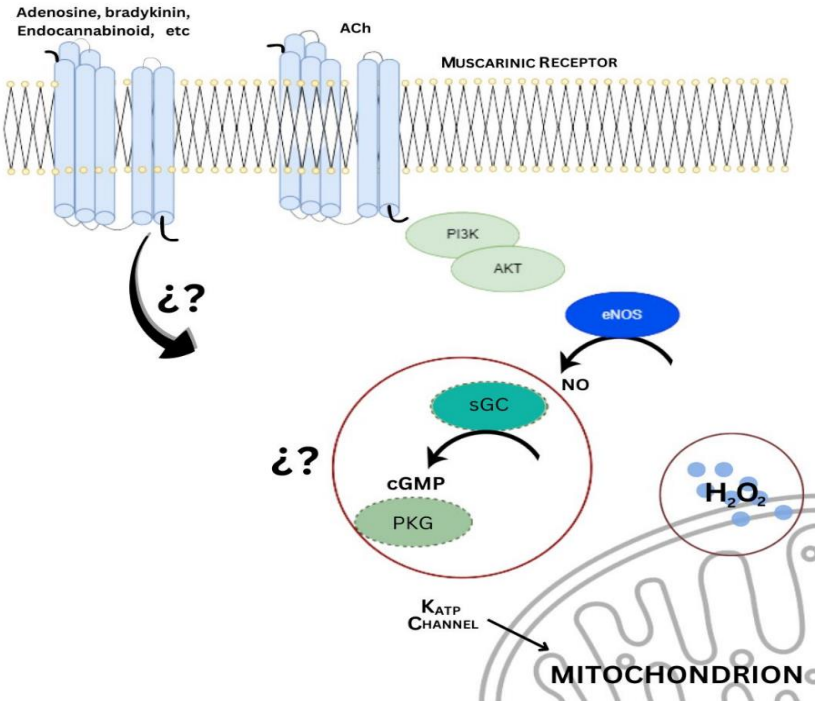

Figure 2. This study presents a schematic depiction of the intracellular pathways that are engaged by distant ischemic preconditioning prior to the onset of myocardial ischemia. Acetylcholine and other autacoids elicit the activation of distinct receptors that are situated inside the plasma membrane of cardiomyocytes. Specifically, the stimulation of muscarinic receptors resulted in the phosphorylation of Akt and eNOS enzymes. Following this, the activation of soluble guanylate cyclase and protein kinase G may result in the opening of mKATP channels and an elevation in the generation of mitochondrial H2O2. Thus, it is plausible that hydrogen peroxide (H2O2) may function as a secondary messenger for the protective signal of rIPC. eNOS endothelial nitric oxide synthase, mKATP mitochondrial KATP channels, NO nitric oxide, P13K Phosphatidylinositol 3-kinase, PKG protein kinase G, and sGC soluble guanylate cyclase.[1]

In contrast, our study revealed that rIPC elicits the activation of a parasympathetic pathway that leads to the activation of the Akt enzyme and phosphorylation of endothelial nitric oxide synthase (eNOS), opening of mitochondrial ATP-sensitive potassium (mKATP) channels, and formation of hydrogen peroxide (H2O2) in the cardiac tissue prior to the onset of myocardial ischemia. Hence, it is plausible to classify them as rIPC triggers (Figure 2).[1]

At now, there is a prevailing belief that the transmission of the rIPC signal to the designated organ involves many factors, including humoral, neuronal, and systemic systems. It is worth noting that the specific mechanisms involved in this transmission may vary depending on the model being studied. The dependence of humoral factor release in response to rIPC on sensory innervation to the preconditioned limb has been shown. Nevertheless, the specific outcome of activating sensory nerves, which subsequently triggers the release of a humoral factor, remains uncertain.[15]

On the other hand, it is well recognised that there is a cardiac intrinsic neuronal network responsible for the processing of sensory input and the regulation of efferent autonomic outputs originating from intrinsic cardiac ganglia. The neuronal network is also susceptible to ischemia/reperfusion injury and the subsequent remodelling that occurs after a myocardial infarction, leading to a deterioration in ventricular function. Hence, it is essential to investigate the function of these intracardiac neurons in the process of rIPC.[16]

The Delayed Phase of Remote Ischemic Preconditioning

The second window of protection, also known as the delayed phase of rIPC, is initiated by alterations in the gene expression associated with the myocardium's reaction to oxidative and inflammatory damage.[1]

The occurrence of cardiac tissue necrosis leads to the initiation of an inflammatory reaction that is distinguished by the infiltration of cells and the release of inflammatory signals. Neutrophils exhibit infiltration into the infarcted region during the first hours subsequent to the initiation of ischemic conditions. These cells play a crucial role in the innate immune response. These cells generate elevated amounts of ROS and release enzymes such as myeloperoxidase and proteases, therefore increasing the extent of vascular and tissue damage in the immediate vicinity.[17]

Konstantinov et al. found that rIPC reduces leukocyte inflammation in humans. In the acute phase of rIPC stimulation, genes involved in chemotaxis, adhesion and migration, exocytosis, apoptosis, and innate immunity were downregulated. The anti-inflammatory effects were substantially greater 24 hours after rIPC. The researchers found that postponed rIPC increases Hsp73 protein expression and protects Hadhsc, Prdx4, and Fabp4 from oxidative stress. However, numerous pro-inflammatory genes were downregulated.[9]

Previous studies have provided evidence indicating the involvement of nuclear factor kappa-B (NF-kB), a transcription factor that is sensitive to redox changes, in the regulation of many inflammatory genes (iNOS and inducible cyclooxygenase). These findings support the notion that NF-kB plays a role in rIPC cardioprotection. While the activation of NF-kB during ischemia/reperfusion is known to have negative consequences, such as the production of leukocyte adhesion molecules, cytokines, and chemokines, its activation during rIPC has been shown to have an adaptive effect during the delayed phase. This adaptive effect may be attributed to the upregulation of its inhibitor.[10]

Therefore, rIPC has the potential to mitigate the inflammatory response that occurs after reperfusion by activating NF-kB, which then upregulates the synthesis of its endogenous inhibitor, resulting in an elevation in NO production. The precise function of NO in the delayed phase remains uncertain; nonetheless, it is likely to have antiapoptotic and anti-inflammatory properties.[18]

In contrast, Singh et al. found that the neurogenic pathway is heavily engaged during late rIPC and adenosine preconditioning. The humoral and neurogenic pathways may act cooperatively to protect the heart, according to the scientists. Adenosine, a humoral molecule, may activate the neurogenic pathway and induce cardioprotection during rIPC.[1]

Chronic Effect of Remote Ischemic Preconditioning

Acute myocardial infarction (AMI) causes an abrupt increase in ventricular loading, which remodels the infarcted border zone and the non-infarcted myocardium elsewhere. After a myocardial infarction, ventricular remodelling comprises two phases: early in the first week and late thereafter. The initial stage involves infarcted region enlargement, which may cause early ventricular rupture or aneurysm. The next step of remodelling involves ventricular dilation, shape change, and hypertrophy.[5]

As previously stated, the first phase of remodelling is distinguished by the enlargement of the infarct due to the inflammatory response and the breakdown of the extracellular matrix (ECM) by serine proteases and the activation of matrix metalloproteinases (MMPs). The process of early remodelling is characterised by the occurrence of wall thinning and ventricular dilatation, which subsequently leads to an increase in diastolic and systolic wall stresses. The occurrence of ventricular dilatation in the early stages of infarct expansion has been conclusively seen in human subjects, and it serves as a significant factor in predicting the outcome of the condition. The process of late remodelling encompasses the enlargement of myocytes and alterations in the structure of the ventricles. These modifications aim to distribute the heightened pressures on the walls more uniformly. Additionally, the ECM develops a collagen scar to stabilise the forces causing expansion and to impede further deformation.[19]

Few studies have examined how rIPC affects ventricular remodelling. After reperfusion, rIPC was linked to lower levels of pro-inflammatory cytokines, IL-1β and TNF-α. IL-10 concentrations increase with rIPC given 24 hours before ischemia/reperfusion. STAT5, a transcription factor involved in the survival activating factor enhancement pathway, increases IL-10. In human heart injury, this route is downstream of JAK. In another study, rIPC increased IL-6 levels, which have reparative capabilities in myocardial infarction-affected myocardium, via early growth response protein 1.[13,20,21]

In stroke models, rIPC impacts circulating leukocytes and spleen immunological precursors. After rIPC, rats with middle cerebral artery closure infarction had enhanced splenic capacity and cerebral lymphocyte infiltration on day 3. Rat splenectomy reversed the aforementioned alterations, indicating splenic conditioning. Previous study has shown that rIPC activates the splenic-vagal nerve axis to protect the heart. Splenectomy and vagotomy diminish rIPC's cardioprotective effects, corroborating this. In SAFE, splenectomy lowers STAT3. Finally, IL-10 may aid splenic axis rIPC cardioprotection. Given the research, including ours, on the parasympathetic nervous system and rIPC, it would be fascinating to study how rIPC influences remodelling via modulating the inflammatory response.[1]

As previously said, the aforementioned data indicate that rIPC may serve as a viable approach for individuals experiencing left ventricular remodelling. Further investigations using larger patient cohorts and animal models are necessary to ascertain the specific contributions of rIPC in the process of left ventricular remodelling.[1]

Inter-Organ Preconditioning

Acute ischemia/reperfusion stress causes cell death in the heart, kidneys, liver, gut, lungs, brain, and skeletal muscle. Many organs and tissues share ischemia/reperfusion damage pathophysiology. Thus, emerging acute ischemia/reperfusion damage treatments seem to work similarly across numerous organs and tissues.

Thus, rIPC has been extended to several organs, establishing itself as a real inter-organ protection against acute ischemia/reperfusion harm.[22]

Due to its high energy needs and complicated microvascular network, the kidney is prone to ischemia/reperfusion injury. Various studies reveal rIPC's renoprotective benefits. These studies found that rIPC lowers serum creatinine, blood urea nitrogen, and histological damage relative to untreated controls. Interestingly, these studies found no difference between local and rIPC.[10]

In cardiac, orthopaedic, lung resection, and transplantation, acute lung damage causes morbidity and death. In CABG surgery, cytokine-mediated systemic inflammation impairs lungs. This response decreases alveolar oxygenation and increases pulmonary vascular resistance, necessitating artificial breathing. Peralta et al. discovered that liver rIPC decreased lung and other organ neutrophil concentration and systemic inflammation after prolonged hepatic ischemia/reperfusion. Researchers have explored how rIPC prevents acute lung ischemia/reperfusion damage in animals. These studies consistently lower systemic inflammatory markers, pulmonary edoema, and respiratory failure. Pulmonary vascular resistance, pressure, PaO2, and lung compliance decreased. Peak inspiratory pressure and pulmonary resistance decreased.[12]

In the first study on liver ischemia/reperfusion injury, hind-limb rIPC reduced ALT levels. It has been established that rIPC protects against acute hepatic ischemia/reperfusion injury in rats, rabbits, and mice by many authors using different procedures.[23] Stroke and carotid endarterectomy cause acute ischemia/reperfusion damage to the brain. Several studies suggest that rIPC may build brain resistance to ischemia/reperfusion injury. This mechanism improves cerebral perfusion, reduces cerebral infarction, and promotes cerebral collaterals. Previous investigations have indicated that rIPC reduces leukocyte migration and provides brain protection.[24]

Comprehensive experiments with several stimuli, focusing on cross-preconditioning, are advised. Using rIPC with pharmacological pretreatment may be a future therapeutic technique since it seems to mitigate the negative effects of ischemia/reperfusion injury across organs and tissues more effectively.[1]

Clinical Evidence and Potential Challenges of Remote Ischemic Preconditioning

The suitability of preconditioning procedures in the clinical environment is contingent upon the characteristics of the ischemia/reperfusion event, which may be either predictable, such as in the case of CABG surgery and elective percutaneous coronary intervention (PCI), or unanticipated, as shown in STEMI.[1]

A preliminary investigation conducted on paediatric patients following surgical repair of congenital heart diseases was among the first studies to use rIPC protocol. The findings of this study indicated that rIPC intervention resulted in a reduction in postoperative troponin I levels and a decreased need for inotropic support. A following experiment was conducted using a similar rIPC methodology, with a sample size of 57 patients having CABG. The findings of this trial demonstrated outcomes that were consistent with the aforementioned study. Subsequent to these first investigations, a series of modest nevertheless affirmative research have emerged, substantiating the advantageous impact of rIPC within the context of cardiac surgery. However, it is worth noting that a few studies have shown neutral or worse outcomes as well.[25]

Three big multi-center clinical trials on rIPC with cardiac surgery revealed modest cardioprotection. The first South Korean clinical study randomised 1280 heart surgery patients. Surgery includes CABG, valve replacement, congenital heart disease treatment, and aortic surgery. Mortality, myocardial infarction, arrhythmia, stroke, coma, renal failure or dysfunction, respiratory failure, cardiogenic shock, gastrointestinal problems, and multi-organ failure were not improved by rIPC before or after cardiopulmonary bypass. For reconciliation, ERICCA and RIPHEART examined different trial findings. ERICCA was a multicenter phase III study of 1612 CABG patients with or without valve surgery. Note that the study did not use conventional anaesthetic. Neutral except for the 6-minute walk test, which favoured rIPC. The phase III RIPHeart study comprised 1403 propofol-anesthetized heart surgery patients from several locations. The main endpoint and troponin release were neutral. Over 90% of ERICCA study participants and all RIPHeart trial participants used propofol anaesthesia without precautions as previously reported. Another potential complicating factor was the random assignment of all participants to rIPC, an upper arm blood pressure cuff.[26,2,5]

CABG surgery may not be ideal for rIPC evaluation. Due to advancements in surgery, anaesthesia, and cardioplegia, CABG surgery produces minimal myocardial damage. Myocardial damage in cardiac surgery may result from inflammation, direct heart manipulation, and coronary micro-embolization. Preconditioning methods, age demographics, comorbidities, pharmacological therapies, and anaesthetic procedures may affect rIPC surgical trial outcomes. Due to rIPC technique variations, clinical studies are not comparable, making cardioprotective strategy development challenging. The arm's rIPC efficacy is unknown because to considerable vascularization and innervation discrepancies between the upper and lower extremities. Dezfulian et al. discovered no significant variations in reactive hyperemia physiological response and plasma nitrite concentration when rIPC was delivered to the arm or thigh in healthy participants. The anatomical location for rIPC stimulus delivery should be considered in future investigations.[9]

rIPC may be more effective in AMI, when cardioprotection is greater. In STEMI patients, rIPC before thrombolysis or primary PCI reduces infarct size in many clinical studies. In their meta-analysis, Wang et al. evaluated rIPC in 16 randomised trials. The research found that recurrent, brief limb ischemia/reperfusion may preserve elective PCI patients' hearts and kidneys. However, rIPC does not reduce cTnI during PCI. In addition, Manchurov et al. found that rIPC before primary PCI improves endothelial function in acute myocardial infarction patients. Importantly, this benefit lasts at least one week. CONDI-2/ERIC-PPCI, a prospective, single-blind, randomised controlled study of 5401 STEMI patients after primary PCI, examined the impact of rIPC on clinical outcomes. The experiment divided patients into control and rIPC groups. The study found that rIPC did not enhance clinical outcomes in this patient group after one year. Thus, rIPC application in clinical settings remains problematic despite intensive study. Confounding factors may diminish rIPC's effect.[1]

Ageing reduces cardiomyocyte contractile function and cardioprotective systems. Certain interventions for elderly people may be limited by these changes. Comorbidities may also affect rIPC. Jensen et al. showed that type 2 diabetes causes ischemia/reperfusion damage resistance. High glycosylated protein levels modify mitochondrial function and inhibit mitochondrial permeability transition pore activity, causing this resistance. This is due to rIPC. The researchers found that dialysate from patients with and without diabetes, who do not have peripheral neuropathy, undergoing rIPC reduced infarct size compared to control dialysate. The cardioprotective effect of rIPC was reduced in diabetics with neuropathy. The studies indicate that brain circuits mediate release.[1]

Patient medication also affects rIPC. Sulphonylureas, used to treat type 2 diabetes, reduce preconditioning in experimental and clinical settings. Glibenclamide blocks ATP-sensitive potassium ion channels, preventing ischemia preconditioning benefits. However, medications such as insulin, metformin, GLP-1 analogues, gliptins (DPP-4 inhibitors that limit GLP-1 breakdown), and SGLT-2 inhibitors may protect the heart and enhance further benefits. Pharmacological therapies, such as β-blockers, ACE inhibitors, opioids, and anti-platelet drugs, may change the effect of rIPC by lowering the cardioprotection threshold. Further research is needed to determine whether pharmaceutical interactions affect rIPC cardioprotection.[1]

3. Conclusion

Remote ischemic preconditioning is a multifaceted approach aimed at enhancing the heart's ability to withstand ischemic conditions by inducing cytoprotective stimuli. There is an optimistic outlook for the potential implementation of this approach in many therapeutic situations, with the expectation that it will contribute to the mitigation of ischemia/reperfusion harm. Additional research endeavours should be meticulously planned in order to cultivate a more comprehensive comprehension of the pathways and mechanisms behind both early and late rIPC. Comprehending the routes is crucial for the successful translation of medical interventions to patients.

4. Declaration

4.1 Ethics Approval and Consent to participate
Not applicable.

4.2. Consent for publication
Not applicable.

4.3 Availibility of data and materials
Data used in our study were presented in the main text.

4.4 Competing interests
Not applicable.

4.5 Funding Source
Not applicable.

4.6 Authors contributions
Idea/concept: IMS. Design: IMS. Control/supervision: SA. Data collection/processing: IMS. Analysis/interpretation: IMS. Literature review: SA. Writing the article: IMS. Critical review: SA. All authors have critically reviewed and approved the final draft and are possible for the content and similarity index of the manuscript.

4.7 Acknowledgements
We thank to Brawijaya Cardiovascular Research Center

References

1. Donato M, Bin EP, D'Annunzio V, Gelpi RJ. Myocardial remote ischemic preconditioning: from cell biology to clinical application. *Mol Cell Biochem*. 2021;476(10):3857-3867. doi:10.1007/s11010-021-04192-4

2. Lau JK, Roy P, Javadzadegan A, et al. Remote Ischemic Preconditioning Acutely Improves Coronary Microcirculatory Function. *J Am Heart Assoc*. 2018;7(19). doi:10.1161/JAHA.118.009058

3. Stokfisz K, Ledakowicz-Polak A, Zagorski M, Zielinska M. Ischaemic preconditioning – Current knowledge and potential future applications after 30 years of experience. *Adv Med Sci*. 2017;62(2):307-316. doi:10.1016/j.advms.2016.11.006

4. Zhao Z-Z, Li E, Li X-J, Guo Q, Shi Q-B, Li M-W. Effects of remote ischemic preconditioning on coronary blood flow and microcirculation. *BMC Cardiovasc Disord*. 2023;23(1):404. doi:10.1186/s12872-023-03419-0

5. Donato M, Goyeneche MA, Garces M, et al. Myocardial triggers involved in activation of remote ischaemic preconditioning. *Exp Physiol*. 2016;101(6):708-716. doi:10.1113/EP085535

6. Johnsen J, Pryds K, Salman R, Løfgren B, Kristiansen SB, Bøtker HE. The remote ischemic preconditioning algorithm: effect of number of cycles, cycle duration and effector organ mass on efficacy of protection. *Basic Res Cardiol*. 2016;111(2):10. doi:10.1007/s00395-016-0529-6

7. Rosenberg JH, Werner JH, Moulton MJ, Agrawal DK. Current Modalities and Mechanisms Underlying Cardioprotection by Ischemic Conditioning. *J Cardiovasc Transl Res*. 2018;11(4):292-307. doi:10.1007/s12265-018-9813-1

8. Donato M, Bin EP, D´Annunzio V, Gelpi RJ. Myocardial remote ischemic preconditioning: from cell biology to clinical application. *Mol Cell Biochem*. 2021;476(10):3857-3867. doi:10.1007/s11010-021-04192-4

9. Dezfulian C, Taft M, Corey C, et al. Biochemical signaling by remote ischemic conditioning of the arm versus thigh: Is one raise of the cuff enough? *Redox Biol*. 2017;12:491-498. doi:10.1016/j.redox.2017.03.010

10. Hausenloy DJ, Kharbanda RK, Møller UK, et al. Effect of remote ischaemic conditioning on clinical outcomes in patients with acute myocardial infarction (CONDI-2/ERIC-PPCI): a single-blind randomised controlled trial. *Lancet*. 2019;394(10207):1415-1424. doi:10.1016/S0140-6736(19)32039-2

11. Youssuf ME, Yassin IAF, Sallam MM. Protective role of single versus multiple remote ischemic preconditioning in elective percutaneous coronary interventions. *Al-Azhar Int Med J*. 2023;4(2). doi:10.58675/2682-339X.1661

12. Wang X, Kong N, Zhou C, et al. Effect of Remote Ischemic Preconditioning on Perioperative Cardiac Events in Patients Undergoing Elective Percutaneous Coronary Intervention: A Meta-Analysis of 16 Randomized Trials. *Cardiol Res Pract*. 2017;2017:1-14. doi:10.1155/2017/6907167

13. Hauerslev M, Mørk SR, Pryds K, et al. Influence of long-term treatment with glyceryl trinitrate on remote ischemic conditioning. *Am J Physiol Circ Physiol*. 2018;315(1):H150-H158. doi:10.1152/ajpheart.00114.2018

14. José Alburquerque-Béjar J, Barba I, Valls-Lacalle L, et al. Remote ischemic conditioning provides humoural cross-species cardioprotection through glycine receptor activation. *Cardiovasc Res*. 2017;113(1):52-60. doi:10.1093/cvr/cvw242

15. Gong R, Wu Y-Q. Remote ischemic conditioning during primary percutaneous coronary intervention in patients with ST-segment elevation myocardial infarction: a systematic review and meta-analysis. *J Cardiothorac Surg*. 2019;14(1):14. doi:10.1186/s13019-019-0834-x

16. Hildebrandt HA, Kreienkamp V, Gent S, Kahlert P, Heusch G, Kleinbongard P. Kinetics and Signal Activation Properties of Circulating Factor(s) From Healthy Volunteers Undergoing Remote Ischemic Pre-Conditioning. *JACC Basic to Transl Sci*. 2016;1(1-2):3-13. doi:10.1016/j.jacbts.2016.01.007

17. Hausenloy DJ, Garcia-Dorado D, Bøtker HE, et al. Novel targets and future strategies for acute cardioprotection: Position Paper of the European Society of Cardiology Working Group on Cellular Biology of the Heart. *Cardiovasc Res*. 2017;113(6):564-585. doi:10.1093/cvr/cvx049

18. Gaspar A, Lourenço AP, Pereira MÁ, et al. Randomized controlled trial of remote ischaemic conditioning in ST-elevation myocardial infarction as adjuvant to primary angioplasty (RIC-STEMI). *Basic Res Cardiol*. 2018;113(3):14. doi:10.1007/s00395-018-0672-3

19. Lieder HR, Irmert A, Kamler M, Heusch G, Kleinbongard P. Sex is no determinant of cardioprotection by ischemic preconditioning in rats, but ischemic/reperfused tissue mass is for remote ischemic preconditioning. *Physiol Rep*. 2019;7(12). doi:10.14814/phy2.14146

20. Pearce L, Davidson SM, Yellon DM. Does remote ischaemic conditioning reduce inflammation? A focus on innate immunity and cytokine response. *Basic Res Cardiol*. 2021;116(1):12. doi:10.1007/s00395-021-00852-0

21. Kingma JG, Simard D, Rouleau JR. Influence of cardiac nerve status on cardiovascular regulation and cardioprotection. *World J Cardiol*. 2017;9(6):508. doi:10.4330/wjc.v9.i6.508

22. Billah M, Ridiandries A, Rayner BS, et al. Egr-1 functions as a master switch regulator of remote ischemic preconditioning-induced cardioprotection. *Basic Res Cardiol*. 2020;115(1):3. doi:10.1007/s00395-019-0763-9

23. Xia Z, Herijgers P, Nishida T, Ozaki S, Wouters P, Flameng W. Remote preconditioning lessens the deterioration of pulmonary function after repeated coronary artery occlusion and reperfusion in sheep. *Can J Anesth Can d'anesthésie*. 2003;50(5):481-488. doi:10.1007/BF03021061

24. Heusch G, Rassaf T. Time to Give Up on Cardioprotection? *Circ Res*. 2016;119(5):676-695. doi:10.1161/CIRCRESAHA.116.308736

25. Basalay M V., Davidson SM, Gourine A V., Yellon DM. Neural mechanisms in remote ischaemic conditioning in the heart and brain: mechanistic and translational aspects. *Basic Res Cardiol*. 2018;113(4):25. doi:10.1007/s00395-018-0684-z

26. Hausenloy DJ, Ntsekhe M, Yellon DM. A future for remote ischaemic conditioning in high-risk patients. *Basic Res Cardiol*. 2020;115(3):35. doi:10.1007/s00395-020-0794-2

Contents list available at www.heartscience.ub.ac.id

Heart Science Journal

Journal Homepage : www.heartscience.ub.ac.id

Review Article

Sudden Cardiac Death in Young Age, What Should We Know?

Icmi Dian Rochmawati[1*], Ardian Rizal[2], Valerinna Yogibuana Swastika Putri[2], Indra Prasetya[2]

[1]Brawijaya Cardiovascular Research Center, Department of Cardiology and Vascular Medicine, Faculty of Medicine, Universitas Brawijaya, Malang, Indonesia.
[2]Department of Cardiology and Vascular Medicine, Faculty of Medicine, Universitas Brawijaya, Malang, Indonesia.

ARTICLE INFO

Keyword :
Young;
Sudden Cardiac Death;
Preventive.

ABSTRACT

While young sudden cardiac death (SCD) is statistically uncommon, its dramatic presentation and impact on families and communities make it a newsworthy issue. Nonetheless, it is important to view SCD in children and adolescents as a public health concern and devise strategies based on research and consensus to address it. Both individuals with and without a history of cardiovascular illness are susceptible to sudden cardiac death. Employing cardiovascular disease risk screening for healthy individuals and those with a family history of sudden cardiac death can serve as a preventive approach against sudden cardiac death. Assessing the severity of cardiovascular disease in people becomes essential to prevent disease progression and minimize the risk of mortality from cardiovascular conditions.

1. Introduction

Each year, cardiovascular disease is responsible for 17 million deaths, and sudden cardiac deaths contribute to 25% of these fatalities. Males have a higher probability of experiencing abrupt deaths in comparison to females. Sudden cardiac death (SCD) is defined as a death that happens within one hour of the onset of symptoms or within 24 hours after last being seen in good health if the death is not witnessed. SCD can be triggered by various cardiovascular factors; while coronary heart disease is often associated with older age, arrhythmias display a sudden pattern and can affect individuals of different age groups.[1]

Although relatively rare in statistics, sudden cardiac death (SCD) among young individuals is noteworthy because of its dramatic presentation and the profound effect it has on families and communities. The media's extensive coverage of SCD cases in athletes brings attention to the idea that seemingly fit and healthy young people may still possess hidden vulnerabilities. However, it is important to prevent SCD in children and adolescents as an important issue and take steps to address it through evidence-based approaches, research, and consensus-building efforts.[2]

2. Discussion

Epidemiology

SCD is a serious problem in modern cardiology since it affects many of individuals (about 400,000 in the United States alone) and has severe socioeconomic consequences. [3]

There is scant data on the occurrence of sudden cardiac death (SCD) in South East Asia, particularly in community-based settings. A Singapore study found that the incidence of SCD is 20.9 per 100,000 persons. Wong et al. contend that there is also a lack of awareness of incidence data from other South East Asian countries such as Malaysia and Indonesia. [5]

Identification of Young Patient Risk of SCD

SCDs occur in people who already have cardiac problems, and may cause or hasten the sudden worsening of illnesses

Familial propensity

Familial propensity may impact SCD and catastrophic ventricular arrhythmias. Certain kinds of cardiomyopathy are passed down via families as autosomal dominant genetic illnesses. [6]

Dietary structure

The incidence of SCD is linked to dietary content. Consuming a reasonable quantity of deep-sea fish may raise omega-3 fatty acid levels helps control cholesterol levels and reduces the risk of myocardial infarction. Inadequate magnesium ions may cause coronary artery spasms and arrhythmias, while enough magnesium consumption has antiarrhythmic effects and lessens the risk of SCD. Magnesium supplementation has been associated with a lower incidence of SCD. [6]

* Corresponding author at: Brawijaya Cardiovascular Research Center, Department of Cardiology and Vascular Medicine, Faculty of Medicine, Universitas Brawijaya, Malang, Indonesia.
E-mail address: icmidianr@hotmail.com (I.D. Rochmawati).

https://doi.org/10.21776/ub/hsj.2024.005.02.7
Received 10 August 2023; Received in revised form 21 August 2023; Accepted 4 September 2023.
Available online 28 April 2024

Table 1. Population-Based Estimates of SCD Incidence in the Young

Study	Patient Group	Age Range, y	SCD Incidence (per 100 000 Patient-Years)	Comments
Molander et al[22]	All unexpected deaths, southern Sweden	1–20	0.7	≈15% SCD
Driscoll et al[23]	Death certificate survey, Olmsted County, Minnesota	1–22	1.3	>50% sudden death cardiac related
Gerein et al[24]	Cardiopulmonary arrest patients, Ontario, Canada	<17	1.5 (9.1 all arrests)	16% deemed attributable to cardiac causes
Puranik et al[25]	Forensic office review of sudden death, Eastern Sydney, Australia	5–35	1.0	29% autopsy negative
Chugh et al[26]	Sudden death survey, Multnomah County, Oregon	1–17	1.7	Same study included infants, accounting for 76% of all events
Park et al[27]	Out-of-hospital cardiac arrest, Korea	<19	4.2	Includes ≈25% infants, ≈30% deemed cardiac
Papadakis et al[28]	Sudden deaths, England and Wales	1–34	1.8	14% classified as SCD
Hendrix et al[29]	Death certificate survey, 12 Dutch provinces	1–40	1.6	Increased rate in patients >30 y
Winkel et al[30]	Sudden deaths, Denmark	1–35	1.9–2.8	Dependent on assignment of nonautopsy cases
Margey et al[31]	Sudden death statistics, Republic of Ireland	15–35	2.9	Sudden unexplained death 27%, hypertrophic cardiomyopathy 15%
Wren et al[32]	All deaths, 1 English health region	1–20	2.5	Half of SCD associated with prior known diagnosis
Winkel et al[33]	All deaths, Denmark	1–18	1.5	No prior medical history in two-thirds of cases
Bardai et al[34]	Out-of-hospital, province in the Netherlands	<21	3.2 (9.0 all arrests)	39% cardiac etiology
Meyer et al[35]	Out-of-hospital, King County, Washington	<35	2.3	In patients >25 y, coronary artery disease primary cause
Atkins et al[36]	Out-of-hospital, multiple US districts	1–11	3.73	Resuscitation Outcomes Consortium
Atkins et al[36]	Out-of-hospital, multiple US districts	12–18	6.4	Resuscitation Outcomes Consortium
Kitamura et al[37]	Out-of-hospital, Japan	<12	2.4 (female) 3.3 (male)	Nationwide registry of OHCA
Daya et al[38]	Out-of-hospital, USA	<18	10.1	Includes infant sudden death

OHCA indicates out-of-hospital arrest; and SCD, sudden cardiac death.

Figure 1. Incidence of Sudden Cardiac Death in the Young[2]

Atrial fibrillation, obstructive sleep apnea syndrome and Chronic renal disease

In people with atrial fibrillation, the prevalence of fatal embolisms has greatly decreased because to oral anticoagulants, although SCD is still not prevented by them. Chronic renal disease patients are more likely to develop SCD. Upper airway collapse, which causes apnea and hypoxemia, characterizes the recurring and intermittent respiratory disorder known as obstructive sleep apnea syndrome. By itself, this condition increases the risk of SCD.[6]

Obesity

Obesity increases the likelihood of hypertension, hyperlipidemia, and hyperglycemia, which are distinct coronary heart disease risk factors and may enhance susceptibility to SCD.[6]

Mental factors

Numerous research has demonstrated a link between SCD incidence and depression, anxiety, and high levels of psychological stress.[6]

Overworked

Excessive and rigorous exercise may cause the sympathetic and parasympathetic nervous systems to malfunction, leading to electrolyte imbalances and hypoglycemia, which can trigger SCD.[6]

Bad living habits

Prolonged sleep deprivation disrupts sympathetic and parasympathetic nerve activity, possibly producing premature heartbeats and arrhythmias, and eventually SCD. Tobacco and alcohol use are at increased risk of coronary heart disease, promoting its beginning. Stress and polluted air exposure may cause coronary heart disease, and a variety of other disorders, increasing the risk of SCD owing to arrhythmias and spasms coronary artery.[6]

Risk Stratification

Clinical risk stratification, including the risk of SCD, is a key part of good healthcare management. Given that coronary artery disease (CAD) and heart failure (HF) are key underlying causes in the majority of SCD patients, CAD and HF risk variables serve as predictors of SCD-related fatalities and overall mortality. These risk factors, which include increasing age, male gender, cigarette smoking, hypertension, obesity, high cholesterol levels, diabetes mellitus, and family history, are included in risk assessment systems such as the Framingham Risk Score in the United States and the HeartScore in Europe.[7]

In addition to the above mentioned criteria, clinical labs may identify other risk factors for SCD. Left ventricular (LV) dysfunction, a history of heart failure (HF), left ventricular hypertrophy, poor heart functional status, an increased heart rate, and abnormal electrocardiogram (ECG) readings are examples of these. The quantity of blood pumped out of the left ventricle is measured as the LV ejection fraction (LVEF), which may be assessed via echocardiography, magnetic resonance imaging (MRI), or nuclear medicine scans. The ECG examines the heart rate, rhythm, size, and location of the heart chambers, as well as any cardiac muscle damage or conduction system anomalies. Prolonged QT intervals, Tpeak-Tend intervals, and T-wave alternans have all been recommended as risk indicators.[7]

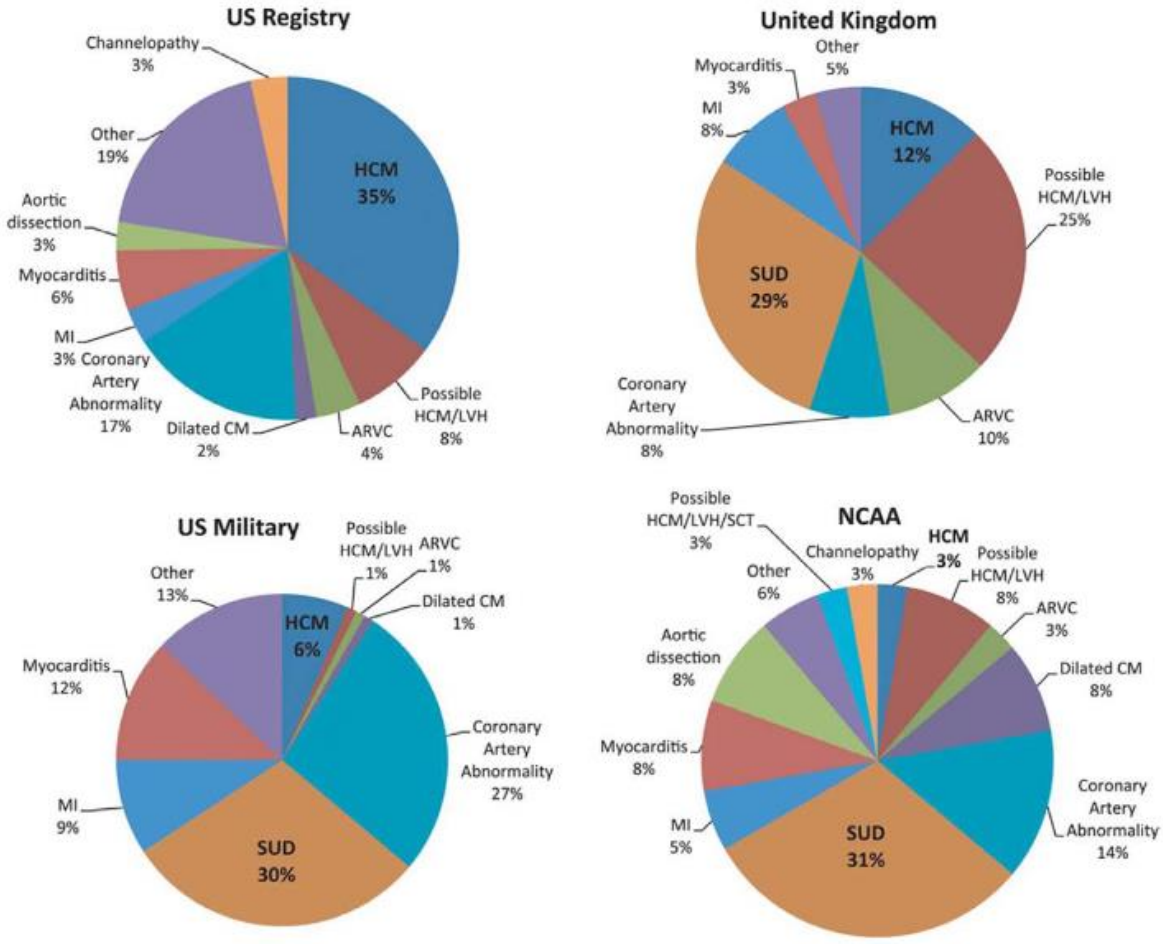

Figure 2. Etiology of Sudden Cardiac Death[4]
ARVC arrhythmogenic cardiomyopathy; CM Cardiomyopathy; HCM hypertrophic cardiomyopathy; LVH left ventricular hypertrophy; MI myocardial infarction;NCAA National Collegiate Athletic Association; SCT sickle cell trait; SUD sudden unexplained death.

Etiology

Inheritable and Acquired Channelopathy and Cardiomyopathy

Channelopathy

Cardiac ion channelopathies are the leading suspects in cases where a negative autopsy is associated with Individuals under the age of 35 account for 40% of all sudden unexpected natural deaths. The majority of instances include Long QT syndrome (LQTS), catecholaminergic polymorphic ventricular tachycardia (CPVT) and Brugada syndrome (BrS).[8]

Every ion channelopathy exhibits a distinctive electrocardiogram (ECG) pattern and characteristic presentation. These conditions are frequently misidentified as seizure disorders. The simultaneous occurrence of these channelopathies may increase the likelihood of arrhythmic death during myocardial infarction, metabolic disturbances, or when multiple medications are administered. The emergence of cardiac events triggered by fever should raise suspicion for Brugada syndrome (BrS).[8]

The Cardiac Action Potential and Cellular Excitability

A precise sequence of depolarizing and repolarizing ion currents enabled by ion channels, which form the cellular action potential, regulates the cardiac cycle. Changes in these disturb the timing and shape of the action potential, exposing the heart to arrhythmias. Moreover, the excitability of cardiac cells is greatly influenced by the concentration of intracellular free calcium. Excessive calcium levels can lead to premature spontaneous depolarization, as observed in cases of digoxin toxicity and catecholaminergic polymorphic ventricular tachycardia (CPVT).[8]

Dysfunctional ion channels

Ion channelopathies are caused by genetic abnormalities in the genes that encode ion channels or related proteins, resulting in changes in their properties. These mutations may cause a channel to become inactive, hypoactive, hyperactive, or permeable. These mutations, for example, impact the cardiac sodium channel Nav1.5 and its encoding gene SCN5A. Long QT syndrome type 3 (LQT3) is caused by the channel failing to shut correctly, while Brugada syndrome is caused by insufficient opening or defective expression of the channel. Surprisingly, the same mutation may cause either illness within the same family.[8]

Long QT Syndrome

Long QT syndrome (LQTS) is ion channelopathy that is hereditary or genetic. The term "acquired long QT syndrome" refers to cases in which the QT interval is prolonged as a result of acquired heart disease, biochemical abnormalities, or pathophysiological events such as hypokalemia, the use of medications that prolong the QT interval, hypothermia, or neurological events such as a stroke.[8]

Long QT syndrome is caused by a genetic mutation in one of the 17 LQTS genes. The inheritance pattern is often autosomal dominant, and the condition was formerly known as Romano-Ward syndrome. LQT1, LQT2, LQT3, and LQT5 are the most often seen genotypes. Genotype analysis may be useful in verifying a diagnosis, simplifying genetic screening of possibly afflicted family members, assessing risk, and tailoring suitable medication.[8]

Brugada Syndrome

Brugada syndrome is diagnosed when a distinct electrocardiogram (ECG) pattern is observed in a structurally normal heart, and its occurrence is more common in South Asian countries. This ECG pattern is associated with a heightened risk of potentially life-threatening arrhythmias, which often manifest during vagal triggers such as post-meal periods and nighttime, as well as during episodes of fever. The risk of arrhythmias is particularly elevated during the fourth and fifth decades of life, and men are more susceptible than females.[8]

The underlying pathophysiology of the ECG features and the arrhythmogenic substrate of Brugada syndrome remains debatable. However, mounting evidence suggests that minor structural abnormalities in the right ventricular outflow tract (RVOT) region play a role in the development of this condition. Consequently, Brugada syndrome may be considered as part of the spectrum of arrhythmogenic right ventricular cardiomyopathy (ARVC).[8]

Currently, molecular genetic testing is primarily recommended for the SCN5A gene, particularly in families with known SCN5A mutations (presymptomatic cases). Genetic counseling should also include an electrocardiogram (ECG) assessment, as there have been reported cases of individuals within these families who exhibit a positive phenotype but lack the identified genotype. Genetic testing may have a limited role in risk stratification.[8]

CPVT (Catecholaminergic Polymorphic Ventricular Tachycardia)

The typical manifestation of this condition is observed in children aged 4 to 12 years, who experience sudden fainting or cardiac arrest during exercise, often associated with activities like swimming. These symptoms tend to be more severe in males. The resting 12-lead electrocardiogram (ECG) appears normal. The diagnosis is established through exercise testing, after ruling out structural heart disease entails recording premature ventricular contractions, which frequently occur at heart rates of more than 100 beats per minute during exercise and may proceed to polymorphic ventricular tachycardia. The distinctive "bidirectional ventricular tachycardia" that is highly suggestive of CPVT may also be found in certain situations.[8]

Cardiomyopathy

The risk of sudden death (SD) in cardiomyopathies is principally addressed by hypertrophic cardiomyopathy (HCM) and arrhythmogenic cardiomyopathy (ACM). While SD may develop in other kinds of cardiomyopathies, such as dilated and restrictive cardiomyopathy, these disorders seldom cause exertional restrictions owing to heart failure symptoms. Furthermore, they are uncommon causes of sudden mortality in young people and sportsmen.[9]

Hypertrophic Cardiomyopathy (HCM)

HCM is the most common main heart muscle disorder caused by hereditary causes, affecting 0.2-0.5 percent of the general population. It differs significantly in how it appears, its underlying processes, and its clinical development. The condition has an autosomal dominant inheritance pattern, and the genetic foundation is identified in mutations in genes responsible for sarcomeric proteins. A disease-causing mutation may be detected in roughly 35-45 percent of afflicted patients, and this rate jumps to approximately 65 percent when there is a positive family history of HCM. However, because to the wide range of genetic variants and clinical manifestations, the link between particular sarcomere mutations and clinical outcomes in HCM patients has proved untrustworthy.[9]

Arrhythmogenic Cardiomyopathy (ACM)

ACM is a rare hereditary cardiac condition that damages the myocardium. Its general population prevalence is estimated to be between 0.01 and 0.05 percent. This cardiomyopathy has a particular penetrance and expression pattern that is affected by age and gender. Sudden death (SD) is more common in men throughout youth or early adulthood, and it may even be the first symptom of the illness.[9]

While most ACM mutations are discovered in genes that encode desmosomal proteins, mutations may also arise in genes that are only partly connected to junctional complexes. Positive findings from genetic screening might be found in up to 50% of family cases. However, knowledge of genotype-phenotype connections in ACM remains inadequate. A person might have numerous mutations with variable prognostic importance, which has significant consequences for genetic counseling. [9]

Structural Congenital Heart Disease

The sudden cardiac death (SCD) in this group is increased due to additional risk factors such as scarring, hypertrophy, and fibrosis. SCD accounts for 15 to 25% of mortality in individuals with congenital heart dysfunction.[7]

Individuals who are at risk of ventricular fibrillation due to conditions such as tetralogy of Fallot, extended QRS length, palliative shunt, or ventricular dysfunction may consider the use of an implanted cardioverter defibrillator (ICD) as it has been proven effective in preventing sudden cardiac death. For patients with continuous, gradual ventricular tachycardia and a single affected area, catheter ablation is considered the most suitable treatment. As congenital heart disease continues to be a concern for human health, further research is necessary to improve diagnostic and treatment techniques, aiming to reduce the heightened risk of sudden death associated with this condition.[7]

Sudden Cardiac Death in Athletes

The occurrence of sudden cardiac death in a seemingly healthy athlete is a tragic occurrence that contradicts the normal relationship between sports involvement and excellent physical health. Several groups have called for pre-participation assessments to discover or raise concerns about cardiovascular anomalies that could result in sudden cardiac death during sports (PPE). However, the particular components of an ideal PPE continue to be the topic of extensive debate, as they differ across nations, leagues, and levels of competition.[4]

Most recommendations state that the history, physical examination, and electrocardiogram (ECG) are low-cost pre-participation screening procedures that should be used as the primary screening tools. For young competitive athletes, the American Heart Association (AHA) now advises certain history and physical examination components. Before participating in competitive high school or college sports, the athlete's personal or family physician should perform these assessments. These athletes should be sent to cardiologists and subjected to baseline and periodic echocardiographic and electrocardiographic testing. Additional imaging and electrophysiological studies may be considered at the cardiologist's discretion.[10]

The use of ECG in athlete screening becomes increasingly challenging due to the frequency of aberrant ECG abnormalities that may emerge due to athletic training, even in the absence of underlying cardiac disease. These "abnormal" ECG patterns are caused by athletic conditioning-related factors such as increased vagal tone, muscular mass, and a bigger heart size. These tendencies are influenced by age, gender, race, ethnicity, and, most crucially, the kind and length of the activity. Endurance athletes who engage in sports such as long-distance running are particularly sensitive to ECG symptoms related to their training. [10]

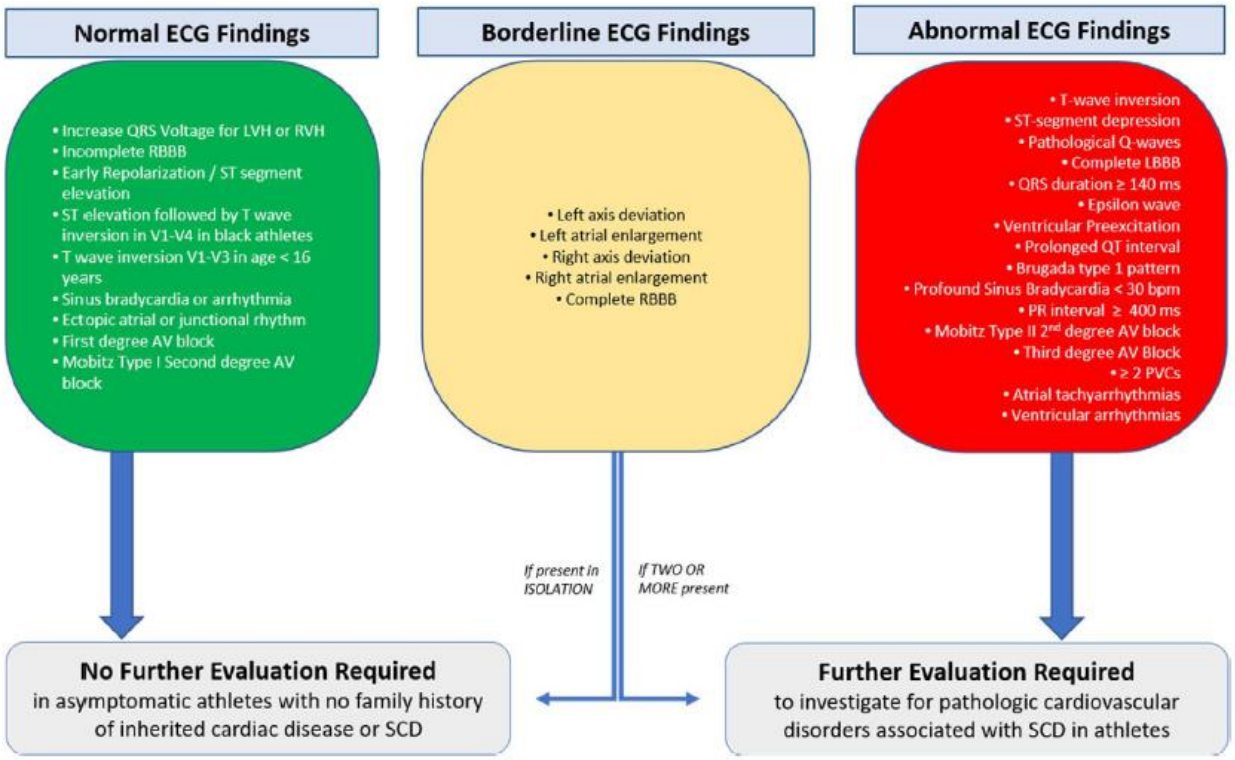

Figure 3. Classification of ECG Findings Based on The International Consensus Standards for ECG Interpretation in Athletes[10]
SCD sudden Cardiac Death; ECG electrocardiogram;LVH Left Ventricular Hypertrophy; RVH Right Ventricular Hypertrophy; RBBB Right Bundle Branch Block; LBBB Left Bundle Branch Block; AV Atrio Ventricular; PVC Premature Ventricular Contraction

Sudden Cardiac Death Associated with Medication

Several medicines have the potential to cause arrhythmias by changing the ion channels of cardiomyocytes, hence disrupting the electrical activity of the heart. These pharmaceuticals include antiarrhythmic medications, diuretics, antibiotics, and narcotics like cocaine.[6]

Cocaine is known for its sympathomimetic effects, leading to increased heart contractions, elevated heart rate, and high blood pressure. Abusing high amounts of cocaine can lead to cardiac tachycardia/fibrillation, acute myocardial infarction, or cerebral hemorrhage, all of which have the potential to cause sudden death. To minimize the occurrence of adverse events, healthcare providers should routinely monitor electrolyte levels, changes in electrocardiograms, and renal function.[6]

Primary and Secondary Prevention of Sudden Cardiac Death

a. Surgery Prevention

The implanted cardioverter-defibrillator (ICD) is the most advanced and effective method for managing and preventing sudden cardiac death (SCD). It can quickly identify ventricular arrhythmias and promptly administer defibrillation, potentially saving patients' lives. ICDs are more effective than antiarrhythmic medications in reducing the occurrence of severe ventricular arrhythmias and the risk of sudden cardiac death (SCD). The ICD's ability to prevent sudden cardiac death in patients with persistent ventricular tachycardia significantly enhances their prognosis and increases overall patient survival rates.[1,10]

It effectively prevents SCD, while the effectiveness of medication therapy remains uncertain for individuals with a history of cardiac arrest and syncope, making ICDs the preferred option. For arrhythmogenic right ventricular cardiomyopathy patients with a history of persistent ventricular tachycardia and syncope, ICD implantation can prevent sudden cardiac death. Additionally, in cases where decompensated heart failure causes malignant ventricular arrhythmias in patients with grade IV cardiac dysfunction, ICDs can prevent SCD and reduce mortality.[6]

b. Drug

While the ICD remains the most effective approach to prevent and treat sudden cardiac death (SCD), achieving widespread acceptance in China might present challenges due to the country's unique characteristics. Therefore, it is vital to prioritize pharmacological SCD prevention. Pharmacological therapies play a crucial role in reducing SCD caused by malignant arrhythmias.[6]

1. Beta-blockers

These medications work by lowering heart rate, regulating blood pressure, and prolonging diastole, potentially leading to decreased myocardial oxygen consumption in patients with coronary heart disease.[6]

2. Amiodarone

Amiodarone falls under the category of type III antiarrhythmic medications, and it acts to correct heart rhythm irregularities. This is accomplished by prolonging the effective refractory period of cardiac cells, effectively removing triggers for reentry. Additionally, amiodarone blocks the entry of fast sodium ions into cardiac conducting fibers, which results in reduced conduction velocity and decreased autonomy of the sinoatrial node.[6]

3. Angiotensin-converting enzyme inhibitors

It may reverse the remodeling of the left ventricle, raise vagal tone, and decrease adrenergic transmission-related angiotensin II levels. [6]

4. Aldosterone receptor antagonist

Aldosterone affects myocardial interstitial fibrosis and myocardial cell hypertrophy. Blocking the aldosterone receptor can prevent myocardial remodeling and potentially increase heart rate variability. Spironolactone demonstrated a significant reduction in the incidence of sudden cardiac death (SCD) in individuals with a left ventricular ejection fraction (LVEF) below 40 percent.[11]

5. Statins

Statins can potentially reduce the likelihood of ventricular tachycardia and ventricular fibrillation, resulting in a decreased occurrence of sudden cardiac death (SCD). Furthermore, for patients with non-ischemic cardiomyopathy requiring implanted cardioverter-defibrillator (ICD) treatment, statins may aid in reducing the frequency of arrhythmias and overall mortality.[4]

Research has demonstrated the effectiveness of statins in both preventing and treating coronary heart disease and stroke. For individuals with coronary heart disease and concurrent ventricular arrhythmias, statins can decrease the probability of ventricular tachycardia and ventricular fibrillation, leading to a reduced risk of sudden cardiac death (SCD).[10]

SCD Prevention

a. Prediction of SCD

The primary focus of preventing sudden cardiac death (SCD) should be directed towards high-risk populations, including individuals with coronary artery disease, cardiomyopathy, cardiac electrophysiology abnormalities, and valvular heart disease. Initiatives are in place to assist patients in addressing underlying causes, managing risk factors, monitoring high-risk individuals for changes in their condition, and ultimately reducing the occurrence of SCD.

b. The Early Warning Indicators of SCD

1. ECG, Holter, and ECG exercise test

ECG and Holter monitoring can aid in predicting likelihood of sudden cardiac death (SCD) by identifying slow or fast arrhythmias and myocardial ischemia. In cases where individuals experience angina pectoris during physical exertion and have a normal resting ECG, the ECG exercise test can help determine angina during activity is caused by myocardial ischemia occurring during physical exertion.[6]

2. Ultrasonic testing bedside ultrasound

Echocardiography is vital in verifying the existence of structural heart ailments and identifying the underlying reason for Sudden Cardiac Death (SCD). LVEF is a crucial metric that gauges the efficiency of the left ventricle's pumping action and is widely used as an indicator of its systolic function.[6]

SCD leads to the demise of 30 to 50 percent of individuals suffering from heart failure. Around 25% of those diagnosed with symptomatic heart failure encounter SCD within 2.5 years of diagnosis. Among cardiac arrest patients, nearly 45% exhibit an LVEF (left ventricular ejection fraction) below 30%. When dealing with ischemic or nonischemic cardiomyopathy, an LVEF of 35 percent or lower is linked to a higher risk of sudden cardiac death (SCD), necessitating additional assessment for potential ICD (implantable cardioverter-defibrillator) treatment. [6]

Bedside ultrasonography enables rapid identification of severe hypovolemia, tension pneumothorax, pericardial tamponade, pulmonary embolism, and myocardial infarction. A substantial embolus in the pulmonary trunk, left, and right branches confirms the diagnosis of a pulmonary embolism.[6]

3. Brain natriuretic peptide

SCD, as an indicator of cardiovascular disease risk, is associated with elevated levels of brain natriuretic peptides. Besides patients diagnosed with heart failure and coronary artery disease, brain natriuretic peptides can also serve as predictors for SCD in otherwise healthy individuals who might be susceptible to such events.[6]

4. Stiffness of the aorta and limb blood pressure examination

An efficient way to identify atherosclerosis early on is to measure the aorta's flexibility, limb-synchronous blood pressure, and blood flow.[6]

5. Coronary CT and coronary angiography

The risk posed by ischemic heart disease to human health is substantial. Sudden Cardiac Death (SCD) is predominantly triggered by malignant arrhythmia, of the myocardial scar and cardiac dysfunction resulting from ischemic heart disease. An essential step in preventing SCD is the proactive diagnosis of ischemic heart disease.[6]

6. Ventricular late potential (VLP)

Ventricular Late Potentials (VLP) are characterized by high-frequency, low-amplitude fragmentation potentials occurring toward the end of the QRS wave. They indicate delayed conduction and non-synchronous depolarization in the ventricular myocardium. VLP has proven highly sensitive and specific in predicting myocardial infarction accompanied by malignant arrhythmia. In individuals with cardiac disease, the combination of Left Ventricular Ejection Fraction (LVEF) and VLP is an independent predictor of ventricular arrhythmia, significantly improving the accuracy of predicting arrhythmia events.[6]

3. Conclusion

Both individuals with and without a history of cardiovascular disease are susceptible to sudden cardiac death. To prevent sudden cardiac death proactively, it is recommended to conduct screenings for cardiovascular disease risk in both healthy individuals and those with a family history of sudden cardiac death. Assessing the severity of cardiovascular disease in individuals becomes crucial for disease management and reducing the mortality risk associated with cardiovascular conditions.

4. Declaration

4.1 Ethics Approval and Consent to participate
Not applicable.

4.2. Consent for publication
Not applicable.

4.3 Availibility of data and materials
Data used in our study were presented in the main text.

4.4 Competing interests
Not applicable.

4.5 Funding Source
Not applicable.

4.6 Authors contributions
Idea/concept: IDR. Design: IDR. Control/supervision: AR, VY, IP. Data collection/processing: IDR. Analysis/interpretation: IDR, AR, VY, IP. Literature review: IDR, AR, VY, IP. Writing the article: IDR. Critical review: AR, VY, IP. All authors have critically reviewed and approved the final draft and are possible for the content and similarity index of the manuscript.

4.7 Acknowledgements
We thank to Brawijaya Cardiovascular Research Center.

References

1. Chandra E, Suwanto D. Deteksi Dini untuk Mencegah Kematian Mendadak Akibat Aritmia. *Cermin Dunia Kedokt*. 2021;48(6):303. doi:10.55175/cdk.v48i6.1429

2. Corianò M, Tona F. Strategies for Sudden Cardiac Death Prevention. *Biomedicines*. 2022;10(3). doi:10.3390/biomedicines10030639

3. Bayés de Luna A, Massó van-Roessel A, Escobar-Robledo LA, Arimany-Manso J. Actualización de la muerte súbita cardiaca: epidemiología y estratificación del riesgo. *Rev Esp Med Leg*. 2018;44(1):5-12. doi:10.1016/j.reml.2017.10.002

4. Emery MS, Kovacs RJ. Sudden Cardiac Death in Athletes. *JACC Hear Fail*. 2018;6(1):30-40. doi:10.1016/j.jchf.2017.07.014

5. Wong CX, Brown A, Lau DH, et al. Epidemiology of Sudden Cardiac Death: Global and Regional Perspectives. *Hear Lung Circ*. 2019;28(1):6-14. doi:10.1016/j.hlc.2018.08.026

6. Plumlee KH. *Sudden Death*. (Zhu H, ed.). Springer Nature Singapore Pte Ltd. 2021; 2003. doi:10.1016/B0-32-301125-X/50019-4

7. Osman J, Tan SC, Lee PY, Low TY, Jamal R. Sudden Cardiac Death (SCD) - Risk stratification and prediction with molecular biomarkers. *J Biomed Sci*. 2019;26(1):1-12. doi:10.1186/s12929-019-0535-8

8. Skinner JR, Winbo A, Abrams D, Vohra J, Wilde AA. Channelopathies That Lead to Sudden Cardiac Death: Clinical and Genetic Aspects. *Hear Lung Circ*. 2019;28(1):22-30. doi:10.1016/j.hlc.2018.09.007

9. Rizzo S, Carturan E, De Gaspari M, Pilichou K, Thiene G, Basso C. Update on cardiomyopathies and sudden cardiac death. *Forensic Sci Res*. 2019;4(3):202-210. doi:10.1080/20961790.2019.1631957

10. Vora A, Burkule N, Contractor A, Bhargava K. Prevention of sudden cardiac death in athletes, sportspersons and marathoners in India. *Indian Heart J*. 2018;70(1):137-145. doi:10.1016/j.ihj.2017.12.004

11. Kirchhof P, Breithardt G, Eckardt L. Primary prevention of sudden cardiac death. *Heart*. 2006;92(12):1873-1878. doi:10.1136/hrt.2006.087957

Heart Sci J 2024; 5(2): 44-50

Contents list available at www.heartscience.ub.ac.id

Heart Science Journal

Journal Homepage : www.heartscience.ub.ac.id

Original Article

Impact of Strict and Lenient Heart Rate Control on Six-Minute Walk Test and Quality of Life in Atrial Fibrillation Patients with Rheumatic Mitral Stenosis: A Preliminary Study

Nur Kaputrin Dwigustiningrum[1*], Ardian Rizal[2], Valerinna Yogibuana Swastika Putri[2], Anna Fuji Rahimah[3], Mohammad Saifur Rohman[2], Adhika Prastya Wikananda[2], Yoga Waranugraha[2], Tri Astiawati[3], Fitranti Suciati Laitupa[3]

[1]Brawijaya Cardiovascular Research Center, Department of Cardiology and Vascular Medicine, Faculty of Medicine, Universitas Brawijaya, Malang, Indonesia.
[2]Department of Cardiology and Vascular Medicine, Faculty of Medicine, Universitas Brawijaya, Malang, Indonesia.
[3]Department of Cardiology and Vascular Medicine, Iskak General Hospital, Tulung Agung, Indonesia

ARTICLE INFO

Keyword :
Strict and lenient heart rate;
HRQoL;
Six-Minute Walk Test;
Atrial Fibrillation;
Rheumatic Mitral Stenosis.

ABSTRACT

Background: Recent studies showed no outcome difference between strict and lenient rate control in the general Atrial Fibrillation (AF) population. However, for AF and Rheumatic Mitral Stenosis (RMS) patients, evidences were lacking.
Objective: To assess the impact of strict and lenient heart rate control on the Six-Minute Walk Test (SMWT) and Health Related Quality of Life (HRQoL) in patients with AF and RMS.
Material and Methods: A prospective multicenter trial across tertiary hospitals in East Java assessed strict and lenient heart rate control's impact on the SMWT and HRQoL in AF and RMS patients. Sixty-one participants were randomized into strict and lenient groups over six months from March to August 2023. Medications were adjusted to achieve target heart rates, and HRQoL was assessed using SF-36 and SMWT at baseline and three months post-target heart rate attainment.
Result: In our study, 29 patients were under strict heart rate control, and 32 were under lenient control. We found a decrease in HRQoL across all subscales, with significant differences observed in general health perception and physical function among those under strict control (p=0.002 and 0.03, respectively). However, no significant disparity was found in the SMWT distance difference between lenient and strict groups (p=0.529), nor in METs (p=0.326).
Conclusion: In the study, lenient heart rate control demonstrates significant effects on the general health perception and physical function subscales compared to strict heart rate control.

1. Introduction

Indonesia stands as an endemic region for Rheumatic Heart Disease (RHD), with a remarkable 1.18 million cases documented in 2015, positioning it as the fourth most impacted nation worldwide, following China, India, and Pakistan.[1] Among individuals diagnosed with Mitral Stenosis (MS) originating from RHD, the prevalence of atrial arrhythmias, notably atrial fibrillation (AF), is notably high, affecting approximately 30-40% of individuals.[2] The trajectory of Rheumatic Mitral Stenosis (RMS) often begins with AF after periods of asymptomaticity, with the risk of AF escalating with advancing age.[3] AF, impacting 2-4% of the population, demonstrates a 2-3-fold increase in incidence with age progression.[4] Moreover, AF poses significant health risks, elevating the likelihood of stroke, heart failure, and mortality, particularly among women. Notably, AF patients face a twofold higher mortality rate compared to those in sinus rhythm.[4,5] The presence of AF in RMS patients significantly correlates with a dismal prognosis, marked by heightened risks of thromboembolism, heart failure, and premature mortality, persisting even post-valve intervention.[3]

The medical management of AF in the context of RMS revolves around two key pillars: anticoagulation to mitigate thromboembolic risks and heart rate control to ameliorate symptoms.[6] Heart rate regulation commonly involves the use of β-blocker medications and digitalis as atrioventricular node inhibitors to modulate heart rate in AF patients within the general population.[7] Findings from the Atrial Fibrillation Follow-up Investigation of Rhythm Management (AFFIRM) trials underscored the superior efficacy of β-blockers over calcium channel blockers in heart rate control, with β-blockers demonstrating a higher rate of effectiveness (70% *vs.* 54%), whether administered either independently or alongside digitalis. However, the Rate Control Efficacy in Permanent Atrial Fibrillation: a Comparison between Lenient versus Strict Rate Control II (RACE II) study revealed no discernible disparity between lenient and strict heart rate control strategies in general AF management.[8] However, the optimal approach for modulating heart rate, determining the intensity of heart rate reduction, and defining the ideal heart rate target for AF patients with RMS remains elusive. Notably, there are currently no established guidelines delineating target heart rates specifically tailored to this patient cohort.[7] This study sought to

* Corresponding author at: Brawijaya Cardiovascular Research Center, Department of Cardiology and Vascular Medicine, Faculty of Medicine, Universitas Brawijaya, Malang, Indonesia.
E-mail address: kaputrin@gmail.com (N.K. Dwigustiningrum).

https://doi.org/10.21776/ub/hsj.2024.005.02.8
Received 3 January 2024; Received in revised form 11 January 2024; Accepted 25 January 2024
Available online 28 April 2024

explore the influence of strict and lenient heart rate control on the functional capacity, assessed via the Six-Minute Walk Test (SMWT), within the special population of individuals afflicted with AF and RMS.

2. Methods

Study Design

The design of the study was prospective and multicenter, adopted from the RACE II study. Our study was conducted at Saiful Anwar Hospital, Iskak Tulungagung Hospital, and Prima Husada Hospital within the timeframe of March 2023 to August 2023, with follow-up continuing until October 2023. RMS patients were randomized based on strict and lenient heart rate criteria, and subsequently evaluated using the SMWT and Health Related Quality of Life (HRQoL) assessments. Protocols were guided by The Strengthening the Reporting of Observational studies in Epidemiology (STROBE) checklist for prospective studies.[9] Participants were provided with thorough explanations regarding the aims, risks, and benefits of the study, and written consent was acquired. Participants had the right to opt out of the study at any point, and no incentives were offered for participation.

Patient Selection

Sample determination in this study employed consecutive sampling technique with calculations according to prospective study standards.[11] A minimum of 60 patients was necessary for the sample size, computed utilizing G*power software version 3.1 (Universität Düsseldorf, Düsseldorf, Germany, RRID:SCR_013726). Inclusion criteria encompassed patients under 80 years old with AF and moderate-severe RMS heart defects, those with additional valve abnormalities of milder degrees, and individuals with severe RMS ineligible for surgery but agreeing to follow-up until October 2023. Exclusion criteria comprised paroxysmal AF, hemodynamically unstable heart failure, NYHA class IV heart failure, recent hyperthyroidism treatment, current amiodarone use, prior stroke diagnosis, symptomatic bradycardia with conduction disorders, pacemaker or defibrillator implantation, malignancy, obstructive sleep apnea, congenital heart defects, AF secondary to non-cardiac causes, limited physical activity, and recent cardiac procedures such as coronary artery bypass grafting or heart transplantation.

Study Exposures and Outcomes

After obtaining informed consent and allowing for a 15-minute resting period, eligible participants were randomly distributed into either a strict or lenient heart rate group. The strict heart rate group was characterized by a resting heart rate of 60-80 beats per minute (bpm), while the lenient heart rate group had a resting heart rate of 81-110 bpm. Baseline heart rates were measured using the six-second timelines method with electrocardiography (ECG). For patients in the strict heart rate group with heart rates exceeding 81 bpm, medication adjustments were made to achieve the target heart rate, either by increasing the dose or adding alternative heart rate-controlling agents. Conversely, if a patient's heart rate fell below 80 bpm in the lenient heart rate group, medication doses were reduced accordingly. No changes in medication were made for patients whose heart rates fell within the randomized group. HRQoL and functional capacity were assessed before and after medication adjustments, utilizing the SF-36 questionnaire for HRQoL evaluation and the SMWT for measuring functional capacity. These assessments were conducted at baseline and again 3 months after reaching the target heart rate.

Statistical Analysis

Information was displayed as n(%) for categorical variables and as mean ± standard deviation (SD) for numerical variables. Categorical data at baseline were assessed utilizing the chi-squared test, while numerical data underwent normality testing using the Kolmogorov-Smirnov test. A p-value above 0.5 indicated normal distribution of the data, followed by the application of the t-test. A p-value less than 0.05 denoted statistical significance. For assessing the main findings, changes in HRQoL and functional capacity between baseline and follow-up were evaluated using paired t-tests. A p-value less than 0.05 suggested statistically significant effects. Effect estimates in this study were presented as mean differences with corresponding 95% confidence intervals (CI). Statistical analyses were conducted employing the Statistical Package for the Social Sciences (SPSS) software version 17.0 (SPSS Inc., Chicago, IL, RRID:SCR_002865).

3. Result

Table 1. Baseline characteristics of patients included in our study

Characteristics	Strict Heart Rate (n=29)	Lenient Heart Rate (n=32)	P value
Gender			0.273[a]
Man	7 (24.1%)	13 (40.6%)	
Woman	22 (75.9%)	19 (59.4%)	
Age*	53.00±13.41	52.37±10.88	0.842[c]
BMI			
Underweight	3 (10.3%)	4 (12.5%)	0.204[e]
Normal	19 (65.5%)	26 (81.3%)	
Obesitas I	1 (3.4%)	1 (3.1%)	
At risk	6 (20.7%)	1 (3.1%)	
Complaint			
DOE	12 (42.9%)	15 (46.9%)	0.959[a]
Fatigue	12 (41.4%)	9 (28.1%)	0.413[a]
Palpitation	12 (41.4%)	10 (31.3%)	0.578[a]
Leg swelling	3 (10.3%)	4 (12.5%)	1.000[b]
Chest pain	3 (10.3%)	8 (25.5%)	0.249[a]
Syncope	0 (0%)	1 (3.1%)	1.000[b]
Hypertension	3 (10.3%)	7 (21.9%)	0.307[b]
Smoker	1 (3.4%)	0 (0%)	0.475[b]
Planimetric MVA (cm^2)**	0.80 (0.39 – 2.20)	0.88 (0.42 – 2.20)	0.393[d]
MV gradient (mmHg)*	12.89 ± 4.15	10.64 ± 4.40	0.050[c]
PHT MVA (cm)**	0.90 (0.30 – 2.00)	0.84 (0.40 – 1.98)	0.866[d]
EF teich (%)**	56.61 ± 11.67	54.09 ± 12.89	0.445[c]
TAPSE (cm)*	1.96 ± 0.32	1.84 ± 0.33	0.150[c]

Characteristics	Strict Heart Rate (n=29)	Lenient Heart Rate (n=32)	P value
LA diameter (mm)**	4.65 (2.90 – 49)	4.90 (2.90 – 57)	0.225[d]
LAVI (ml/m^2)**	78.41 (43.23 – 148)	80 (18 – 600)	0.989[d]
Isolated MS	0	0	NA
Mixed valvular			0.055[e]
Moderate MS, mild MR	4 (28.6%)	15 (42.9%)	0.514
Severe MS, mild MR	8 (57.1%)	2 (14.3%)	0.023
Severe MS, mild-moderate MR	0 (0%)	0 (0%)	NA
Severe MS, moderate MR	2 (14.3%)	6 (42.9%)	-
Multiple valvular			0.489[e]
Moderate MS, mild AR	2 (9.1%)	2 (10.0%)	1.000
Severe MS, mild AR	16 (72.7%)	12 (60.0%)	0.724
Severe MS, mild-moderate AR	0 (0%)	2 (10%)	0.221
Severe MS, moderate AR	4 (18.2%)	4 (20.0%)	-
TR			0.509[e]
Mild TR with low PH	6 (20.7%)	9 (33.3%)	0.337
Mild TR with intermediate PH	1 (3.4%)	1 (3.7%)	0.802
Mild TR with severe PH	5 (17.2%)	2 (7.4%)	0.638
Moderate TR with low PH	1 (3.4%)	2 (7.4%)	0.435
Moderate TR with intermediate PH	6 (20.7%)	2 (7.4%)	0.514
Moderate TR with severe PH	4 (13.8%)	7 (25.9%)	0.290
Severe TR with low PH	0 (0%)	0 (0%)	NA
Severe TR with intermediate PH	0 (0%)	0 (0%)	NA
Severe TR with severe PH	6 (20.7%)	4 (14.8%)	-
Rate control therapy			0.012[a]
Bisoprolol (n(%))	10 (34.5%)	10 (31.3%)	0.096
Digoxin (n(%))	8 (27.6%)	19 (59.4%)	0.003
Bisoprolol & Digoxin (n(%))	11 (37.9%)	3 (9.4%)	-
Other therapy			
Loop diuretic	16 (55.2%)	15 (46.9%)	0.696[a]
ACEi/ARB	13 (44.8%)	8 (25.0%)	0.175[a]
MRA	10 (34.5%)	9 (28.1%)	0.796[a]
VKA	29 (100%)	32 (100%)	NA
Nitrat	1 (3.4%)	1 (3.1%)	1.000[b]
Simvastatin	2 (6.9%)	1 (3.1%)	0.600[b]
Lansoprazole	4 (13.8%)	1 (3.1%)	0.182[b]

[a] *Chi Square ;* [b] *Fisher ;* [c] *T test ;* [d] *Mann Whitney ;* [e] *Kruskal Wallis.* Data are presented as *mean±SD, ** median±SD, n : amount, (%) : percentage

AR, Aortic Regurgitation; BMI, Body Mass Index; DOE, Dyspnea on Exertion; EF, Ejection Fraction; LA, Left Atrial; LAVI, Left Atrial Volume Index; MR, Mitral Regurgitation; MV, Mitral Valve; MVA, Mitral Valve Area; NA, Not available; PHT, Pressure Half Time; TAPSE, Tricuspid Annular Plane Systolic Excursion.

Baseline Characteristics of Participants

Sixty-one eligible participants meeting the full list of inclusion and exclusion criteria were randomly allocated into two treatment groups (Figure 1). Among them, 29 participants (47.5%; mean age 53.00±13.41 years) were assigned to the strict heart rate control group (60-80 bpm), and 32 participants (52.4%; mean age 52.37±10.88 years) were assigned to the lenient heart rate control group (81-110 bpm). Female-predominant AF in patients diagnosed with moderate to severe MS demonstrated no significant difference between the strict and lenient heart rate treatment groups (p=0.273), and the mean age of both groups did not significantly differ (p=0.842). Dyspnea on exertion (DOE), fatigue, and palpitation were reported by participants in the lenient heart rate group, with DOE being the most common complaint, although no significant difference was observed between the groups. Echocardiograms conducted by consultants and cardiologists revealed no cases of isolated MS; instead, all participants presented with multiple valve lesions, including aortic and mitral involvement, as well as mixed MS and regurgitation in both groups. There was no notable distinction in the distribution of multiple and mixed valve involvement between the groups (p=0.489 & p=0.055). However, the severity of MS and regurgitation varied, with the strict heart rate group predominantly exhibiting severe MS and mild mitral regurgitation (MR) (57.1%), while the lenient heart rate group showed a dominance of moderate MS and mild MR (42.9%). Both groups displayed normal right ventricular (RV) contractility and preserved left ventricular ejection fraction (LVEF), with a slightly higher proportion of tricuspid annular plane systolic excursion (TAPSE) and LVEF observed in the strict heart rate group compared to the lenient heart rate group, although these variances did not reach statistical significance. There were no significant differences observed in the severity of tricuspid regurgitation (TR) and the probability of pulmonary hypertension (PH) between the groups. In terms of prescribed medication, digoxin therapy was more commonly used in the lenient heart rate group, while a combination of bisoprolol and digoxin was frequently prescribed in the strict heart rate group, resulting in a notable contrast among the groups (p=0.012). Detailed baseline characteristics of the patients are summarized in Table 1.

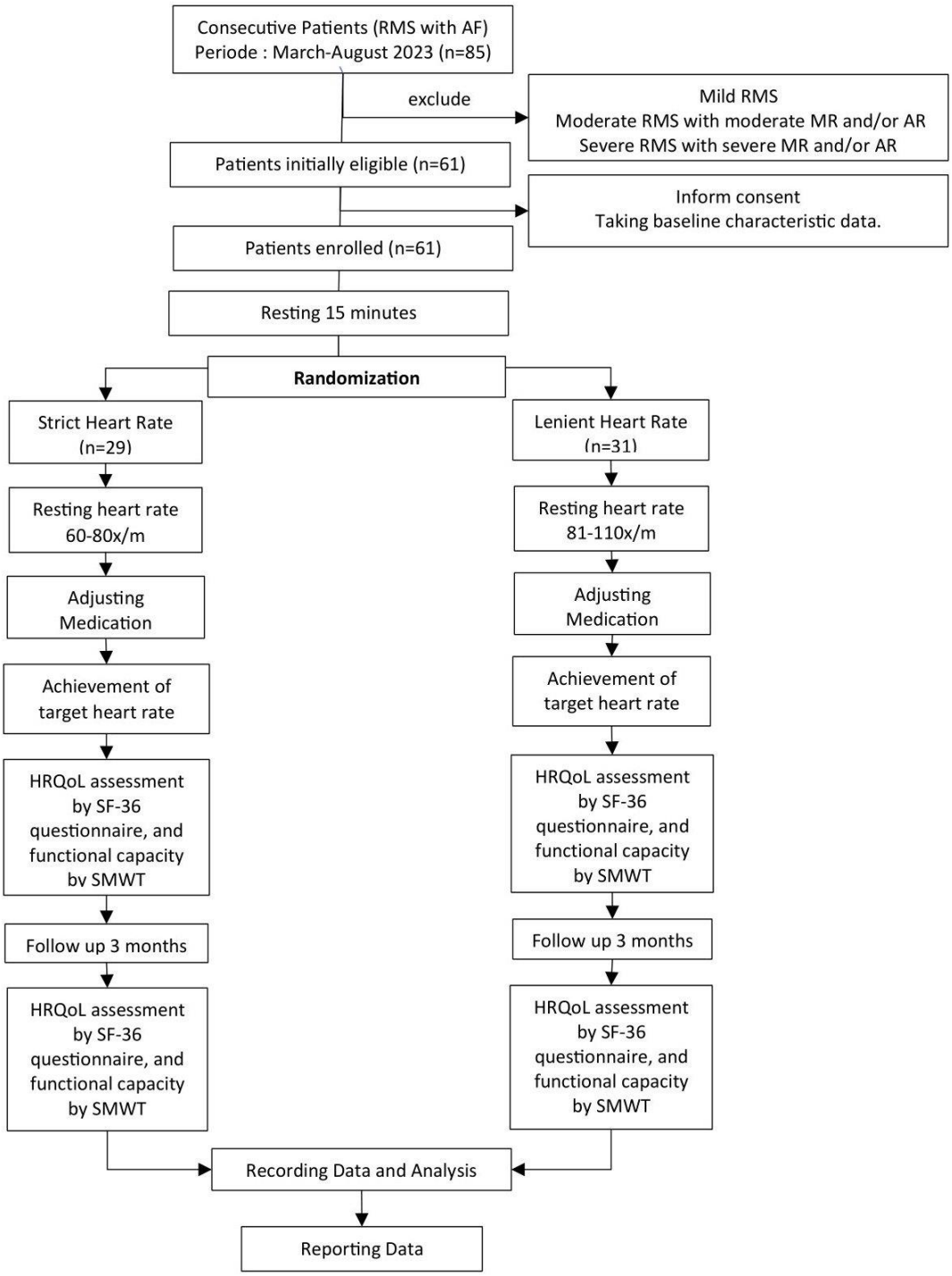

Figure 1. Flow chart randomization and follow-up. Note, AF, Atrial Fibrillation; RMS, Rheumatic Mitral Stenosis; HRQoL, Health Related Quality of Life; SF-36, Short Form-36; SMWT, Six-Minute Walk Test.

Assessing Health-Related Quality of Life (HRQoL)

The SF-36 questionnaire comprised eight subscales for evaluating HRQoL, covering aspects of physical health (including physical function, general health perception, and limitations in role due to physical problems and pain) and mental health (encompassing vitality, mental health, social function, and role limitations due to emotional problems). Comparing the strict heart rate group to the lenient heart rate group, the general health perception subscale exhibited a wider range in the former, with significant differences observed before and after treatment ($p=0.002$). Similarly, the physical function subscale demonstrated higher median values in the strict heart rate group compared to the lenient heart rate group, with significant disparities noted ($p=0.002$). However, in the physical limitations, body pain, social function, emotional limitations, vitality, and mental health subscales, both heart rate groups exhibited similar HRQoL levels before and after treatment. The analysis results regarding the differences in HRQoL between the initial and subsequent measurements are displayed in Table 2.

Table 2. Measurement of HRQoL in Strict and Lenient Heart Rate Groups

HRQoL	Heart Rate Adjustment		p-value
	Strict (n= 29)	Lenient (n= 32)	
A. Physical Health			
General Health Perception	46 (0 – 125)	22 (0 – 50)	0.002
Physical Function	63 (0 – 150)	30 (0 – 100)	0.002
Physical Limitations	35 (0 – 100)	33 (0 – 100)	0.906
Body Pain	11 (0 – 25)	8 (0 – 20)	0.232
B. Mental Health			
Social function	13 (0 – 25)	15 (0 – 30)	0.573
Emotional Limitations	21 (0 – 50)	13 (0 – 25)	0.127
Vitality	21 (0 – 100)	10 (0 – 25)	0.147
Mental Health	12 (0 – 40)	8 (0 – 40)	0.250

Primary data source, 2023. Data were presented as median±SD
HRQoL, Health Related Quality of Life

Assessing Functional Capacity

Metabolic Equivalent (METs) was computed utilizing a formula designed to estimate METs based on walking distance. Evaluation of functional capacity, including distance walked (in meters), VO2 max, and METs, revealed no notable disparities between the strict and lenient heart rate groups (p=0.135). Despite the lenient heart rate group exhibiting a VO2 max value nearly similar to that of the strict heart rate group, no notable variance was detected (p=0.426). Moreover, the METs value in the lenient heart rate group closely approximated that of the strict heart rate group, yet statistical significance was not achieved (p=0.429) (Table 3).

Table 3. Functional Capacity in Strict and Lenient Heart Rate Groups

Functional Capacity	Heart Rate Adjustment		p-value
	Strict (n=29)	Lenient (n=32)	
Distance walking (meter)	10 (0 – 106)	5 (0 – 70)	0.135
VO2 max	0.16 (0 – 1.08)	0.1 (0 – 1.81)	0.426
METs	0.06 (0 – 0.30)	0.035 (0 – 0.51)	0.429

Primary data source, 2023. Data are presented as median±SD
VO2 max, Volume of Oxygen Maximum; METs, Metabolic Equivalents

4. Discussion

This study revealed a predominant presence of women among AF patients with MS, constituting 75.9% and 59% of the strict and lenient heart rate groups, respectively. The participants in the strict heart rate group, ranging in age from 25 to 73 years with a mean age of 53.00 ± 13.41, and those in the lenient heart rate group, aged 27 to 78 years with a mean age of 52.37 ± 10.88, demonstrated a similar pattern. These findings aligned with an investigation undertaken by Husniyah and colleagues at Soetomo Hospital in Surabaya during 2018, indicating a higher prevalence of AF in women (58.3%) compared to men (41.7%) within the age range of 51 to 60 years. RHD emerged as the most common etiology of AF, accounting for 60% of cases.[12] Additionally, a study by Arslan et al. underscored age as a significant factor in AF development, particularly among older MS patients.[13]

RHD manifests as a condition characterized by various and diverse valve abnormalities. Heart disease affecting multiple valves involves the presence of stenotic or regurgitant lesions in two or more heart valves, while mixed heart disease denotes the presence of both stenotic and regurgitant lesions within a single valve.[14] Notably, none of the patients in this study presented with isolated MS. Among AF patients with RMS undergoing strict heart rate treatment, a significant proportion experienced aortic regurgitation (AR) valve involvement (75.9%) and MR (48.3%). Similarly, in the lenient heart rate treatment group, AR valve involvement was observed in 62.6% of patients, with MR valve involvement at 43.8%. In both treatment groups, AR valve abnormalities outnumbered MR valve abnormalities. Insights from a meta-analysis conducted by Noubiap and colleagues in 2020 revealed a higher prevalence of AF in patients with severe valve disease in contrast to individuals who mild to moderate valve disease. AF exhibited notably higher prevalence among patients with mixed mitral valve disease (65.6%) compared to those with isolated MS (33.9%) or MR (21.6%). The increased severity of age-related valve lesions and prolonged inflammatory processes may contribute to enhanced chamber remodeling and a heightened incidence of AF in RHD patients.[15]

The irregular rhythm and accelerated heart rate characteristic of AF often manifest in symptoms such as dizziness, fatigue, dyspnea, and palpitations. Achieving sufficient regulation of heart rate becomes crucial as it can alleviate these symptoms and improve hemodynamics by providing sufficient duration for ventricular filling while averting tachycardiomyopathy. In principle, stringent heart rate management, defined as maintaining a resting heart rate below 80 beats per minute, holds the potential to enhance operational capability and overall quality of life.[16] However, findings from the extensive RACE II study, conducted across the general AF population, demonstrated that lenient heart rate control was comparably effective to strict control and was notably easier to attain.[17]

Our study revealed a decrease in HRQoL among AF patients with RMS across all subscales, with significant differences noted particularly in the general health perception and physical function subscales within the strict heart rate group. These findings were consistent with previous study. Shei et al.'s study similarly indicated that both physical function and mental health were notably higher in the strict heart rate group compared to the lenient control group. Our findings aligned with Shei et al.'s findings, further emphasizing significant results observed on the physical function subscale within the strict heart rate treatment group.[16]

Furthermore, the analysis of the relationship between the SF-36 subscales and heart rate revealed a stronger association in the physical function and general health perception subscales within the strict heart rate group. Several factors may contribute to this observation. First, strict heart rate control could alleviate complaints of palpitations and other symptoms linked to heightened heart rate during strenuous activity. Second, excessive physical exertion, such as exercise, often leads to increased oxygen consumption, yet a rapid and irregular heart rate is associated with inadequate cardiac output, failing to meet the body's demands. This discrepancy can be rectified through strict heart rate management. Third, fatigue resulting from excessive activity can exacerbate symptoms related to arrhythmia. Effective heart rate control has the potential to alleviate these symptoms, offering significant relief to individuals.[16]

In this study, AF patients with MS were found to experience a decrease in functional capacity in both treatment groups, as described. Interestingly, there was no substantial variance detected in the enhancement of functional capacity, as measured by SMWT, between the two distinct groups. These results were in line with the investigation carried out by Michael Laufer-Perl and colleagues, which indicated that individuals with MS experienced a decrease in operational capability compared to subjects without heart disease

under control. This decline was primarily attributed to factors such as chronotropic incompetence and limited reserve of stroke volume, rather than solely valve dysfunction, illustrating the complex nature of this condition's impact on cardiovascular health.[18] These results were in line with the research conducted by Shei and colleagues, indicating that strict heart rate control might not have affected functional capacity in patients with permanent AF within the general population.[16] Additionally, Jaber et al's study yielded no observed correlation between resting heart rates below 90 beats per minute and functional capacity among AF patients.[19] Conversely, previous investigations by Nauman and colleagues as well as Laukkanen and colleagues had identified an inverse the association between resting heart rate and functional capacity in both the general population and those with heart conditions.[20,21] The intricate interplay the link among reduced atrial function, ventricular diastolic filling duration, and irregular heart rate in AF made the relationship between heart rate and functional capacity complex and often unclear.[19] Utilizing the SMWT for measuring functional capacity allows for the calculation of VO2 max and METs. Across both treatment groups, encompassing strict and lenient heart rate controls, a decrease in VO2 max and METs was observed. Notably, the VO2 max was lower under strict heart rate control, partly due to the influence of heart rate, a component in VO2 max calculation. In a multivariable analysis conducted by Michael Laufer-Perl, it was found that heart rate, tidal volume response, and variations in VO2 max emerged as independent predictors of functional capacity among patients with MS. These variables collectively contribute to understanding the nuanced dynamics influencing functional capacity in this cohort.[18]

There were several limitations apparent in our study. Primarily, the sample size of patients was relatively small, thus diminishing the statistical power of our findings. Expanding the number of participants would bolster the robustness and generalizability of the study outcomes. Additionally, a more prolonged follow-up period is essential to discern the enduring benefits of regulating lenient and strict heart rates among patients grappling with RMS compounded by AF. Understanding the long-term implications of these interventions is crucial for optimizing patient care strategies. Furthermore, augmenting examination parameters, particularly incorporating measurements of diastolic function, is imperative. Given the association between age and the prevalence of AF, integrating comprehensive assessments of diastolic function would provide valuable insights into the complex interplay of cardiovascular dynamics in this patient population.

5. Conclusion

In summary, our findings indicate that strict heart rate control exhibited greater significance in impacting the general health perception and physical function subscales compared to lenient heart rate management. However, this distinction was not observed in the context of the SMWT among patients contending with AF alongside rheumatic mitral stenosis. These results underscore the nuanced effects of heart rate regulation on various aspects of patient well-being and functional capacity within this specific clinical population. Further study is warranted to elucidate the underlying mechanisms driving these differential impacts and to optimize treatment strategies tailored to the multifaceted needs of individuals with this complex cardiovascular condition.

6. Declaration

6.1 Ethics Approval and Consent to participate

The subjects in this study are humans, so ethical rules must be followed. This research has passed the ethical due diligence, approved based on the Certificate of Ethical Eligibility No. 400/011/K.3/102.7/2023 issued by the Health Research Ethics Committee at Dr. Saiful Anwar Malang, Certified of Ethical Eligibility No. 070/1865/35.04.24.09/2023 issued by Iskak General Hospital and Certified of Ethical Eligibility No. 1003/RSPH/R-BLS/DIR/VIII/2023 issued by Prima Husada Hospital.

6.2. Consent for publication

Not applicable.

6.3 Availibility of data and materials

Data used in our study were presented in the main text.

6.4 Competing interests

Not applicable.

6.5 Funding Source

Not applicable.

6.6 Authors contributions

Idea/concept: AR, VY, MSR, AF, YOW. Design: PUT, AR. Control/supervision: AR, VY, MSR, AF, YOW. Data collection/processing: PUT, AR, AP, TRI, FIT. Analysis/interpretation: PUT, VY, AR. Literature review: VY, AR, MSR, AF. Writing the article: PUT, VY, AR. Critical review: VY, AR, MSR, AF. All authors have critically reviewed and approved the final draft and are possible for the content and similarity index of the manuscript.

6.7 Acknowledgements

We thank to Brawijaya Cardiovascular Research Center

References

1. Arafuri N, Murni IK, Julia M, Nugroho S, Soehadi N. Survival of rheumatic heart disease in indonesian children. Glob Heart 2022;17(1):71.doi: 10.5334/gh.1160.

2. Otto CM, Nishimura RA, Bonow RO, Carabello BA, Erwin JP, 3rd, Gentile F, et al. 2020 acc/AHA guideline for the management of patients with valvular heart disease: Executive summary: A report of the american college of cardiology/american heart association joint committee on clinical practice guidelines. Circulation 2021;143(5):e35-e71.doi: 10.1161/CIR.0000000000000932.

3. Stassen J, Butcher SC, Namazi F, Ajmone Marsan N, Bax JJ, Delgado V. Left atrial deformation imaging and atrial fibrillation in patients with rheumatic mitral stenosis. J Am Soc Echocardiogr 2022;35(5):486-494.doi: 10.1016/j.echo.2021.12.010.

4. Permataranny MB, Yanni M, Permana H. Profil penderita stenosis mitral reumatik di RSUP Dr. M. Djamil Padang tahun 2012-2016. Jurnal Kesehatan Andalas 2019;8(1):28-36.doi: 10.25077/jka.v8i1.967.

5. Peters F, Karthikeyan G, Abrams J, Muhwava L, Zuhlke L. Rheumatic heart disease: current status of diagnosis and therapy. Cardiovasc Diagn Ther 2020;10(2):305-315.doi: 10.21037/cdt.2019.10.07.

6. Bansal A, Sarkar PG, Chaturvedi V. Atrial fibrillation in rheumatic heart disease. Current Treatment Options in Cardiovascular Medicine 2020;22(11):42.doi: 10.1007/s11936-020-00845-7.

7. Giannini C, Mazzola M, Pugliese NR, Petronio AS. Mitral valve stenosis in the current era: a changing landscape. J Cardiovasc Med (Hagerstown) 2022;23(11):701-709.doi: 10.2459/JCM.0000000000001384.

8. Groenveld HF, Crijns HJ, Tijssen JG, Alings M, Hillege HL, Tuininga YS, et al. Rate control in atrial fibrillation, insight into the RACE II study. Neth Heart J 2013;21(4):199-204.doi: 10.1007/s12471-013-0391-1.

9. Cuschieri S. The STROBE guidelines. Saudi J Anaesth 2019;13(1):S31-S34.doi: 10.4103/sja.SJA_543_18.

10. Goodyear MD, Krleza-Jeric K, Lemmens T. The Declaration of Helsinki. BMJ 2007;335(7621):624-625.doi: 10.1136/bmj.39339.610000.BE.

11. Charan J, Biswas T. How to calculate sample size for different study designs in medical research? Indian J Psychol Med 2013;35(2):121-126.doi: 10.4103/0253-7176.116232.

12. Husniyah B, Herwanto B, Handajani NI. Characteristics of atrial fibrillation based on age, sex, and etiology. JUXTA: Jurnal Ilmiah Mahasiswa Kedokteran Universitas Airlangga 2020;11(2):86.doi: 10.20473/juxta.V11I22020.86-89.

13. Arslan O, Saricam E, Kartal H, Sarak T. The importance of age: independent risk factor for atrial fibrillation in isolated rheumatic mitral stenosis. Journal of Contemporary Medicine 2020;10(2):186-189.doi: 10.16899/jcm.738502.

14. Unger P, Pibarot P, Tribouilloy C, Lancellotti P, Maisano F, Iung B, et al. Multiple and mixed valvular heart diseases. Circ Cardiovasc Imaging 2018;11(8):e007862.doi: 10.1161/CIRCIMAGING.118.007862.

15. Noubiap JJ, Nyaga UF, Ndoadoumgue AL, Nkeck JR, Ngouo A, Bigna JJ. Meta-analysis of the incidence, prevalence, and correlates of atrial fibrillation in rheumatic heart disease. Glob Heart 2020;15(1):38.doi: 10.5334/gh.807.

16. She F, Ma Y, Li Y, Li L, Xu W, Wang H, et al. Influence of heart rate control on exercise capacity and quality of life in patients with permanent atrial fibrillation. BMC Cardiovasc Disord 2019;19(1):308.doi: 10.1186/s12872-019-01293-3.

17. Van Gelder IC, Groenveld HF, Crijns HJ, Tuininga YS, Tijssen JG, Alings AM, et al. Lenient versus strict rate control in patients with atrial fibrillation. N Engl J Med 2010;362(15):1363-1373.doi: 10.1056/NEJMoa1001337.

18. Laufer-Perl M, Gura Y, Shimiaie J, Sherez J, Pressman GS, Aviram G, et al. Mechanisms of effort intolerance in patients with rheumatic mitral stenosis: Combined echocardiography and cardiopulmonary stress protocol. JACC Cardiovasc Imaging 2017;10(6):622-633.doi: 10.1016/j.jcmg.2016.07.011.

19. Jaber J, Cirenza C, Amaral A, Jaber J, Oliveira Filho JA, de Paola AA. Correlation between heart rate control during exercise and exercise capacity in patients with chronic atrial fibrillation. Clin Cardiol 2011;34(9):533-536.doi: 10.1002/clc.20948.

20. Nauman J, Aspenes ST, Nilsen TI, Vatten LJ, Wisloff U. A prospective population study of resting heart rate and peak oxygen uptake (the HUNT Study, Norway). PLoS One 2012;7(9):e45021.doi: 10.1371/journal.pone.0045021.

21. Laukkanen JA, Khan H, Kunutsor S. Cardiorespiratory fitness, muscle strength and risk of cardiovascular outcomes. J Public Health Emerg 2017;1(6):60.doi: 10.21037/jphe.2017.05.10.

Heart Sci J 2024; 5(2): 51-56

Contents list available at www.heartscience.ub.ac.id

Heart Science Journal

Journal Homepage : www.heartscience.ub.ac.id

Original Article

Effects of the Low-Dose Colchicine Regimen on Left Ventricular Adverse Remodeling and Systolic Function in Acute Myocardial Infarction Patients with Anterior ST-Segment Elevation Undergoing Primary Percutaneous Coronary Intervention: A Randomized Controlled Trial

Fahreza Caesario[1*], Indra Prasetya[2], Mohammad Saifur Rohman[2], Budi Satrijo[2], Setyasih Anjarwani[2]

[1]Brawijaya Cardiovascular Research Center, Department of Cardiology and Vascular Medicine, Faculty of Medicine, Universitas Brawijaya, Malang, Indonesia.
[2]Department of Cardiology and Vascular Medicine, Faculty of Medicine, Universitas Brawijaya, Malang, Indonesia.

ARTICLE INFO

Keyword :
Adverse Remodeling;
Colchicine;
Reperfusion Injury;
STEMI;
Systolic Function.

ABSTRACT

Background: Inflammation in reperfusion injury results in adverse ventricular remodeling and reduced systolic function. The anti-inflammatory effects of colchicine have shown beneficial effects in cardiovascular disease.
Objective: To determine the effects of low-dose colchicine on left ventricular (LV) adverse remodeling and systolic function in acute myocardial infarction with anterior ST-segment elevation (anterior STEMI) patients undergoing primary percutaneous coronary intervention (PPCI).
Material and Methods: This prospective, randomized, double-blinded study randomly assigned anterior STEMI patients who underwent PPCI to receive either low-dose colchicine (1mg loading dose followed by 0.5mg daily) or a matching placebo for 30 days in addition to standard therapy. Outcomes included adverse LV remodeling and systolic function, determined by transthoracic echocardiography (TTE) in the first and third month.
Result: Enrollment comprised 196 patients, with 92 patients in the colchicine group and 104 patients in the placebo group. Adverse LV remodeling and a decrease in systolic function were observed in both groups. No significant differences in LV remodeling were observed between the colchicine and placebo groups, as indicated by the change in LV end-systolic volume index (LVESVI) at the first month (16.5% vs. 18.25% [p=0.091]) and third month (19.5% vs. 21.5% [p=0.124]). Similar results were found in LV systolic function between the colchicine and placebo groups, with a reduction in LV ejection fraction (LVEF) observed in the first month (6.3% vs. 8.95% [p=0.083]) and third month (9.5% vs. 11.5% [p=0.163]). Diarrhea was the only reported side effect, occurring in 6.5% of patients in the colchicine group.
Conclusion: Low-dose colchicine administration in anterior STEMI patients undergoing PPCI did not reduce LV adverse remodeling or systolic function.

1. Introduction

In terms of morbidity, patients with anterior ST-elevation Myocardial Infarction (STEMI) remain at high risk of new-onset heart failure, with a 26% incidence in the first year despite undergoing Primary Percutaneous Coronary Intervention (PPCI).[1] In addition to the large amount of vascularized tissue in anterior STEMI, the extensive infarct size is also contributed to by reperfusion injuries from PPCI procedures.[2] The inflammatory response is essential in reperfusion injury, leading to adverse ventricular remodeling and significantly reduced cardiac systolic function.[3] Commonly, widely recognized anti-inflammatory medications, such as colchicine, are frequently studied for their capacity to inhibit several mediators involved in the post-myocardial infarction inflammatory pathway.

In various animal and clinical studies, Colchicine, a botanical alkaloid, is known to have anti-inflammatory and anti-fibrotic effects on the injured heart.[4–6] This drug utilizes various pathways to suppress inflammation and fibrosis, ranging from inhibiting the inflammasome to regulating proteins that controll cell proliferation.[6,7] In an animal study, colchicine decreased adverse cardiac remodeling and attenuated the development of heart failure from myocardial infarction following permanent left anterior descending coronary artery occlusion.[8] A clinical study reported that short-term, high-dose colchicine administration can significantly reduce infarct size in STEMI patients.[7] However, it remains unclear whether low-dose colchicine therapy over extended periods reduces reperfusion injury compared with a placebo in patients with acute STEMI. This study aimed to determine the effects of a low-dose colchicine regimen as an additional medical treatment for reperfusion injury in patients with anterior STEMI undergoing PPCI. If this study yields positive results, low-dose colchicine may be considered as a readily available, cost-effective adjunctive therapy with fewer side effects, in addition to the optimal therapy recommended for post-PCI STEMI patients.

* Corresponding author at: Brawijaya Cardiovascular Research Center, Department of Cardiology and Vascular Medicine, Faculty of Medicine, Universitas Brawijaya, Malang, Indonesia.
E-mail address: fahrezacaesario@gmail.com (F. Caesario).

https://doi.org/10.21776/ub/hsj.2024.005.02.9
Received 18 January 2024; Received in revised form 28 January 2024; Accepted 31 January 2024
Available online 28 April 2024

2. Material and Methods

Study Design

From February 2022 to July 2023, we conducted this prospective, randomized, double-blinded, placebo-controlled trial at RSUD dr. Saiful Anwar Malang. The treatment and control groups in this study were randomly assigned without the knowledge of the patients or the researchers themselves, and were followed for 3 months to observe the primary outcome. The hospital's Health Research Ethics Committee approved the study based on Certificate of Ethical Eligibility No. 400/235/K.3/302/2020. All participants provided written informed consent, and the protocol adhered to the principles of the Declaration of Helsinki. No incentive payments were made to participants in this study. Participants experiencing drug side effects would have their treatment covered by the research team.

Study Patients

Eligible patients were adults (>18 years old) who had presented with anterior STEMI within the past 7 days, underwent PPCI, and received guidelines-based medical therapy for STEMI as indicated. The diagnosis of anterior STEMI was based on clinical symptoms of Acute Coronary Syndromes (ACS) supported by Electrocardiography (ECG) examination that showed elevation of ST-segment in anterior (V1-5), anterior extensive (I,aVL, V1-6), and anteroseptal leads (V1-4), with evidence of acute total occlusion in Left Anterior Descending (LAD) coronary artery (Thrombolysis in Myocardial Infarction [TIMI] grade 0 or 1 flow). The main exclusion criteria included comorbidities, cardiogenic shock, severe renal failure (eGFR <30 mL/kg/min), hypersensitivity to colchicine, andcontraindications to colchicine. Detailed inclusion and exclusion criteria are outlined in the Supplemental Material.

Randomization

Computer-generated randomization was used to assign patients to colchicine or placebo in a 1:1 ratio. Colchicine and placebo were over-encapsulated (1 capsule containing 0.5mg of colchicine or placebo) by an independent packaging team not involved in the rest of the trial. This ensured that the intervention drugs and placebo had identical appearances, thereby blinding investigators, the study coordinator, and patients to treatment allocation. To design an unbiased controlled trial, the investigators, patients, and follow-up team members were all kept completely unaware.

Study Procedure

The patient received informed consent after meeting the specificinclusion and exclusion. The patient underwent treatment according to established STEMI guidelines, including Angiotensin-Converting Enzyme Inhibitors (ACE-I) /Angiotensin Receptor Blockers (ARBs), β-blockers, high-intensity statins, acetylsalicylic acid, and ticagrelor or clopidogrel at recommended daily dosages. Patients received study medication based on randomization: the intervention group received colchicine with a loading dose of 1 mg at 1-2 hours before PPCI, followed by a daily dose of 0.5 mg for a maximum of 30 days, whereas the control group received a placebo with a similar regimen. Medication adherence was assessed by pill count one month later. Transthoracic Echocardiography (TTE) was performed at three time points: baseline (within 24 hours), one month, and three months after the PPCI procedure. Research team members conducted a reminder via telephone 2-3 days before the examination.

Echocardiography Examination

TTE examinations were performed on the PHILIPS AFFINITI 50G to assess left ventricular adverse remodeling and systolic function. Images were acquired following a standardized protocol and independently verified by two observers. The observers were blinded to clinical trial information and treatment allocation. Left ventricular adverse remodeling was defined as changes in left ventricular geometry characterized by a ≥ 20% increase in the Left Ventricular End Diastolic Volume Index (LVEDVI) and/or a ≥ 15% increase in Left Ventricular End Systolic Volume Index (LVESVI). Both adverse remodeling parameters were assessed by measuringLeft Ventricular End Diastolic Volume or End Systolic Volume (LVEDV/LVESV) obtained from the Apical 4 chamber (A4c) view and Apical 2 chamber (A2c) views, then divided by the patient Body Surface Area (BSA). Left ventricular systolic function was assessed by measuring the Left Ventricular Ejection Fraction (LVEF) through biplane (BP) acquisition from A4c and A2c views and reported as a percentage. Interobserver Intraclass Correlation Coefficient (ICC) for LVEDV, LVESV, and LVEF by BP was assessed in 10 randomly selected patients by both observers. The corresponding interobserver ICCs were 0.99, 0.98, and 0.99 for LVEDV, LVESV, and LVEF, respectively.

Study Outcome

The outcome of this study involved comparing changes in left LVEDVI, LVESVI, and LVEF through BP assessment in both groups from baseline to the first and third month. This aimed to identify the occurrence of left ventricular adverse remodeling and a decrease in systolic function.

Sample Size and Statistical Analysis

The sampling technique in this study involved randomized sampling. The sample size for this study was determined based on the purpose and type of the study, taking into account findings from previous study. The assumption included an error of 5%, a power of 80%, and an effect size of approximately 30% in both groups, with a 1:1 ratio. Considering an estimated 10% dropout rate from the initially counted samples, a minimum of 90 participants in each group, totaling a minimum of 180 samples, was anticipated.

The collected data were entered into the Statistical Package for the Social Sciences (SPSS), Version 23.0 (IBM, NY, US). The data were described using descriptive statistics, including mean (± standard deviation) and median (interquartile range) for quantitative variables, and number (%) for qualitative factors. Independent sample t-test and Chi-square test were used for data analysis. Parameter values in each group were compared using the Mann-Whitney test. The Chi-square test was also used to compare qualitative traits and characteristics between the two groups. Frequency histograms and Kolmogorov-Smirnov tests were used to assess distribution normality.

3. Results

From February 2022 to July 2023, this study involved 223 patients diagnosed with anterior STEMI who underwent PPCI. A total of 207 patients meeting the inclusion and exclusion criteria were then randomized into two treatment groups. After 3 months of follow-up, 11 patients dropped out, leaving details for 92 patients in the colchicine group and 104 patients in the placebo group out of the initial 207 patients (Figure 1).

The baseline characteristics of the patients are described in Table 1. The colchicine and placebo groups were predominantly male (83.7% & 72.1%) with an average age of 56.43 ± 8.96 and 55.47 ± 9.68, respectively, and no significant differences were observed. Smoking, hypertension, and dyslipidemia were common risk factors in both groups. No differences were found in the level of cardiac enzymes (troponin I and CKMB) between the groups. STEMI patients often arrived at our emergency department with a tendency toward delay, as indicated by the predominance of onset > 12 hours in both groups. The location of LAD occlusion showed no significant difference between the two groups, either in the proximal or non-proximal sections. All patients received guideline-based medical therapy for standard ACS treatment. Adherence to the study treatment was

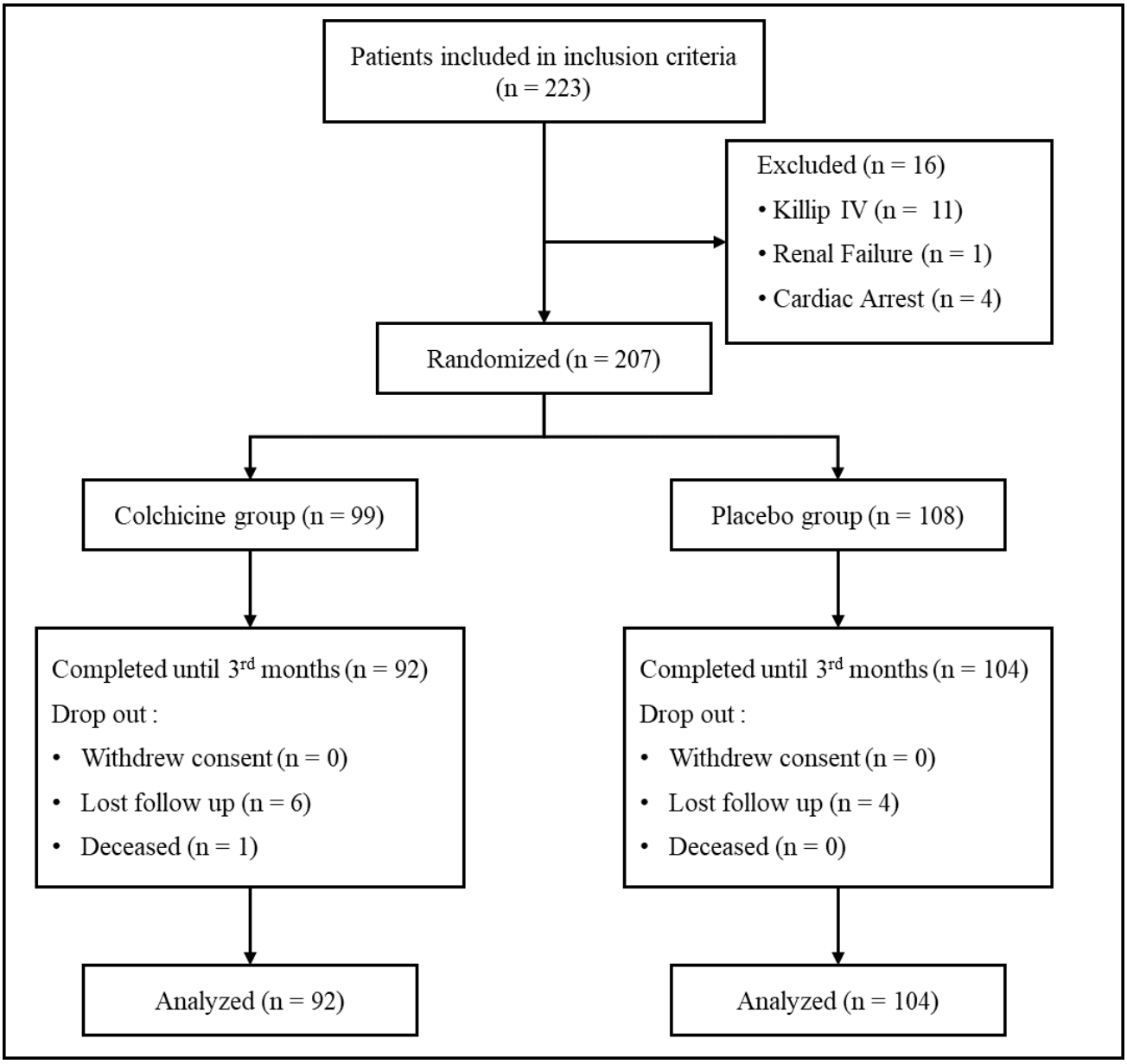

Figure 1. Enrollment and follow-up of the patients. 223 patients were enrolled, and 207 patients were randomized after matching with exclusion criteria. After 3 months of follow-up, a total of 11 patients were lost to follow-up and deceased, leaving 196 patients to be analyzed, with the distribution of 92 patients in the colchicine group and 104 patients in the placebo group.

measured by counting the remaining medicine; consumption of more than 80% of the prescribed drugs was considered adherent. Diarrhea was the only side effect of colchicine found in the intervention group, occurring in a total of 6 patients (6.5%).

Evaluation of the left ventricular adverse remodeling and systolic function parameters including LVEDVI, LVESVI, and LVEF Biplane, measured at baseline, first, and third month, is described in Table 2. At baseline, the LVEDVI, LVESVI, and LVEF Biplane values in the colchicine and placebo groups were nearly similar; with no significant differences observed (73.5 vs. 75 ml/m^2 [p=0.638]; 31.5 vs 32.5 ml/m^2 [p=0.403]; and 55% vs 55% [p=0.468]). Although LVEDVI values at the first and third-month evaluation in the colchicine group were lower than the placebo (78 vs. 81 ml/m2; 81.5 vs. 84 ml/m2), these differences were not not statistically significant (p=0.147 & p=0.156). The values of LVESVI were significantly lower (36.09 vs. 38.19 ml/m^2 [p=0.02]; 38.87 vs. 40.86 ml/m^2 [p=0.027]), and the LVEF Biplane was significantly higher (52 vs. 50% [p=0.027]; 50.5 vs. 49% [p=0.044]) in the colchicine group compared to the placebo group at the first and third-month evaluations.

Left ventricle adverse remodeling was observed in both the colchicine and placebo groups at the first and third-month evaluations, characterized by an average increase in LVESVI values >15% as per the operational definition. In contrast, the rise in LVEDVI values in both groups at the first and third month did not meet the criteria (Table 3). Although the increase in LVESVI and LVEDVI values was lower in the colchicine group, there were no significant differences compared to the placebo group at the first (16.5% vs. 18.25% [p=0.091]; 7.27% vs. 8.12% [p=0.134]) and third month evaluation (19.5% vs. 21.5% [p=0.124]; 11% vs 12% [p=0.221]). Decrease of left ventricular systolic function was also observed in both groups, evidenced by a reduction in LVEF Biplane at the first and third-month evaluations (Table 3). Similar to the previous results, the lower values of the LVEF Biplane reduction in the colchicine group also did not show significant differences compared to the placebo group in the first month (6.3% vs. 8.95% [p=0.083]) and third-month evaluations (9.5% vs. 11.5% [p=0.163]).

Table 1. Baseline characteristics of the patients

Characteristic	Colchicine (n=92)	Placebo (n=104)	*P* value
Age, year ± sd	56.43 ± 8.96	55.47 ± 9.68	0.472[c]
BSA, m^2	1.73 ± 0.32	1.69 ± 0.24	0.511[c]
Sex			
Male	77 (83.7%)	75 (72.1%)	0.077[a]
Risk factors			
Smoker	66 (71.7%)	60 (57.7%)	0.058[a]
Diabetes Mellitus	32 (34.8%)	43 (41.3%)	0.426[a]
Hypertension	53 (57.6%)	69 (66.3%)	0.266[a]
Dyslipidemia	78 (84.7%)	83 (79.8%)	0.103[a]
Cardiac enzymes			
Troponin, median (IQR)	8.8 (0.9 – 24.47)	8.7 (0.8 -20.15)	0.611[d]
CKMB, median (IQR)	57 (28 – 213)	44.5 (27 – 185.75)	0.131[d]
STEMI Onset			
< 12 hours	21 (22.8%)	26 (25%)	0.787[a]
> 12 hours	71 (77.2%)	78 (75%)	0.852[a]
Part of LAD			
Prox LAD	46 (50.0%)	50 (48.1%)	0.900[a]
Non-Prox LAD	46 (50.0%)	54 (51.9%)	0.857[a]
Medication			
ACE-I/ARBs	92 (100%)	104 (100%)	0.921[a]
β-blockers	92 (100%)	104 (100%)	0.963[a]
High-intensity statin	92 (100%)	104 (100%)	0.963[a]
DAPT	92 (100%)	104 (100%)	0.963[a]
Treatment adherence	92 (100%)	104 (100%)	0.963[a]

*note: BSA: Body Surface Area; CKMB: Creatinine Kinase-MB; ACE-I: Angiotensin Converting Enzyme Inhibitor; ARBs: Angiotensin Receptor Blockers; DAPT: Dual Anti Platelet Therapy; GDMT: Guideline-Directed Medical Therapy; STEMI: ST Elevation Myocardial Infarct; LAD: Left Anterior Descending Artery;
[a] Chi Square ; [c] T test ; [d] Mann Whitney

Table 2. Comparison of left ventricular adverse remodeling and systolic function parameters at baseline, first and third months

	Baseline			1 Month			3 Months		
	Placebo (n=104)	Colchicine (n=92)	*P* value	Placebo (n=104)	Colchicine (n=92)	*P* value	Placebo (n=104)	Colchicine (n=92)	*P* value
LVEDVI (ml/m2), median (IQR)	75 (67 – 83.8)	73.5 (66.25 – 83)	0.638[d]	81 (73 – 89.75)	78 (71– 88)	0.147[d]	84 (76 – 93)	81.5 (74– 90.75)	0.156[d]
LVESVI (ml/m2), median (IQR)	32.5 (28 – 37)	31.5 (27 – 36)	0.403[d]	38.19 ± 6.13	36.09 ± 6.31	0.020[c]	40.86 ± 6.21)	38.87 ± 6.31	0.027[c]
LVEF Biplane (%), median (IQR)	55 (54 – 61.75)	55 (54 – 63)	0.468[d]	50 (48 – 57)	52 (50 – 60.75)	0.027[d]	49 (47 – 55)	50.5 (48 – 58)	0.044[d]

*note: LVEDVI: Left Ventricular End Diastolic Volume Index; LVESVI: Left Ventricular End Systolic Volume Index; LVEF: Left Ventricular Ejection Fraction; [c] T test ; [d] Mann Whitney

Table 3. Comparison of ΔLVEDVI, ΔLVESVI, and ΔLVEF Biplane at baseline measurement to the first and third months evaluation.

	Δ Baseline - 1 Month			Δ Baseline - 3 Months		
	Placebo (n=104)	Colchicine (n=92)	*P* value	Placebo (n=104)	Colchicine (n=92)	*P* value
LVEDVI (ml/m2), median (IQR)	8.12 ± 2.55	7.27 ± 1.67	0.134[c]	12 (10 – 13)	11 (9 – 14)	0.221[d]
LVESVI (ml/m2), median (IQR)	18.25[+] (13.82 – 21.40)	16.5[+] (11.12 – 19.15)	0.091[d]	21.50[+] (17 – 27)	19[+] (15.25 – 26)	0.124[d]
ΔLVEF Biplane (%), median (IQR)	-8.95 (-11.1 – -6.1)	-6.30 (-10.72 – -5.8)	0.083[d]	-11.5 (-13 – -10)	-9.5 (-12 – -9.5)	0.163[d]

[+]Left ventricle adverse remodelling defined as ΔLVEDVI ≥ 20% and/or ΔLVESVI ≥ 15%
*note: ΔLVEDVI: Differences of Left Ventricular End Diastolic Volume Index; ΔLVESVI: Differences of Left Ventricular End Systolic Volume Index; ΔLVEF: Differences of Left Ventricular Ejection Fraction
[c] T test ; [d] Mann Whitney

4. Discussion

Our study revealed that the administration of low-dose colchicine as an additional medical treatment for up to 30 days did not reduce the occurrence of left ventricle adverse remodeling and the decrease of left ventricle systolic functioncompared to placebo in anterior STEMI patients after PPCI. There are both similarities and differences between our findings and previousstudies on colchicine. Inflammation is a crucial factor contributing to adverse left ventricle remodeling and reduction in systolic function following myocardial reperfusion, potentially leading to various cardiovascular events.[9,10] Low-dose colchicine, as utilized in our study, has been acknowledged for its benefits in suppressing chronic inflammatory processes, as published in The Colchicine Cardiovascular Outcome Trial (COLCOT) and Low-Dose Colchicine 2 (LoDoCo-2) trials. Those studies demonstrated favorable cardiovascular outcomes through the administration of low-dose colchicine (0.5 mg) daily during median follow-ups of 22 and 28 months in patients with acute and chronic coronary syndromes.[11,12] Other studies with a similar design demonstrated benefits in reducing rehospitalization by administering low-dose colchicine for one month in patients with STEMI who undergo PCI therapy.[13] European Society of Cardiology (ESC) also recommended low-dose colchicine for long-term management in their latest ACS guideline when risk factors are insufficiently controlled or there are recurrent cardiovascular disease events despite optimal therapy.[14] Another study that assessed the early administration of low-dose colchicine within 30 days after acute myocardial infarction failed to demonstrate a reduction in C-reactive protein (CRP), an inflammatory biomarker, during follow-up.[15] At a higher dosage, as investigated in the COVERT MI trial, administering colchicine at the time of reperfusion and continued for 5 days also failed to demonstrate a significant difference in infarct size reduction in STEMI patients compared to placebo. As a result, at the 3-month follow-up, there was no significant difference in left ventricle remodeling between the two groups, aligning with our study findings.[16] On the contrary, a pilot study with the same colchicine dosage regimen as the previously mentioned study yielded different results. It demonstrated the beneficial effect of high-dose colchicine given for 5 days in reducing infarct size in STEMI patients with an onset of less than 12 hours.[7]

Based on findings from previous studies, our study's failure to demonstrate colchicine's post-reperfusion anti-inflammatory effects may be attributed to the determination of the dose and duration of administration. As is well known, colchicine exhibits dose-dependent effects within a limited therapeutic window.[17] Peak plasma levels of colchicine after oral congestion are generally obtained after 0.5–3 hours and drop over the next 2 hours. The bioavailability of colchicine ranges from 24% to 88%, with a mean of 45%.[18] Inflammatory response after reperfusion exhibits a proinflammatory phase lasting 3 to 7 days, with the peak occurring between 24 and 72 hours.[19] An animal study found that pharmacological inhibition of the inflammasome within 1 hour of reperfusion limits secondary inflammatory injury and infarct size following myocardial ischemia–reperfusion.[20] Hence, the timing of early colchicine administration in our study just before PPCI seemed appropriate. Other factors, such as total ischemic time, area at risk size, or factors associated with reperfusion, may contribute to the absence of the efficacy of colchicine in reducing left ventricle adverse remodeling and systolic function decline.[16]

This study identified six patients who experienced gastrointestinal adverse effects, specifically diarrhea, with colchicine use, raising concerns about its safety. Gastrointestinal issues are a potential side effect of colchicine use, as indicated by the prior studies.[11,12] This investigation did not include any clinical interaction between colchicine and other medications. No clinical symptoms of rhabdomyolysis or hemorrhage were observed during the 3-month follow-up. Colchicine interaction with statins, a crucial STEMI treatment, have been noted in previous studies.[21] This demonstrates the efficacy of low-dose colchicine in STEMI, although a laboratory assessment may be necessary to clarify potential medication interactions.

There were several limitations in our study. First, the number of patients involved is insufficient to fully represent the benefits of low-dose colchicine administration. Second, this study utilized the TTE evaluation, which is not commonly employed for determining the left ventricular adverse remodeling and systolic function. Advanced imaging examinations, such as cardiac Magnetic Resonance Imaging (MRI), may be preferred. Third, our study only evaluates the early phase of cardiac remodeling. A longer study period might be needed to assess remodeling progression.

5. Conclusion

In summary, our study provides no evidence that early low-dose colchicine administration for 30 days in anterior STEMI patients undergoing PPCI could reduce the occurrence of left ventricle adverse remodeling and systolic function decline compared with placebo. Further study is required to investigate the dose-response and timing of colchicine administration, aiming to identify a therapy that effectively reduces left ventricle adverse remodeling and systolic function decline after reperfusion of STEMI.

6. Declaration

6.1 Ethics Approval and Consent to participate
The subjects in this study are humans, so ethical rules must be followed. This research has passed the ethical due diligence, approved based on the Certificate of Ethical Eligibility No. 400/235/K.3/302/2020 issued by the Health Research Ethics Committee at Dr. Saiful Anwar Malang.

6.2. Consent for publication
Not applicable.

6.3 Availibility of data and materials
Data used in our study were presented in the main text.

6.4 Competing interests
Not applicable.

6.5 Funding Source
Not applicable.

6.6 Authors contributions
Idea/concept: FC, IP, MSR. Design: FC, IP, MSR. Control/supervision: IP, MSR, BS, SA. Data collection/processing: FC, IP, MSR. Analysis/interpretation: FC, IP, MSR. Literature review: FC. Writing the article: FC. Critical review: IP, MSR, BS, SA. All authors have critically reviewed and approved the final draft and are possible for the content and similarity index of the manuscript.

6.7 Acknowledgements
We thank to Brawijaya Cardiovascular Research Center

References

1. Van Tassell B, Talasaz AH, Redlich G, Ziegelaar B, Abbate A. A Real-World Analysis of New-Onset Heart Failure After Anterior Wall ST-Elevation Acute Myocardial Infarction in the United States. *Am J Cardiol*. 2023;211:245-250. doi:10.1016/j.amjcard.2023.11.037

2. Hausenloy DJ, Yellon DM. Myocardial ischemia-reperfusion injury: a neglected therapeutic target. *Journal of Clinical Investigation*. 2013;123(1):92-100. doi:10.1172/JCI62874

3. Yalta K, Yilmaz MB, Yalta T, Palabiyik O, Taylan G, Zorkun C. Late Versus Early Myocardial Remodeling After Acute Myocardial Infarction: A Comparative Review on Mechanistic Insights and Clinical Implications. *J Cardiovasc Pharmacol Ther*. 2020;25(1):15-26. doi:10.1177/1074248419869618

4. González L, Bulnes JF, Orellana MP, Muñoz Venturelli P, Martínez Rodriguez G. The Role of Colchicine in Atherosclerosis: From Bench to Bedside. *Pharmaceutics*. 2022;14(7):1395. doi:10.3390/pharmaceutics14071395

5. Akodad M, Sicard P, Fauconnier J, Roubille F. Colchicine and myocardial infarction: A review. *Arch Cardiovasc Dis*. 2020;113(10):652-659. doi:10.1016/j.acvd.2020.04.007

6. Zhang FS, He QZ, Qin CH, Little PJ, Weng JP, Xu SW. Therapeutic potential of colchicine in cardiovascular medicine: a pharmacological review. *Acta Pharmacol Sin*. 2022;43(9):2173-2190. doi:10.1038/s41401-021-00835-w

7. Deftereos S, Giannopoulos G, Angelidis C, Alexopoulos N, Filippatos G, Papoutsidakis N, et al. Anti-Inflammatory Treatment With Colchicine in Acute Myocardial Infarction. *Circulation*. 2015;132(15):1395-1403. doi:10.1161/CIRCULATIONAHA.115.017611

8. Fujisue K, Sugamura K, Kurokawa H, Matsubara J, Ishii M, Izumiya Y, et al. Colchicine Improves Survival, Left Ventricular Remodeling, and Chronic Cardiac Function After Acute Myocardial Infarction. *Circulation Journal*. 2017;81(8):1174-1182. doi:10.1253/circj.CJ-16-0949

9. Westman PC, Lipinski MJ, Luger D, Waksman R, Bonow RO, Wu E, et al. Inflammation as a Driver of Adverse Left Ventricular Remodeling After Acute Myocardial Infarction. *J Am Coll Cardiol*. 2016;67(17):2050-2060. doi:10.1016/j.jacc.2016.01.073

10. Algoet M, Janssens S, Himmelreich U, Gsell W, Pusovnik M, Van den Eynde J, et al. Myocardial ischemia-reperfusion injury and the influence of inflammation. *Trends Cardiovasc Med*. 2023;33(6):357-366. doi:10.1016/j.tcm.2022.02.005

11. Tardif JC, Kouz S, Waters DD, Bertrand OF, Diaz R, Maggioni AP, et al. Efficacy and Safety of Low-Dose Colchicine after Myocardial Infarction. *New England Journal of Medicine*. 2019;381(26):2497-2505. doi:10.1056/NEJMoa1912388

12. Nidorf SM, Fiolet ATL, Mosterd A, Eikelboom JW, Schut A, Opstal TSJ, et al. Colchicine in Patients with Chronic Coronary Disease. *New England Journal of Medicine*. 2020;383(19):1838-1847. doi:10.1056/NEJMoa2021372

13. Satrijo B, Wicaksono Ashari Y, Rohman MS, Anjarwani S, Tjahjono CT. Heart Science Journal Benefits of Low Dosage of Colchicine Administration on Decreasing Rehospitalization and Mortality within 30 Days in Post-Acute Coronary Syndrome Patients with ST-Segment Elevation Undergoing Percutaneous Coronary Intervention. 2023;4(3):28-33. doi:10.21776/ub/hsj.2023.004.03.6

14. Byrne RA, Rossello X, Coughlan JJ, Barbato E, Berry C, Chieffo A, et al. 2023 ESC Guidelines for the management of acute coronary syndromes. *Eur Heart J*. 2023;44(38):3720-3826. doi:10.1093/eurheartj/ehad191

15. Hennessy T, Soh L, Bowman M, Kurup R, Schultz C, Patel S, et al. The Low Dose Colchicine after Myocardial Infarction (LoDoCo-MI) study: A pilot randomized placebo controlled trial of colchicine following acute myocardial infarction. *Am Heart J*. 2019;215:62-69. doi:10.1016/j.ahj.2019.06.003

16. Mewton N, Roubille F, Bresson D, Prieur C, Bouleti C, Bochaton T, et al. Effect of Colchicine on Myocardial Injury in Acute Myocardial Infarction. *Circulation*. 2021;144(11):859-869. doi:10.1161/CIRCULATIONAHA.121.056177

17. Leung YY, Yao Hui LL, Kraus VB. Colchicine—Update on mechanisms of action and therapeutic uses. *Semin Arthritis Rheum*. 2015;45(3):341-350. doi:10.1016/j.semarthrit.2015.06.013

18. Imazio M, Nidorf M. Colchicine and the heart. *Eur Heart J*. 2021;42(28):2745-2760. doi:10.1093/eurheartj/ehab221

19. Prabhu SD, Frangogiannis NG. The Biological Basis for Cardiac Repair After Myocardial Infarction. *Circ Res*. 2016;119(1):91-112. doi:10.1161/CIRCRESAHA.116.303577

20. Toldo S, Mezzaroma E, Mauro AG, Salloum F, Van Tassell BW, Abbate A. The Inflammasome in Myocardial Injury and Cardiac Remodeling. *Antioxid Redox Signal*. 2015;22(13):1146-1161. doi:10.1089/ars.2014.5989

21. Dixon DL, Patel J, Spence R, Talasaz AH, Abbate A, Wiggins BS. Select drug-drug interactions with colchicine and cardiovascular medications: A review. *Am Heart J*. 2022;252:42-50. doi:10.1016/j.ahj.2022.06.002

Heart Sci J 2024; 5(2): 57-63

Contents list available at www.heartscience.ub.ac.id

Heart Science Journal

Journal Homepage : www.heartscience.ub.ac.id

Original Article

The Relationship Between CHA2DS2-VASc Scores and The Degree of TIMI Flow in Patients with Acute ST-Segment Elevation Myocardial Infarction Who Underwent Primary Percutaneous Coronary Intervention at Dr. Saiful Anwar Malang

Muhammad Bayu Aji Saputra Sudarno[1*], Sasmojo Widito[2], Setyasih Anjarwani[2], Novi Kurnianingsih[2], Evit Ruspiono[3]

[1]Brawijaya Cardiovascular Research Center, Department of Cardiology and Vascular Medicine, Faculty of Medicine, Universitas Brawijaya, Malang, Indonesia.
[2]Department of Cardiology and Vascular Medicine, Faculty of Medicine, Universitas Brawijaya, Malang, Indonesia.
[3]Department of Cardiology and Vascular Medicine, Iskak General Hospital, Tulung Agung, Indonesia.

ARTICLE INFO

Keyword :
Acute Coronary Syndrome;
CHA2DS2-VASc Score;
Intervention;
Percutaneous Coronary
Slow Flow- No Reflow Phenomena;
TIMI Flow Degree.

ABSTRACT

Background: Suboptimal reperfusion of the compromised myocardium in the area of the culprit coronary arteries is one of the main problems associated with primary PCI that need reliable risk stratification methods to accurately predict the occurrence of decreased TIMI flow given its complex pathophysiology. Some parameters are included CHA2DS2-VASc score.
Objective: To understand the relationship between CHA2DS2-VASc and the decreased TIMI flow in STE-ACS patients who had underwent primary PCI at RSUD dr. Saiful Anwar Malang.
Material and Methods: The study was cohort retrospective with the inclusion criteria being all STE-ACS patients who underwent primary PCI in RSUD Dr. Saiful Anwar Malang from January 2018 – August 2023. Patients were assigned to TIMI flow grade <3 group (N =169) and TIMI flow grade 3 (N = 677) according to TIMI Flow degree after primary PCI. All the patient's angiogram were evaluated for TIMI score and CHA2DS2-VASc score is based on a guideline. We concluded data in SPSS program and used the Spearman test and p value of .05 was considered as significant.
Result: From a total sample of 846 patients, the correlation between STE-ACS onset and TIMI flow indicates that a higher number of patients with STE-ACS onset <12 hours was found in the TIMI flow <3 and 3 groups (p=0.000). The cutoff CHA2DS2 VASC score's sensitivity and specificity values were ascertained using ROC analysis with cut off value 2.5. The incidence of decreased TIMI flow rate was more significant in the CHA2DS2-VASc ≥3 group with DM (+) and age ≥64 (OR value 0.156, p=0.000) than in the CHA2DS2-VASc ≥3 group without DM and age < 64. With an OR value of 2.94 (p=0.000), Killip class > 2 is another powerful predictor of lower TIMI flow.
Conclusion: The only variables in the CHA2DS2-VASc score component that are most strongly associated with the risk of reducing the degree of TIMI flow are DM, age, and Killip class.

1. Introduction

Acute Myocardial Infarction (AMI) is a disruption of blood flow to the heart which causes the death of heart muscle cells. A heart attack occurs when an area of the surrounding muscle does not receive blood perfusion or the perfusion is so low that it cannot maintain heart muscle function. Blood flow in the blood vessels stops after acute coronary occlusion, except for a small amount of collateral flow from the surrounding blood vessels. ST segment elevation Acute Coronary Syndrome (STE-ACS) is part of the spectrum of acute coronary syndromes (ACS) consisting of unstable angina pectoris, STE-ACS, and non-ST segment elevation ACS (NSTE-ACS).[1–3]

Mortality rate due to heart disease can be increased during or after hospitalization. Some patients can die within two hours, but some survive up to a month after revascularization. Based on ACS registration data from various countries, the intra-hospital mortality rate in STE-ACS patients is 7.1% in RO-STEMI, 6.9% in AMIS-Plus-Swiss Registry, 7% in the EURO and GRACE Heart Survey registries, 10.6% in the Myocardial Infarction National Audit Project (MINAP) registries and 14% in the DENMARK registries.[4–8]

Suboptimal reperfusion of the compromised myocardium in the area of the culprit coronary arteries is one of the main problems associated with primary PCI. Approximately 5–15% of STE-ACS cases

* Corresponding author at: Brawijaya Cardiovascular Research Center, Department of Cardiology and Vascular Medicine, Faculty of Medicine, Universitas Brawijaya, Malang, Indonesia.
E-mail address: bayulaut20@gmail.com (M.B.A.S. Sudarno).

https://doi.org/10.21776/ub/hsj.2024.005.02.10
Received 3 November 2023; Received in revised form 6 November 2023; Accepted 6 November 2023
Available online 28 April 2024

undergoing primary PCI experience no-reflow phenomenon. The no-reflow phenomenon is described as failure of myocardial reperfusion in areas experiencing prolonged ischemia even though reopening of the infarct-related coronary artery (IRA) has been performed via primary PCI, which classified to TIMI flow 0 after PCI. The no-reflow phenomenon portends a poor short-term and long-term prognosis. STE-ACS patients who experience no-reflow after primary PCI have a high risk of malignant arrhythmias, re-infarction, mechanical complications (ventricular septal rupture, severe mitral regurgitation or even left ventricular wall rupture) and acute heart failure. This is associated with a high risk of death within 30 days in patients with no-reflow. [4,9–13]

There is a need for reliable risk stratification methods that accurately predict the occurrence of no-reflow given its complex pathophysiology. Some parameters included in the CHA2DS 2 -VASc score, such as congestive heart failure, hypertension, and diabetes are closely related to microvascular dysfunction and no reflow phenomenon. From several previous studies, no research has been found regarding the CHA2DS2-VASc score as a predictor factor for the occurrence of no-reflow phenomenon in STE-ACS patients in Indonesia.[14–16] In this regard, researchers conducted further studies to understand the relationship between CHA2DS2-VASc and the no-reflow phenomenon in STE-ACS patients who had underwent primary PCI at RSUD dr. Saiful Anwar Malang.

2. Material and Methods

The population in this study were patients with STE-ACS who had undergone PCI at RSUD dr. Saiful Anwar Malang from January 2018 – August 2023. The sample was carried out by consecutive sampling who met the selection criteria in the period January 2018-August 2023 were sequentially included in the research sample. Data were obtained from the ACS registry to determine the sample to meet inclusion and exclusion criteria. The inclusion criteria were all patients with STE-ACS who underwent PCI patients and have complete medical record data (laboratory and echocardiography). Exclusion criteria were patients who are not willing to be included in this study, Incomplete data, the patient was admitted with a diagnosis of sepsis upon admission, patients with malignancy or other terminal illnesses, STE-ACS who undergo fibrinolytics only without PCI, patients with idiopathic cardiomyopathy, congenital heart disease, heart valve disease, autoimmune disease or rheumatic heart disease, malignancy, severe kidney and liver dysfunction or other uncontrollable systemic diseases. (septic pneumonia) and patients whose data are not completed.

Finally, a total of 846 patients were included in this investigation according to the inclusion and exclusion criteria. This study was authorized by the hospital's central institutional review board committee. Reviewing patient medical records yielded ACS registry. Patients were assigned to TIMI flow grade <3 group (N =169) and TIMI flow grade 3 (N = 677) group according to TIMI Flow degree after primary PCI. All the patients angiogram were evaluated for TIMI score and CHA2DS2-VASc score is based on a guideline. We concluded data in SPSS program and used the Spearman test for correlation between the CHA2DS2 VASC score and TIMI Flow Degree with significant negative correlation results (p=0.000; r=-0.330) and multivariate regression analyses were entered to determine the other independent risk factors. A P value of .05 was considered as significant.

3. Results

Table. 1 Baseline Characteristic

Variable	TIMI flow grade <3 (n=169)	TIMI flow grade 3 (n=677)	*P value*
Age, median (IQR)	64 (14)	56 (14)	**0.000**[b]
Gender, n (%)			
Female	41 (27.7%)	107 (72.3%)	**0.005**[a]
Male	119 (17.3%)	570 (82.7%)	
Smoker, n(%)			
No	70 (25.7%)	202 (74.3%)	**0.001**[a]
Yes	90 (15.9%)	475 (84.1%)	
CHA2DS2-VASc score, n(%):			
1	15 (5.8%)	244 (94.2%)	**0.000**[c]
2	40 (11.1%)	320 (88.9%)	
3	64 (41.8%)	89 (58.2%)	
4	28 (60.9%)	18 (39.1%)	
5	9 (60.0%)	67 (40.0%)	
6	4 (100%)	0 (0%)	
LVEF (%), median (IQR)	43 (18)	50 (11)	**0.000**[b]
Onset STE-ACS, n(%):			
< 12 h	119 (18.4%)	527 (81.6%)	0.521[a]
> 12 h	39 (20.9%)	148 (79.1%)	
Killip class, (%):			
≤ 2	90 (13.5%)	575 (86.5%)	**0.000**[a]
3 or 4	70 (40.9%)	101 (59.1%)	
Hypertension, n(%)			
No	29 (14.6%)	364 (85.4%)	**0.001**[a]
Yes	98 (23.8%)	313 (76.2%)	
Diabetes mellitus, n(%)			
No	104 (14.9%)	592 (85.1%)	**0.000**[a]
Yes	56 (39.7%)	85 (60.3%)	
Infarct area, n(%):			
Anterior	73 (19.6%)	299 (80.4%)	0.984[c]
Inferior	34 (18.7%)	148 (81.3%)	
Posterior	2 (22.2%)	7 (77.8%)	
Lateral	0 (0.0%)	1 (100%)	
Multiple	50 (18.9%)	215 (81.1%)	

Lesion, n(%)			
1 vessel disease	26 (16.3%)	134 (83.8%)	0.361[a]
2 or 3 vessel disease	134 (19.8%)	543 (80.2%)	
Antiplatelet, n(%):			
Clopidogrel	110 (19.5%)	453 (80.5%)	0.725[a]
Tricagrelor	50 (18.2%)	224 (81.8 %)	
Total stent length, n(%):			
< 40 mm	130 (20.0%)	521 (80.0%)	0.264[a]
≥ 40 mm	29 (15.9%)	153 (84.1%)	
Stent diameter, n(%):			
≥ 3 mm	114 (19.1%)	471 (80.5%)	0.704[a]
< 3 mm	45 (18.1%)	204 (81.9%)	
Balloon inflation pressure, n(%):			
< 15 atm	73 (19.9%)	293 (80.1%)	0.653[a]
≥ 15 atm	87 (18.5%)	384 (81.5%)	
Blood sugar, mg/dl, median (IQR)	177 (161)	142 (64)	**0.000[b]**
Creatinine, mg/dl, median (IQR)	1.16 (0.83)	1 (0.49)	**0.007[b]**
HDL, mg/dl, median (IQR)	39 (16)	40 (13)	0.206[b]
Triglyceride, mg/dl, median (IQR)	169 (58)	175 (56)	0.532[b]
LDL, mg/dl, median (IQR)	116 (45)	122 (43)	0.355[b]
Leucocyte, mg/dl, median (IQR)	12790 (6480)	12160 (5670)	0.058[b]

Tabel 2. 2x2 *cut off* CHA2DS2 VASC Score

Cut Off CHA2DS2 VASC Score	TIMI flow grade		Value p	OR	CI 95%
	<3	3			
≥3	104 (47.7%)	114 (52.3%)	0.000	9.172	6.259 – 13.441
<3	56 (9.0%)	563 (91.0%)			
Total	160 (19.1%)	677 (80.9%)			

Table 3. Corelation of CHA2DS2 VASC and TIMI flow grade

Variable Independent	Variable Dependent	Sig	Coefficient Corelation (r)	Result
CHA2DS2 VASC score	TIMI flow grade	0.000	-0.402	Significant negative corelation (moderate, >0.4 – 0.6)

Table 4. Backward analysis for logistic regression

Factor				95% C.I.for EXP(B)	
	B	Sig.	Exp(B)	Lower	Upper
Age	0.025	0.031	1.025	1.002	1.048
LVEF	-0.041	0.000	0.960	0.940	0.980
Killip class	0.931	0.000	2.536	1.595	4.032
DM	1.005	0.000	2.731	1.673	4.460
CHA2DS2 VASC	1.593	0.000	4.919	3.108	7.785
Constant	-2.132	0.011			

Table 5. Confounding analysis

MODEL	Variable	Value	OR change
1. Gold Standard	CHA2DS2 VASC Score (>3) LVEF Age Killip class DM	OR 4.919 (3.108 – 7.785)	Confounding not excluded if OR change > 10%
2. Excluding LVEF model	CHA2DS2 VASC Score (>3) Age Killip class DM	OR 5.243 (3.391 – 8.108)	6.59% (<10%) LVEF excluded
3. Excluding Age model	CHA2DS2 VASC Score (>3) Killip class DM	OR 6.576 (4.401 – 9.827)	33.69% (>10%) Age not excluded
4. Excluding Killip class model	CHA2DS2 VASC Score (>3) Age DM	OR 6.141 (4.010 – 9.405)	24.84% (>10%) Killip class not excluded
5. Excluding DM model	CHA2DS2 VASC Score (>3) Age Killip class	OR 6.476 (4.238 – 9.895)	31.65% (>10%) DM not excluded
6. Final model	CHA2DS2 VASC Score (>3) LVEF Age Killip class DM	OR 5.243 (3.391 – 8.108)	LVEF, Age, Killip Class and DM are other predictors

Table 6. Final logistic regression analysis

Factor				95% C.I.for EXP(B)	
	B	Sig.	Exp(B)	Lower	Upper
Age	0.027	0.014	1.027	1.006	1.049
Killip class (3 or 4)	1.078	0.000	2.940	1.917	4.508
DM (+)	0.986	0.000	2.680	1.683	4.269
CHA2DS2 Vasc (≥3)	1.657	0.000	5.243	3.391	8.108
Constant	-4.192	0.000			

Table 7. Comparative analysis of OR for DM factors and age in patients with CHA2DS2-VASc score ≥3

Score CHA2DS2-VASc	Factor				95% C.I.for EXP(B)	
		B	Sig.	Exp(B)	Lower	Upper
≥3	DM (+) / DM (-)	0.758	0.012	2.133	1.184	3.845
	Age ≥64 (+)/(-)	1.051	0.001	2.859	1.529	5.346
	Constant	-0.860	0.001	0.423		
Score CHA2DS2-VASc	Factor				95% C.I.for EXP(B)	
		B	Sig.	Exp(B)	Lower	Upper
≥3	Age ≥64 (-) and DM (-)	-1.861	0.000	0.156	0.055	0.441
	Age ≥64 (+) or DM (+)	-1.093	0.020	0.335	0.133	0.843
	Age ≥64 (+) and DM (+) (Reff)					
	Konstanta	1.050	0.017			

Baseline Characteristic

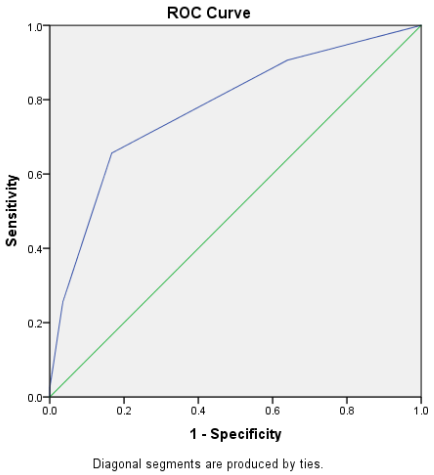

Figure 1. ROC Curve

The patient's age was highest in the TIMI flow <3 group and lowest in the TIMI flow 3 group (64 (14) vs 56 (14), p=0.000). Men are more likely than women to have TIMI grade 3, with the percentage being higher (84.1%) for men than for women (74.3%). Women predominated in TIMI grades 0–2 (27.7% vs 17.3%; p = 0.005). Individuals with hypertension were predominant in the TIMI grade <3 group (23.8% vs. 14.6%; p=0.001). The association between DM and TIMI flow revealed that DM patients predominated in the TIMI grade <3 group (39.7% vs. 14.9%) (p=0.000). Patients in TIMI grade <3 had greater blood sugar levels than those in TIMI grade 3 (177(161) vs 142 (64); p=0.000). There is a positive correlation between TIMI grade 3 and LVEF, a Kruskal-Mann Whitney analysis of non-normal data revealed a difference (p=0.000). The correlation between the CHA2DS2-VASc score and the degree of TIMI flow indicates that a TIMI flow of less than three is typically associated with a higher score (>3) in the CHA2DS2-VASc. The Kruskal Wallis test revealed a significant connection (p=0.000) (the chi square condition >2x≥2 not met).

Killip class and TIMI flow are related in that patients with Killip class ≤ 2 were more common in the TIMI grade 3 group (86.5%), while Killip class 3 or 4 was more common in the TIMI grade <3 group (40.9%) (p=0.000). In the TIMI flow < 3 group, the proportion of smokers is larger (84.1%) than that of non-smokers (74.3%) (p=0.001). Patients in TIMI grade <3 had higher creatinine levels than those in TIMI grade 3 (1.16 (0.83) vs. 1 (0.49); p=0.007). The categories of STE-ACS onset with less than 12 hours and those with more than 12 hours are known to mostly cause TIMI grade 3 (p=0.521). In comparison to TIMI grade 3, the patient's leukocyte value was greater in TIMI grade 1, however there was no significant difference (p=0.058). There was no significant difference observed between the two TIMI flow group for HDL, TG, and LDL (p>0.05).

Sensitivity and specificity of CHA2DS2-VASc score in predicting decreased TIMI flow Degree

The cutoff CHA2DS2 VASC score's sensitivity and specificity values were ascertained using ROC analysis. The results of the diagnostic test revealed an AUC value of 0.778 (77.8%), which was statistically significant at p = 0.000 (p<0.05) and regarded as rather excellent (70%-80%). The cut off value 2.5, which was rounded to 3, had a sensitivity value of 65.6% and a specificity value of 83.3% based on the findings of establishing the cutoff point.

Patients with TIMI flow <3 are dominant in CHA2DS2-VASc score ≥3 (47.7%), whereas patients with complete reflow (TIMI flow 3) are prominent in CHA2DS2-VASc score <3 (91%). The TIMI flow and the CHA2DS2-VASc cut off score were correlated (p=0.000, OR = 5.271), indicating that patients with a CHA2DS2-VASc cut off score ≥3 were more likely to experience decreased TIMI flow than those with a score <3. The degree of TIMI flow and the CHA2DS2 VASC score were found to be correlated using the Spearman correlation test. The results showed a significant negative association (p=0.000; r=-402), indicating that the degree of TIMI flow decreases as the CHA2DS2 VASC score increases.

Risk factors contributing to decreased TIMI flow grade

The bivariate test findings showed that a number of factors, including age, gender, smoking, LVEF, Killip class, hypertension, DM, stent length, GDS, creatinine, HDL, and leukocytes, had p values less than 0.25, aside from the CHA2DS2-VASc score. After that, confounding analysis will be done and all of these variables will be multivariately examined using the backward technique to create a gold standard model. The five top factors from the regression analysis utilizing the backward technique were CHA2DS2, Age, LVEF, Killip class, and DM. To determine whether these variables are independent or independent predictors, a confounding analysis was conducted. This variable can be excluded if there is a change in OR <10% in the analysis of confounding factors other than the CHA2DS2-VASc score (≥3). Following the confounding analysis, the final model resulting from the logistic regression analysis included four risk factors: age (1.027 (CI 95% 1.006 – 1.049); p=0.014), DM (OR 2.680 (CI 95% 1.683 – 4.269); p=0.000), Killip class (OR 2.940 (CI 95% 1.917 – 4.508); p=0.000), and CHA2DS2-VASc score (≥3) (OR 5.243 (CI 95% 3.391 – 8.108); p=0.000).

Age and DM risk variables had the biggest effects on the occurrence of reduced TIMI flow rate in the CHA2DS2-VASc ≥3 score group itself. Within the CHA2DS2-VASc ≥3 group, we chose to do a sub-analysis by splitting the population into two groups: DM (+)/(-) and age ≥64 (+)/(-). Following this sub-analysis, the following was discovered:

- With a p value of 0.012 and an OR of 2.133 (CI 95% 1.184 – 3.845), DM (+) is associated with a higher risk of reduced TIMI flow in STE-ACS patients with a CHA2DS2-VASc score of ≥3, as opposed to DM (-).
- Age has a value of p=0.0001 with OR 2.859 (CI 95% 1.529 – 5.346), indicating that individuals with STE-ACS who are ≥64 (+) and have a CHA2DS2-VASc score of ≥3 are more likely to see a reduction in TIMI flow than people who are younger.
- A p value of 0.020 with an OR of 0.335 (CI 95% 0.133 – 0.843) was found in STE-ACS patients with a CHA2DS2-VASc score of ≥3 and one of the risk factors (age ≥64 (+)/(-) or DM (+)/(-)). This indicates that patients with only one risk factor, age or DM, are less likely to experience decreased TIMI flow than those with age ≥64 (+) and DM (+).
- Patients with age ≥64 (-) and DM (-) who had a CHA2DS2-VASc score ≥3 in STE-ACS have a p value = 0.000 with OR 0.156 (CI 95% 0.055 – 0.441), indicating a lower risk of decreased TIMI flow compared to Age ≥64 (+) and DM (+).

4. Discussion

This study's findings indicated that the incidence of declining TIMI flow was significantly influenced by DM, aging, and Killip class. The CHA2DS2-VASc score is composed of the following components: "A" (age), "D" (diabetes mellitus), "S" (stroke), "V" (vascular disease), "Sc" (sex category), "H" (hypertension), and "C" (congestive heart failure). Apart from being determined by LVEF (left ventricular ejection fraction), the "C" component is determined by the congestive condition at presentation/Killip class. We interpret each of these components using definitions derived from the 2020 ESC guidelines. The stroke component was not included in the evaluation of the CHA2DS2-VASc score in this study since we did not include a history of stroke due to the extremely low numbers.

The components of DM, age, LVEF, Killip class, hypertension, and smoking had an impact on lowering the degree of TIMI flow in the first bivariate analysis. But only DM, age ≥64, and Killip class were the most reliable indicators of a decline in the degree of TIMI flow after we performed a multivariate analysis. DM, age and Killip components themselves are part of the CHA2DS2-VASc score. With an OR value of 5.243 (p=0.000) age ≥64 and DM were the next two best predictors, followed by a CHA2DS2-VASc score of ≥3. Based on this research, it was shown that three factors—DM and age ≥64—were more significant within the CHA2DS2-VASc score itself than other predictors. The incidence of decreased TIMI flow rate was more significant in the CHA2DS2-VASc ≥3 group with DM (+) and age ≥64 (OR value 0.156, p=0.000) than in the CHA2DS2-VASc ≥3 group without DM and age < 64. With an OR value of 2.94 (p=0.000), Killip class > 2 is another powerful predictor of lower TIMI flow.[3,9,17–20]

The slow flow-no reflow phenomenon was caused by distal thromboembolization, pre-existing microvascular disease (MVD), and individual predisposition (heart failure, hypertension, diabetes mellitus). All of the CHA2DS2-VASc Score's components have previously been applied to represent the reasons behind the no reflow phenomenon. In addition to being more likely to experience a MVD, people with a high CHA2DS2-VASc score also exhibit a higher propensity for thrombogenesis. The impairment of myocardial perfusion flow occurs when the size of the microemboli surpasses 50% of the coronary microvasculature. Moreover, under ACS situations, edema in the cardiac tissue that has suffered an infarction will cause compression of the blood vessels as well as spam, clogging, intravascular thrombus, and edema in the micro blood vessels in the infarction location. These conditions altogether are assumed to be the cause of the high slow flow-no reflow phenomena and the CHA2DS2-VASc score.[7,11–13,21,22]

To reduce the frequency of slow flow-no reflow, a few considerations can be made. The incidence of slow flow- no reflow can be decreased by using a variety of PCI procedures, including manual thrombus aspiration, defered stenting, direct stenting, and antithrombotic treatment selection. A validated score with a high predictive value and simplicity is necessary before selecting many procedures[15,16,23–26].

This article has certain restrictions. First off, selection bias was undoubtedly present because this was a retrospective, observational study. Nevertheless, to reduce the bias resulting from various baseline factors, we employed multivariate analyses. Secondly, there were some laboratory values missing from the data, like HbA1c, which could have affected the analysis's outcome. The type of stent used, the PCI method (delayed direct stenting, manual thrombus aspiration, etc.), and the comparison of TIMI flow grade before and after PCI were not included in our investigation.[27–32]

5. Conclusion

The only variables in the CHA2DS2-VASc score component that are most strongly associated with the risk of reducing the degree of TIMI flow are DM, age, and Killip class. The biggest cumulative effects on the incidence of decreased TIMI flow rate are seen in CHA2DS2-VASc score score > 3 with DM (+), age ≥ 64, and Killip class > 2.

6. Declaration

6.1 Ethics Approval and Consent to participate
The subjects in this study are humans, so ethical rules must be followed. This research has passed the ethical due diligence, approved based on the Certificate of Ethical Eligibility No. 400/244/K.3/302/2023 issued by the Health Research Ethics Committee at Dr. Saiful Anwar Malang.

6.2. Consent for publication
Not applicable.

6.3 Availibility of data and materials
Data used in our study were presented in the main text.

6.4 Competing interests
Not applicable.

6.5 Funding Source
Not applicable.

6.6 Authors contributions
Idea/concept: SW, SA, NK, ER. Design: MB, SW, SA. Control/supervision: SW, SA, NK, ER. Data collection/processing: MB, SW, SA. Analysis/interpretation: MB, SW, SA. Literature review: SW, SA, NK, ER. Writing the article: MB, SW, SA. Critical review: SW, SA, NK, ER. All authors have critically reviewed and approved the final draft and are possible for the content and similarity index of the manuscript.

6.7 Acknowledgements
We thank to Brawijaya Cardiovascular Research Center

References

1. Bonow RO, Mann DL, Zipes DP, Libby P. *Braunwald's Heart Disease e-Book: A Textbook of Cardiovascular Medicine*. Elsevier Health Sciences; 2011.
2. Thygesen K, Alpert JS, Jaffe AS, et al. Fourth universal definition of myocardial infarction (2018). *Circulation*. 2018;138(20):e618-e651.
3. Kolansky DM. Acute coronary syndromes: morbidity, mortality, and pharmacoeconomic burden. *American Journal of Managed Care*. 2009;15(2):S36.
4. Cretu DE, Udroiu CA, Stoicescu CI, Tatu-Chitoiu G, Vinereanu D. Predictors of in-hospital mortality of ST-segment elevation myocardial infarction patients undergoing interventional treatment. An analysis of data from the RO-STEMI registry. *Maedica (Bucur)*. 2015;10(4):295.
5. Byrne RA, Rossello X, Coughlan JJ, et al. 2023 ESC Guidelines for the management of acute coronary syndromes. *Eur Heart J*. Published online August 25, 2023. doi:10.1093/eurheartj/ehad191
6. Arnesen CAL, Veres K, Horváth-Puhó E, Hansen JB, Sørensen HT, Brækkan SK. Estimated lifetime risk of venous thromboembolism in men and women in a Danish nationwide cohort: impact of competing risk of death. *Eur J Epidemiol*. Published online 2022:1-9.
7. Gale CP, Manda SOM, Batin PD, Weston CF, Birkhead JS, Hall AS. Predictors of in-hospital mortality for patients admitted with ST-elevation myocardial infarction: a real-world study using the Myocardial Infarction National Audit Project (MINAP) database. *Heart*. 2008;94(11):1407-1412.
8. Kemenkes. *Riskesdas.*; 2018.
9. Huang X, Zheng W, Zhao XD, Nie SP. CHA2DS2-VASc score predicts the slow flow/no-reflow phenomenon in ST-segment elevation myocardial infarction patients with multivessel disease undergoing primary percutaneous coronary intervention. *Medicine*. 2021;100(21).
10. Henriques JPS, Zijlstra F, van 't Hof AWJ, et al. Angiographic assessment of reperfusion in acute myocardial infarction by myocardial blush grade. *Circulation*. 2003;107(16):2115-2119.
11. Hanna EB. *Practical Cardiovascular Medicine*. John Wiley & Sons; 2022.

12. Gupta S, Gupta MM. No reflow phenomenon in percutaneous coronary interventions in ST-segment elevation myocardial infarction. *Indian Heart J*. 2016;68(4):539-551.

13. De Luca G, Parodi G, Sciagrà R, et al. Preprocedural TIMI flow and infarct size in STEMI undergoing primary angioplasty. *J Thromb Thrombolysis*. 2014;38:81-86.

14. Brown E. PCI in late-presenting STEMI: how late is too late? Published online 2022.

15. Bailleul C, Aissaoui N, Cayla G, et al. Prognostic impact of prepercutaneous coronary intervention TIMI flow in patients with ST-segment and non-ST-segment elevation myocardial infarction: Results from the FAST-MI 2010 registry. *Arch Cardiovasc Dis*. 2018;111(2):101-108.

16. Bagaswoto HP, Maharani E, Setianto BY. Coronary Circulation and Hemodynamics. *ACI (Acta Cardiologia Indonesiana)*. 2016;2(1).

17. Moroni F, Azzalini L, Caixeta A, Oliveira TP, Ybarra LF. TIMI flow and myocardial blushing after rescue PCI and cardiac magnetic resonance: Results from the Myocardial Salvage After Rescue Angioplasty: Evaluation by Magnetic Resonance (SAVE-ME) study. *Int J Cardiol*. 2022;369:77-79.

18. Mahfouz RA, Gad MM, Arab M. Presence of Microvascular Dysfunction and CHA2DS2-VASc Score in Patients with ST-Segment Myocardial Infarction after Primary Percutaneous Coronary Intervention. *Pulse*. 2021;9(3-4):125-132.

19. Jaffe R, Charron T, Puley G, Dick A, Strauss BH. Microvascular obstruction and the no-reflow phenomenon after percutaneous coronary intervention. *Circulation*. 2008;117(24):3152-3156.

20. Hurst JW, Walsh RA, Fuster V, Fang JC. *Hurst's the Heart Manual of Cardiology*. McGraw-Hill; 2013.

21. Gallo G, Volpe M, Savoia C. Endothelial dysfunction in hypertension: current concepts and clinical implications. *Front Med (Lausanne)*. 2022;8:798958.

22. Ciarambino T, Crispino P, Para O, Giordano M. Gender Medicine: A New Possible Frontiers of Venous Thromboembolism. *Stresses*. 2023;3(1):167-181.

23. Ashoori A, Pourhosseini H, Ghodsi S, et al. CHA2DS2-VASc score as an independent predictor of suboptimal reperfusion and short-term mortality after primary PCI in patients with acute ST segment elevation myocardial infarction. *Medicina (B Aires)*. 2019;55(2):35.

24. Aparicio A, Cuevas J, Morís C, Martín M. Slow coronary blood flow: pathogenesis and clinical implications. *European Cardiology Review*. 2022;17.

25. Pechlivani N, Ajjan RA. Thrombosis and Vascular Inflammation in Diabetes: Mechanisms and Potential Therapeutic Targets. *Front Cardiovasc Med*. 2018;5. doi:10.3389/fcvm.2018.00001

26. Indolfi C, Torella D, Cavuto L, et al. Effects of balloon injury on neointimal hyperplasia in streptozotocin-induced diabetes and in hyperinsulinemic nondiabetic pancreatic islet-transplanted rats. *Circulation*. 2001;103(24):2980-2986. doi:10.1161/01.CIR.103.24.2980

27. Cury RC, Abbara S, Achenbach S, et al. CAD-RADS™: Coronary Artery Disease – Reporting and Data System: An Expert Consensus Document of the Society of Cardiovascular Computed Tomography (SCCT), the American College of Radiology (ACR) and the North American Society for Cardiovascular Imaging (NASCI). Endorsed by the American College of Cardiology. *Journal of the American College of Radiology*. 2016;13(12):1458-1466.e9. doi:10.1016/j.jacr.2016.04.024

28. Collet JP, Thiele H, Barbato E, et al. 2020 ESC Guidelines for the management of acute coronary syndromes in patients presenting without persistent ST-segment elevation. *Eur Heart J*. 2021;42(14):1289-1367. doi:10.1093/eurheartj/ehaa575

29. Overgaard CB, Sharma V, Hamid T, et al. Myocardial blush and microvascular reperfusion following manual thrombectomy during PCI for STEMI: insights from the TOTAL trial. *Canadian Journal of Cardiology*. 2015;31(10):S86-S87.

30. Seals DR, Jablonski KL, Donato AJ. Aging and vascular endothelial function in humans. *Clin Sci*. 2011;120(9):357-375.

31. Zhang J, Lenarczyk R, Marin F, et al. The interpretation of CHA2DS2-VASc score components in clinical practice: a joint survey by the European Heart Rhythm Association (EHRA) Scientific Initiatives Committee, the EHRA Young Electrophysiologists, the association of cardiovascular nursing and allied professionals, and the European Society of Cardiology Council on Stroke. *EP Europace*. 2021;23(2):314-322.

32. Zhang QY, Ma SM, Sun JY. New CHA2DS2-VASc-HSF score predicts the no-reflow phenomenon after primary percutaneous coronary intervention in patients with ST-segment elevation myocardial infarction. *BMC Cardiovasc Disord*. 2020;20(1):1-9.

Heart Sci J 2024; 5(2): 64-66

Contents list available at www.heartscience.ub.ac.id

Heart Science Journal

Journal Homepage : www.heartscience.ub.ac.id

Case Report

How to Recognize and Overcome Pulmonary Hypertension Crisis During Patent Ductus Arteriosus Closure by Device in Adult

Lukitasari Ayu Galuh Ardhi[1*], Heny Martini[2]

[1]Brawijaya Cardiovascular Research Center, Department of Cardiology and Vascular Medicine, Faculty of Medicine, Universitas Brawijaya, Malang, Indonesia.
[2]Department of Cardiology and Vascular Medicine, Faculty of Medicine, Universitas Brawijaya, Malang, Indonesia.

ARTICLE INFO

Keyword :
Case Report;
Congenital Heart Disease Intervention;
Patent Ductus Arteriosus;
Pulmonary Hypertension Crisis.

ABSTRACT

Background: Managing a patent ductus arteriosus (PDA) with severe pulmonary hypertension (PH) is challenging since closing the PDA can result in reduced cardiac output and right ventricular (RV) failure. The latest guideline for Adult Congenital Heart Disease (ACHD) stated it is harmful to close the defect in patients with pulmonary vascular resistance (PVR) ≤5 WU and flow ratio (FR) <1.5.
Case presentation: A 37-year-old female was referred with cough, fever, low saturation, and murmur findings. After serial examination, she was diagnosed with large PDA and severe PH her peripheral saturation (SaO_2) was 88%-89% and non-responder to acute vasoreactivity test. After a year of PH therapy, vasoreactivity showed a response to the vasoreactivity test and improved on clinical presentation with SaO_2 91%-92%. Patient fell in to PH crisis condition during the procedure of device closure, prostacyclin analogue intravenous (IV) and phosphodiesterase inhibitors inhalation was administered, and the procedure was carried on. The device was successfully implanted, and the patient had SaO_2 97% in all four extremities before discharge.
Conclusion: With established PH therapy, PDA with severe PH can underwent PDA closure by device with satisfying outcome.

1. Introduction

The main challenge in treating a large PDA is that it might cause volume and pressure overload on the pulmonary vascular bed. Although PH can be reversed with prompt shunt removal, PH may become irreversible if PDA is not identified early on. To protect the pulmonary vascular bed from prolonged pressure and volume overload and prevent Eisenmenger syndrome from developing, shunt closure is essential. When PH is both high-flow and high-resistance, closing the PDA may result in right ventricular failure and poor cardiac output which can lead to PH crisis. Closure of the defect should wait until PH treatment has been established. Device closure is the preferred methods as it has low risk of complications in most cases. One way to help during device closure procedure determine whether to move on with defect closure is to use an occlusion test before removing the device.

2. Case Report

A 37-year-old female with cough, fever, low saturation, and murmur findings. During her childhood, she had poor weight gain but was otherwise healthy. She was underweight with a Body Mass Index (BMI) of 15.6 kg/m2. Her SaO_2 was 88%-89% and blood pressure (BP) of 144/67/96 mmHg. Physical examination revealed loud and palpable second heart sound with pansystolic murmur at left infraclavicular area grade 3/6. Echocardiography showed a PDA with bidirectional shunting dominant Left (L) to Right (R) and mild tricuspid regurgitation with high probability of PH, biventricular systolic function was normal and no other anatomical anomalies were identified. Cardiac catheterization revealed a significant PH with non-responder to vasoreactivity test. It was decided not to close the PDA instead, the patient was started on medication for PH, which included sildenafil, spironolactone, and bisoprolol. After one year of medical treatment the patient's symptoms improved, especially in terms of increased tolerance to exercise. Her SaO_2 was improved to 91%-92%, and was reactive of vasoreactivity testing with 100% FiO2. (see Table 1.) She was then registered for PDA Closure by Device.

Intervention Procedure

Using femoral access with local anesthesia, measurements of intracardiac pressure and saturation was taken. Baseline Aorta (Ao) pressure before the procedure was 120/62/87 mmHg and PA pressure was 102/45/69 mmHg with PA saturation of 66% and Ao saturation of 90%. Angiography showed a large PDA Krichenko type A, with ampulla measuring 14.3 mm and the narrowest point measuring 12.1 mm. PDA Occluder Memopart (Lepu) 18-20 mm was selected. To deliver the occluder we use a 10F delivery seath and through the Amplatz wire, crossing from the PA to the descending aorta (AoD) over the PDA. As the Amplatz wire crossed the PDA, PA pressure abruptly increased to 117/54/80 mmHg, the patient complaints of shortness of breath, desaturation with SaO_2 83%, hypotension, and bradycardia. The patient fell on PH crisis and cardiac arrest. Chest compression was performed and after the return of spontaneous circulation, 100% FiO2 with non-rebreathing mask, milrinone iv and iloprost inhalation was delivered as

* Corresponding author at: Brawijaya Cardiovascular Research Center, Department of Cardiology and Vascular Medicine, Faculty of Medicine, Universitas Brawijaya, Malang, Indonesia.
E-mail address: galuhardhi@yahoo.com (L.A.G. Ardhi).

https://doi.org/10.21776/ub/hsj.2024.005.02.11
Received 19 December 2023; Received in revised form 8 January 2024; Accepted 8 January 2024.
Available online 28 April 2024

Table 1. Hemodynamic data.

Parameter	1st RHC (November 2021)	1st RHC + FiO2 100%	2nd RHC (March 2023)	2nd RHC + FiO2 100%
Hemoglobin (g/dL)	14.3	14.3	14.2	14.2
RV Pressure	145/2	138/7	104/14	N/A
LV Pressure	136/4	145/2	137/12	108/17
Art Pressure	140/67/95	138/64/96	122/61/87	113/51/79
LPA Pressure	137/59/92	135/60/87	118/55/83	107/46/68
PCWP (mean) (mmHg)	4	2	12	17
Arterial SpO2 (%)	84	97	91	97
Qp:Qs	0.58	2.83	1.1	3.0
PVR index (WU/m2)	37.4	15.3	12.3	6.7
Rp:Rs	1.46	0.34	0.47	0.2
Event during procedure	PVC and NSVT		PVC	

Art: arterial; Dia: diastolic; LV: left ventricular; LPA: left pulmonary artery; PVR index: Pulmonary vascular resistance index; PCWP: pulmonary capillary wedge pressure; RV: right ventricle; Sys: systolic; RHC: Right Heart Catheterization.

inotropic and vasodilator. The patient was stabilized with SaO_2 100%, BP 114/65/83 mHg, HR 70 bpm, and PA pressure decreasaed to 65/26/45 mmHg, the procedure was then continued. The device was successfully deployed with no residual shunt and no obstruction at the AoD after evaluation with aortography. Occlusion test was performed to ensure no negative hemodynamic side effects. As we monitored, PA Pressure was decreased to 64/24/42 mmHg below the Aorta Pressure of 129/80/99 mmHg. The patient remains stable with a SaO_2 of 91%-92% and no complaint of shortness of breath or faintness. The patient was then monitored for 2 days at the intensive cardiac unit. PH therapy was continued with milrinone iv continuous drip, iloprost inhalation 3 mcg every 4 hours, oral Sildenafile 3 x 20 mg, Beraprost 2 x 20 mg, and spironolactone 1 x 25 mg. The patient was discharged with SaO_2 of 97%, stable hemodynamics, no cyanosis, and no complaints of dyspnea or residual murmur. The patient remained asymptomatic with SaO_2 of 98%–99% at the 6-month follow-up. This result, along with the data previously discussed, supported our conclusion that, in PDA patients with severe pulmonary hypertension, device closure after established PH management can result in favorable patient outcomes.

3. Discussion

Studies have highlighted the harmful effects of PH on the mortality of ACHD. A comprehensive approach involves multiple stages of evaluation and management, integrating medical treatment, echocardiography, and invasive cardiac catheterization to address PH with a large PDA.[1-3] This approach not only assesses the safety of ductal closure but also uses medical therapy to ensure a secure PDA occlusion. Hemodynamic parameters, including PVR and ratio of the pulmonary-to-systemic flow (Qp: Qs), are also considered. In our patient's case, with a PVR ≥5 WU and Qp: Qs >1.5, a cautious individualized decision is necessary, particularly in expert centres, with a class IIb recommendation from European guidelines of ACHD 2020. Device closure is the preferred method in adults and can be safely performed with a low risk of complications in most cases, even when concurrent cardiac procedures are needed. Surgical intervention is reserved for a select few patients with ducts too large for device closure or anatomical complications like aneurysm development.[4–6] Initially, this patient exhibited no significant decrease on mPAP after vasoreactivity testing. After a year of medical intervention, the clinical presentation improved, with better tolerance to activity, SaO_2 91%, and responsive reaction to vasoreactivity testing with 100% FiO2 was noted. However, despite the success of PH medication in regulating PVR, mPAP remained systemic before the closure of the large PDA. Mortality perioperative was primarily attributed to the frequent occurrence of PH crisis. This condition arises when the mPAP suddenly exceeds the mSAP, causing abrupt pulmonary vasoconstriction, systemic hypotension, and right heart failure, potentially leading to fatal tissue hypoxia.[2,7] The development of PH crisis is associated with endothelial cell damage, systemic inflammatory response syndrome, elevated endothelin levels, and suppression of nitric oxide (NO) generation. To address acidosis and hypoxia, meticulous management of inotropes, vasopressors, adequate fluid balance, and maintaining sinus rhythm and atrioventricular synchrony are critical.[7,8] PH crisis often requires an aggressive combination of therapies for RV failure. Inhaled nitric oxide (iNO) is a standard therapy for post-operative control of PH and prevention of PH crisis. iNO is initiated at doses of 5-20 ppm, with the possibility of increasing to a maximum of 80 ppm within minutes. Its crucial to administer the lowest effective dose to minimize toxicity and gradual withdrawal from iNO are essential to enhance the utility of iNO and avoid the risk of rebound pulmonary hypertension. While iNO may have limitations, such as cost, complex delivery systems, and delays in administration during acute crises, alternative therapies should be considered.[7,9] Prostacyclin and its analogs, including alprostadil, epoprostenol, treprostinil, and iloprost, represent newer pulmonary-specific vasodilators. Iloprost, in particular, reducing the risk of systemic vasodilation by selectively targets ventilated lung segments. Inhaled iloprost may offer a favorable safety profile compared to iNO, as it can be easily administered by inhalation without requiring a complex delivery system. Another therapeutic alternative includes endothelin receptor antagonists (ERAs), which target endothelins contributing to PAH pathobiology through interactions with endothelin receptors (ETRs). [7,8]

4. Conclusion

When faced with severe PH in ACHD, a thorough assessment must be done and measurements to prevent a PH crisis must be taken. Closure of CHD shunts should be done under the umbrella of established oral PAH therapy. PH crisis usually presents with worsening of shortness of breath, cyanosis, desaturation, and hypotension or shock condition. Early recognition of this condition is paramount as well as administration of PH crisis therapy including oxygenation, addressing acidosis, adequate fluid balance, and maintenance of sinus rhythm and atrioventricular synchrony. With established PAH therapy before closure and occlusion test during the device closure procedure, satisfying outcome can be achieved.

5. Declaration

5.1 Ethics Approval and Consent to participate
Patient has provided written informed consent prior to involvement in the study.

5.2. Consent for publication
Not applicable.

5.3 Availibility of data and materials
Data used in our study were presented in the main text.

5.4 Competing interests
Not applicable.

5.5 Funding Source
Not applicable.

5.6 Authors contributions

Idea/concept: HM. Design: HM. Control/supervision: HM. Data collection/processing: LUK Analysis/interpretation: LUK. Literature review: HM. Writing the article: LUK. Critical review: HM. All authors have critically reviewed and approved the final draft and are possible for the content and similarity index of the manuscript.

5.7 Acknowledgements

We thank to Brawijaya Cardiovascular Research Center

References

1. Chiu SN, Lu CW, Lin MT, Chen CA, Wu MH, Wang JK. Pulmonary Hypertension in Adult Congenital Heart Disease in Asia: A Distinctive Feature of Complex Congenital Heart Disease. J Am Heart Assoc. 2022;11(7). doi:10.1161/JAHA.121.022596

2. Galiè N, McLaughlin V V., Rubin LJ, Simonneau G. An overview of the 6th World Symposium on Pulmonary Hypertension. In: European Respiratory Journal. Vol 53. European Respiratory Society; 2019. doi:10.1183/13993003.02148-2018

3. Zhou Z, Gu Y, Zheng H, et al. Interventional Occlusion of Large Patent Ductus Arteriosus in Adults with Severe Pulmonary Hypertension. J Clin Med. 2023;12(1). doi:10.3390/jcm12010354

4. Humbert M, Kovacs G, Hoeper MM, et al. 2022 ESC/ERS Guidelines for the diagnosis and treatment of pulmonary hypertension. Eur Heart J. 2022;43(38):3618-3731. doi:10.1093/eurheartj/ehac237

5. Baumgartner H, de Backer J, Babu-Narayan S V., et al. 2020 ESC Guidelines for the management of adult congenital heart disease. Eur Heart J. 2021;42(6):563-645. doi:10.1093/eurheartj/ehaa554

6. Niu MC, Mallory GB, Justino H, Ruiz FE, Petit CJ. Treatment of severe pulmonary hypertension in the setting of the large patent ductus arteriosus. Pediatrics. 2013;131(5). doi:10.1542/peds.2011-1417

7. Brunner N, de Jesus Perez VA, Richter A, et al. Perioperative pharmacological management of pulmonary hypertensive crisis during congenital heart surgery. Pulm Circ. 2014;4(1):10-24. doi:10.1086/674885

8. Majure DT, Greco T, Greco M, et al. Meta-analysis of randomized trials of effect of milrinone on mortality in cardiac surgery: An update. J Cardiothorac Vasc Anesth. 2013;27(2):220-229. doi:10.1053/j.jvca.2012.08.005

9. Ovaert C, Thijs D, Dewoif,' D, et al. The effect of bosentan in patients with a failing Fontan circulation. Cardiol Young. 1009;9:331-339. doi:10.1O17/S1O47951109990023

Heart Sci J 2024; 5(2): 67-71

Contents list available at www.heartscience.ub.ac.id

Heart Science Journal

Journal Homepage : www.heartscience.ub.ac.id

Case Report

Managing a Challenge Case: Transesophageal Echocardiography-Guided Transcatheter Closure of a Large Secundum Atrial Septal Defect in a Pregnant Woman

Emil Fathoni[1*], Heny Martini[2], Anna Fuji Rahimah[2], Valerinna Yogibuana Swastika Putri[2]

[1]Brawijaya Cardiovascular Research Center, Department of Cardiology and Vascular Medicine, Faculty of Medicine, Universitas Brawijaya, Malang, Indonesia.
[2]Department of Cardiology and Vascular Medicine, Faculty of Medicine, Universitas Brawijaya, Malang, Indonesia.

ARTICLE INFO

Keyword :
Atrial Septal Defect;
Pregnant Woman;
Transcatheter Closure;
Transesophageal Echocardiography.

ABSTRACT

Background: The management of complex cardiovascular conditions during pregnancy poses unique challenges, and in the case of a large secundum atrial septal defect (ASD), achieving successful closure through a transcatheter approach guided by transesophageal echocardiography (TEE) requires careful navigation and expertise. This study sought to present a case that exemplifies the contemporary approach of using TEE guidance for the closure of an ASD in pregnant women
Case presentation: A 31-year-old woman with multigravida, diagnosed with secundum ASD and pulmonary hypertension, underwent TEE. The TEE examination revealed a significant ASD measuring 2.8-3.1 cm with inadequate surrounding rims. Subsequently, our intention was to employ a device to address this defect. TEE was utilized to guide the placement of a 14F delivery sheath into the left upper pulmonary vein and left atrium. Using a catheter, we successfully deployed a 40 mm ASD Occluder (MemoPart), concluding the intervention without any complications. Given the concerns regarding the potential risks of radiation exposure and teratogenic effects on fetal development, particularly in young patients and during pregnancy, it is crucial to prioritize TEE-guided closure of ASD for the safety of both the mother and the fetus.
Conclusion: Closure of ASD with zero fluoroscopy proved to be a safe and effective procedure, demonstrating feasibility and significant benefits for pregnant women with ASD.

1. Introduction

In recent years, transcatheter closure has emerged as a well-established and widely adopted method for treating atrial septal defects (ASDs). This approach has gained popularity due to its exceptional efficacy in closing ASDs, resulting in favorable patient outcomes.[1] Notably, the procedure is associated with minimal morbidity, offering a significant advantage over traditional surgical interventions that require sternotomy. Transcatheter closure also promotes a shorter hospital stay, enabling a faster recovery and improved patient comfort.[1,2] Another noteworthy aspect is the reduced cost associated with this approach, making it a more cost-effective alternative to surgery. As a result of these compelling factors, transcatheter ASD closure has now become the preferred method of choice, replacing surgical intervention in the management of ASDs.[1,2]

The use of transcatheter closure as a treatment modality for ASDs has revolutionized the field of interventional cardiology. However, its application in specific patient populations, such as pregnant women, has been met with unique challenges and concerns. One prominent concern is the potential harm of radiation exposure to the developing fetus, which has led to a reevaluation of traditional fluoroscopy-guided procedures.[2] To address this issue, a breakthrough technique that eliminates the need for fluoroscopy has been devised, aiming to minimize radiation exposure during transcatheter ASD closure procedures. This innovative approach offers a ray of hope for pregnant women who require intervention for their ASDs, ensuring the utmost safety for both mother and child.[2] This article sought to present a compelling case study highlighting the intricate procedures involved in the transcatheter closure of a large ASD in a pregnant woman. The unique aspect of this case was the utilization of transesophageal guidance during the intervention.

2. Case Presentation

At 28-30 weeks gestational age, a 31-year-old woman with a history of multiple pregnancies sought medical attention at the outpatient clinic due to a deterioration in her breathing and the presence of swelling in her legs. These symptoms began after giving birth in July 2021 and have been accompanied by intermittent coughing since the onset of her third pregnancy. The dyspnea was exacerbated by physical activity and improved with rest and elevation. The patient has experienced exertional dyspnea since 2010 during moderate-severe activities. Upon examination, she appeared to be well compensated. Her vital signs were within normal limits, and her peripheral oxygen saturation was 99%. Auscultation revealed a normal first heart sound, a wide fixed split in the second heart sound, and accentuated P2. There were no signs of finger clubbing, and other physical findings were unremarkable. The electrocardiogram showed evidence of right ventricular hypertrophy.

* Corresponding author at: Brawijaya Cardiovascular Research Center, Department of Cardiology and Vascular Medicine, Faculty of Medicine, Universitas Brawijaya, Malang, Indonesia.
E-mail address: emilfathoni@gmail.com (E. Fathoni).

https://doi.org/10.21776/ub/hsj.2024.005.02.12
Received 9 July 2023; Received in revised form 16 July 2023; Accepted 20 July 2023.
Available online 28 April 2024

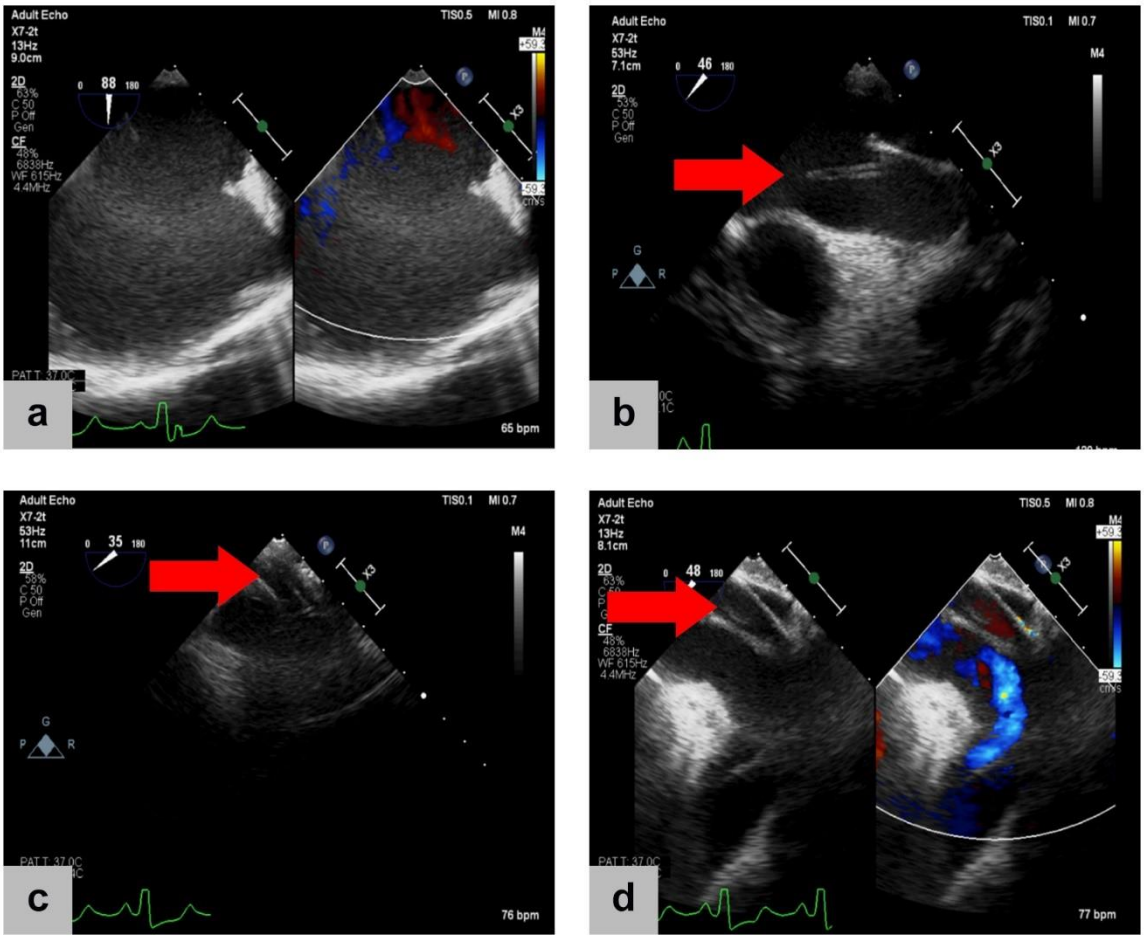

Figure 1. Catheterization MP under TEE guidance (red arrow). (a) Pre-procedural TEE showed the diameter of the secundum ASD; (b) visualization of MP catheter at SVC; (c) visualization of MP catheter at LA; (d) MP catheter was placed at LUPV, the delivery sheath was advanced to the LUPV;

TEE=transesophageal echocardiography; ASD=atrial septal defect; MP=multipurpose; SVC=superior vena cava; RA=right atrium; LUPV=Left Upper Pulmonary Vein

Transthoracic echocardiography (TEE) revealed the presence of a large secundum ASD with a left-to-right shunt, pulmonary hypertension, moderate to severe tricuspid regurgitation, and a tricuspid valve gradient of 45 mmHg. The patient was diagnosed with pulmonary hypertension, secundum ASD, and classified as NYHA functional class III heart failure. Despite receiving medical treatment for heart failure, the symptoms persisted. Consequently, it was necessary to address the issue for both the mother and the fetus. The ASD was planned to be closed using a transcatheter approach following cardiac catheterization. In order to minimize radiation exposure, we exclusively relied on TEE for a fluoroscopy-free procedure. Prior to the intervention, the patient provided informed consent, and a discussion took place involving the obstetrician and anesthesiologist.

In October 2021, a diagnostic right heart catheterization was performed to assess the cardiovascular parameters. Using an MP1 catheter, measurements were taken at various locations including the inferior vena cava (IVC), superior vena cava (SVC), right atrium (RA), left atrium (LA), right ventricle (RV), and main pulmonary artery (PA). The collected data revealed a systolic pressure of 56 mmHg in the pulmonary arteries, which accounted for more than two-thirds of the systemic pressure (82 mmHg). The flow ratio (Qp:Qs) was calculated at 2.1, indicating a moderate shunt. The pulmonary vascular resistance index was measured at 7.3 WU.m^2, and the ratio of pulmonary vascular resistance (PVR) to systemic vascular resistance (SVR) was 0.3. Additionally, an oxygen vasoreactivity test was conducted over a 10-minute period, resulting in a Qp:Qs ratio of 3.0, a pulmonary arteriolar resistance index of 2.4 WU.m^2, and a PVR/SVR ratio of 0.2.

The decision was made to proceed with transcatheter closure of the ASD using a device in the coming months. Prior to the procedure, TEE was performed, revealing an ASD diameter ranging from 2.8 to 3.1 mm with posterior rim measuring 1.0 cm, IVC rim measuring 1.1 cm, aortic rim measuring 0.8 cm, mitral rim measuring 0.8 cm, and SVC rim measuring 0.9 cm. Under general anesthesia and careful TEE monitoring (Figure 1), the patient underwent a fluoroscopy-free transcatheter closure of the ASD. The plan involved the use of a 38 mm MemoPart ASD occluder with TEE guidance (Figure 2). The procedure began with right femoral vein puncture, followed by the insertion of a 7F sheath and an MPA1 6F catheter. The MPA1 catheter was carefully guided through the right femoral vein to the left upper pulmonary vein (LUPV) and then through the ASD using TEE visualization. Subsequently, a bolus of 3000 IU intravenous heparin was administered. The MPA1 6F catheter was subsequently removed, and a 14F delivery sheath was introduced with the assistance of a 260 cm InQwire Amplatz. The InQwire Amplatz was then withdrawn. The ASD occluder, MemoPart No. 38 mm, was advanced through the 14F delivery sheath for deployment.

The occlusion device was initially positioned in the upper left PV and then deployed towards the LA side, with the intention of pulling it towards the RA. However, it was observed that the device did not open properly and instead slipped towards the RA. Subsequent TEE evaluation revealed an abnormal expansion and distorted shape of the LA disc. As a result, the decision was made to remove the device, which appeared to have a shape resembling that of a cobra. In order to proceed, it was determined that the occluder device needed to be replaced.

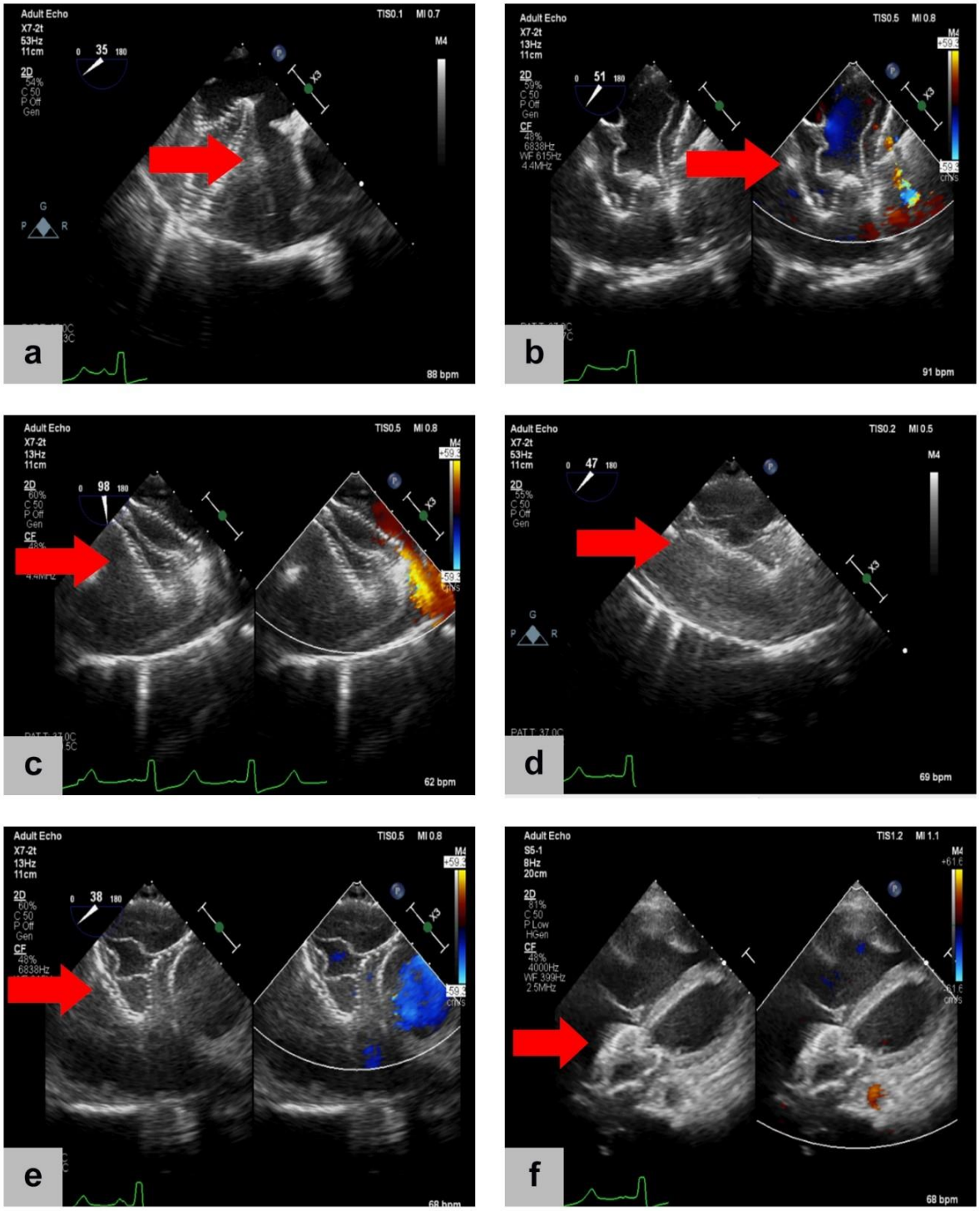

Figure 2. Transcatheter closure of ASD using TEE guidance (red arrow). (a) the device no.38 mm (MemoPart) was displaced through the defect, need repositioning; (b) after repositioning, the device was not positioned correctly (c) replace the occluder device with ASD Occluder MemoPart No. 40 mm (which was available at the time) (d) deployment the device (no residual leak or impingement on adjacent structures); (e) TEE after the procedure showed the device stowed in place; (f) no residual shunt was present.

ASD=atrial septal defect; TEE=transesophageal echocardiography.

An available ASD Occluder MemoPart No. 40 mm was selected and introduced through the 14F delivery sheath. Similar to the previous attempt, the device was positioned in the upper left PV and then expanded on the LA side before being pulled towards the RA. However, it was noted that the device slipped multiple times towards the RA during this process.

Subsequently, the decision was made to employ a catheter-assisted technique using an MPA1 6F catheter. The procedure began with a left femoral vein puncture, followed by the insertion of a 7F sheath and an MPA1 6F catheter. The MPA1 catheter was carefully advanced through the left femoral vein alongside the occluder device, reaching the upper left PV and passing through the ASD under the guidance of TEE. To address the issue of device slippage, a catheter-assisted maneuver was implemented using the MPA1 6F catheter. The catheter was skillfully maneuvered in a circular motion around the device, mimicking the shape of a balloon edge. This maneuver provided support for the device at the edge of the ASD, ensuring proper positioning and stability. Both the LA disc and RA disc of the device appeared to open correctly. Following confirmation of the device's appropriate position, a TEE evaluation was performed to assess the device's placement and detect any residual ASD. No residual defects were observed during the evaluation. Additionally, a wiggle test was conducted to ensure the secure positioning of the device without any remaining ASD. Subsequently, the MPA1 6F catheter was gently withdrawn from the LA to the RA, passing through the edge of the device. The delivery cable was unscrewed from the device. The procedure was successfully concluded at 15:30 pm, with all instruments removed, and the patient extubated. Post-procedure TEE examination confirmed that the device remained securely in place without any residual ASD or interference with neighboring structures (Figure 2).

Following the completion of the procedure, the patient was closely monitored in the observation room. The intervention lasted approximately 120 minutes, during which no significant adverse effects were observed. TTE revealed a well-positioned device with no evidence of residual interatrial shunting. Eight weeks after the closure, the patient underwent a cesarean section at 37-39 weeks of gestation, resulting in the delivery of a healthy infant weighing 2,700 grams. The infant showed no abnormalities or complications. Subsequent follow-up visits at two weeks, three and six months in both the cardiovascular and obstetric clinics indicated an improvement in the patient's symptoms and exercise capacity, as evidenced by a transition to NYHA functional class II.

3. Discussion

Over the last decade, transvenous catheter closure has emerged as the preferred approach for treating secundum ASDs. The use of fluoroscopy guidance has become the gold standard for achieving successful transcatheter implantation. It is worth noting that a median radiation dosage ranging from 5 (0.16-14.4) to 6.5 (0.24-22) millisieverts is typically administered to each patient during the closure procedure.[1] The potential risks of radiation exposure, including the development of cancer and adverse effects on fetal development, have been a significant concern, particularly among pregnant individuals. Despite receiving adequate treatment, our patient, who was currently 28-30 weeks pregnant and had a history of multiple pregnancies, continues to exhibit signs of heart failure. She experienced symptoms of dyspnea when trying to do light activities but had no signs of congestion. In order to ensure the safety of both the mother and the fetus, it is imperative to address the atrial septal defect (ASD) through appropriate treatment. A recent study by Ewert et al. demonstrated a method to reduce radiation exposure by solely relying on echocardiography for the diagnostic right heart catheterization and transcatheter closure of ASD. Out of 22 patients, 19 underwent successful procedures, and the duration of the interventions was found to be comparable to those conducted with fluoroscopy guidance (88 vs. 100 minutes; $p = 0.09$) as reported in their study.[3–5] To ensure the safety and efficacy of ASD device closure, it was crucial to have clear visualization of the catheter tip and accurate deployment of the device.

Therefore, the procedure necessitated the expertise of a trained operator experienced in transcatheter techniques, as well as the involvement of a skilled echocardiographer. Their combined proficiency was essential for achieving optimal outcomes in ASD device closure procedures..[3–5] Furthermore, there was a significant reduction in hemodynamic parameters, especially pulmonary artery pressure (PAP), following closure compared to the pre-closure measurements. This decrease aligned with expectations, as patients with untreated left-to-right shunts, such as ASDs, can develop pulmonary arterial hypertension.[5–7]

According to the clinical assessment, as well as the findings from echocardiography and cardiac catheterization, it was determined that our patient was experiencing pulmonary hypertension. The hypothesis suggested that prolonged exposure to heightened pulmonary blood flow leads to vascular remodeling and dysfunction, resulting in a gradual elevation of PVR and, subsequently, PAP. Although the precise underlying mechanisms of pulmonary arterial hypertension in ASDs are not yet fully comprehended, this theory provided a plausible explanation for the development of pulmonary arterial hypertension in these cases.[7–9] The size of the ASD directly influences pulmonary blood flow. ASDs with larger dimensions have a higher likelihood of leading to the development of pulmonary arterial hypertension. Therefore, by correcting the defect, the pulmonary blood flow can be reduced, resulting in lower PAP.[8] The observed reduction in PAP following the closure of the ASD in our patient indicated that increased flow was the contributing factor to the elevated PAP. Moreover, the subsequent increase in systemic pressure after closure suggested the presence of a significant left-to-right shunt.

Measurement of pulmonary artery pressure in this patient obtained a decrease in pressure after closure procedure. While the PAP tends to decrease from its baseline values in certain patients with pulmonary arterial hypertension following transcatheter closure of ASDs, it may still persist to some extent. This suggested that the pulmonary vasculature may have undergone permanent changes or alterations as a consequence of the condition.[8] Recent research findings indicated a significant association between the reduction in PAP following ASD closure and the severity of pulmonary arterial hypertension, younger age, and smaller defect size. During the procedure, the patient did not experience any arrhythmias resulting from the deployment of the device in the atrial chamber. Several studies have highlighted transient cardiac rhythm abnormalities and device embolization as the most commonly observed complications associated with these procedures..[1,4] Fortunately, the patient did not encounter any notable complications following the procedure, including device embolization, residual shunt, arrhythmias, pericardial effusion, cardiac chamber rupture, device displacement, or thrombosis-related problems.

The findings of this study hold several clinical implications. Firstly, the utilization of TEE guidance during transcatheter closure procedures offered a viable alternative to fluoroscopy, reducing the potential risks associated with radiation exposure, particularly in pregnant patients. This minimized the concerns related to radiation-induced complications for both the mother and the developing fetus. Secondly, the successful closure of the large ASD in this challenging case highlighted the efficacy and safety of this approach in pregnant women, further expanding the options for managing such complex cardiac conditions during pregnancy. Additionally, the improved hemodynamic parameters and symptom relief observed in the patient after the closure procedure emphasized the benefits of timely intervention in addressing ASD-related complications during pregnancy. Looking ahead, future studies were warranted to investigate long-term outcomes, evaluate the durability of the closure, and expand the knowledge on the use of TEE-guided transcatheter closure in pregnant women with large ASDs. Such research can contribute to refining the clinical protocols and enhancing patient care in this unique and challenging population.

The study had a few limitations that should be acknowledged. Firstly, the study presents a single case report, which limits the generalizability of the findings to a larger population.

Although our study provided valuable insights into the management of a specific challenging case, further research involving a larger sample size was needed to validate the results and establish broader applicability. Secondly, the study lacked long-term follow-up data, which would be valuable in assessing the durability and long-term outcomes of the transcatheter closure procedure in pregnant women with large ASD. Additionally, the study did not include a comparative group or control group, which restricts the ability to make direct comparisons with other treatment approaches or evaluate the specific benefits of TEE-guided transcatheter closure in comparison to alternative methods. Lastly, In this particular patient's situation, the presence of a significant ASD size posed technical difficulties that necessitated the use of specialized equipment and a unique balloon. However, regrettably, our hospital did not possess these specific tools. Consequently, we made modifications by utilizing a sheath and wire to adapt the equipment. This adaptation allowed us to achieve the desired positioning of the device during the procedure while minimizing the need for fluoroscopy. To ensure safety, only limited fluoroscopy was used, accompanied by abdominal shielding. Future studies addressing these limitations would help to enhance the understanding and clinical implications of this challenging case management approach.

4. Conclusion

In conclusion, the transcatheter closure of an ASD guided by TEE proves to be a feasible, safe, and effective procedure. The patient experienced improvements in both TTE findings and symptomatology during the follow-up period of one to six months. Furthermore, the patient and her baby remained in a healthy condition after several months post-procedure.

5. Declaration

5.1 Ethics Approval and Consent to participate

Patient has provided written informed consent prior to involvement in the study.

5.2. Consent for publication

Not applicable.

5.3 Availibility of data and materials

Data used in our study were presented in the main text.

5.4 Competing interests

Not applicable.

5.5 Funding Source

Not applicable.

5.6 Authors contributions

Idea/concept: EF. Design: EF. Control/supervision: HM, VY, AF. Data collection/processing: EF. Analysis/interpretation: EF. Literature review: HM, VY, AF. Writing the article: EF. Critical review: HM, VY, AF. All authors have critically reviewed and approved the final draft and are possible for the content and similarity index of the manuscript.

5.7 Acknowledgements

We thank to Brawijaya Cardiovascular Research Center

References

1. Schubert S, Kainz S, Peters B, Berger F, Ewert P. Interventional closure of atrial septal defects without fluoroscopy in adult and pediatric patients. *Clinical Research in Cardiology*. 2012;101(9):691-700. doi:10.1007/s00392-012-0445-1

2. Ewert P, Berger F, Daehnert I, et al. *Transcatheter Closure of Atrial Septal Defects Without Fluoroscopy Feasibility of a New Method*.; 2000. http://www.circulationaha.org

3. Cao H, Chen Q, Zhang GC, Chen LW, Qiu ZH, Lu H. Percutaneous device closure of atrial septal defect with totally transthoracic echocardiography guide, without x-ray machine. *Medicine (United States)*. 2016;95(44). doi:10.1097/MD.0000000000005256

4. Pan X Bin, Ou-Yang W Bin, Pang KJ, et al. Percutaneous Closure of Atrial Septal Defects under Transthoracic Echocardiography Guidance Without Fluoroscopy or Intubation in Children. *J Interv Cardiol*. 2015;28(4):390-395. doi:10.1111/joic.12214

5. Zanjani KS, Zeinaloo A, Malekan-Rad E, Kiani A, Bagheri MM. *Transcatheter Atrial Septal Defect Closure under Transthorasic Echocardiography in Children*. Vol 21.; 2011.

6. Jia Y, Meng X, Li Y, et al. Percutaneous occluder device closure through femoral vein guidance by transthoracic echocardiography in adult atrial septal defect patients. *J Thorac Dis*. 2018;10(3):1460-1467. doi:10.21037/jtd.2018.02.06

7. Yong G, Khairy P, De Guise P, et al. Pulmonary arterial hypertension in patients with transcatheter closure of secundum atrial septal defects a longitudinal study. *Circ Cardiovasc Interv*. 2009;2(5):455-462. doi:10.1161/CIRCINTERVENTIONS.108.826560

8. Acar P, Massabuau P, Elbaz M. Real-time 3D transoesophageal echocardiography for guiding Amplatzer septal occluder device deployment in an adult patient with atrial septal defect. *European Journal of Echocardiography*. 2008;9(6):822-823. doi:10.1093/ejechocard/jen178

9. D'Alto M, Mahadevan VS. Pulmonary arterial hypertension associated with congenital heart disease. *European Respiratory Review*. 2012;21(126):328-337. doi:10.1183/09059180.00004712

10. Ewert P, Daehnert I, Berger F, et al. Transcatheter closure of atrial septal defects under echocardiographic guidance without X-ray: initial experiences. *Cardiol Young*. 1999;9:136

Heart Sci J 2024; 5(2): 72-76

Contents list available at www.heartscience.ub.ac.id

Heart Science Journal

Journal Homepage : www.heartscience.ub.ac.id

Case Report

Management of Pregnant Women with Atrial Septal Defect and Pulmonary Hypertension: A Case Report

Arif Wicaksono[1*], Heny Martini[2], Ardian Rizal[2], Anna Fuji Rahimah[2]

[1]Brawijaya Cardiovascular Research Center, Department of Cardiology and Vascular Medicine, Faculty of Medicine, Universitas Brawijaya, Malang, Indonesia.
[2]Department of Cardiology and Vascular Medicine, Faculty of Medicine, Universitas Brawijaya, Malang, Indonesia.

ARTICLE INFO

Keyword :
Congenital Heart Disease;
Phosphodiesterase-5 (PDE-5)-Inhibitor;
Prostacyclin Analogue;
Pulmonary Hypertension.

ABSTRACT

Background: Pulmonary Hypertension (PH) is a condition where there is an increase in Pulmonary Vascular Resistance (PVR) and an increase in the mean Pulmonary Arterial Pressure (mPAP) to more than 20 mmHg. PH can occur in someone with Congenital Heart Disease (CHD). PH conditions can aggravate pregnancy in women with CHD. Women with PH are recommended not to undergo pregnancy. However, it is possible for women with CHD with PH conditions to undergo pregnancy. In these conditions, optimizing PH therapy is essential so that pregnant women with PH do not experience a worsening of the condition and can carry out their pregnancy well until delivery.
Case presentation: A 38-year-old female patient with a history of Atrial Septal Defect-Pulmonary Hypertension came for common control to the cardiac clinic with the pregnancy condition of her 4th child, who was just discovered when she was six months pregnant. Since giving birth to her third child, the patient began complaining of being quickly tired when doing activities accompanied by swollen legs that disappeared with rest. The patient went to a cardiologist for an echocardiography examination and was diagnosed with Atrial Septal Defect (ASD)-Pulmonary Hypertension (PH). Since then, the patient has been routinely treated by a cardiologist with Pulmonary Hypertension drugs, including Phospodiesterase5 (PDE5) inhibitors (Sildenafil) and Prostacyclin Analogue (Dorner). The patient had done Transesophageal Echocardiography (TEE) with the results of ASD secundum suitable for closure by the device. Patients with Right Heart Catheterization (RHC) results, ASD secundum with PH High Flow High Resistance reactive to Vasoreactivity Test. Since the patient was found to be pregnant, the patient continued to use Sildenafil and discontinued the use of Dorner. The patient then continued treatment in a multidisciplinary team.
Conclusion: Management of pregnant women with CHD and PH is essential because the condition of PH itself further aggravates the condition of pregnancy. Medical management for PH in pregnant women follows the guidelines for the safety of drugs in pregnancy so that the choice of therapy is crucially related to the goal of treatment to control the PH condition in the patient but still pay attention to safety in pregnancy conditions.

1. Introduction

Pulmonary hypertension is a condition that often accompanies people with Congenital Heart Disease (CHD). Women with CHD accompanied by PH are recommended not to get pregnant because pregnancy that occurs can aggravate their PH condition. In women with CHD accompanied by PH conditions who are already pregnant and want to continue their pregnancy, optimizing PH therapy is important to keep the PH condition in patients from getting worse while considering the safety of the pregnancy condition. Here we will discuss how to treat pregnant CHD-PH patients who still want to continue their pregnancy.

2. Case Presentation

A 38-year-old woman with a history of Atrial Septal Defect (ASD)-Pulmonary Hypertension (PH) came to the cardiology clinic while pregnant with her 4th child. The patient just discovered her pregnancy when she was six months pregnant. Patients with routine PH therapy received sildenafil 3 x 25 mg and Dorner 2 x 20 mg. Since it was discovered that she was pregnant, the patient is currently only continuing to use sildenafil.

Patients with a history of first, second, and third pregnancies without any complaints. After giving birth to her 3rd child, she began complaining of shortness of breath and leg swelling related to activity, and improved with rest. She went to a cardiologist and performed echocardiography with the results of Atrial Septal Defect (ASD)-Pulmonary Hypertension (PH). She had done Transesophageal Echocardiography (TEE) with the results of ASD secundum with sufficient posterior rim, sufficient Inferior Vena Cava (IVC) rim, sufficient aorta rim, sufficient mitral rim, and sufficient Superior Vena Cava (SVC) Rim. Patients with Right Heart Catheterization (RHC) results, ASD secundum with PH High Flow High Resistance reactive to Vasoreactivity Test. Patients with a history of normal growth and development. There was no history of recurrent respiratory tract infections in the patient. There was no history of breastfeeding or eating disorders in the patient. The patient claimed to be growing well, like his peers.

* Corresponding author at: Brawijaya Cardiovascular Research Center, Department of Cardiology and Vascular Medicine, Faculty of Medicine, Universitas Brawijaya, Malang, Indonesia.
E-mail address: arrifwitjaksono@gmail.com (A. Wicaksono).

https://doi.org/10.21776/ub/hsj.2024.005.02.13
Received 10 June 2023; Received in revised form 26 June 2023; Accepted 4 July 2023.
Available online 28 April 2024

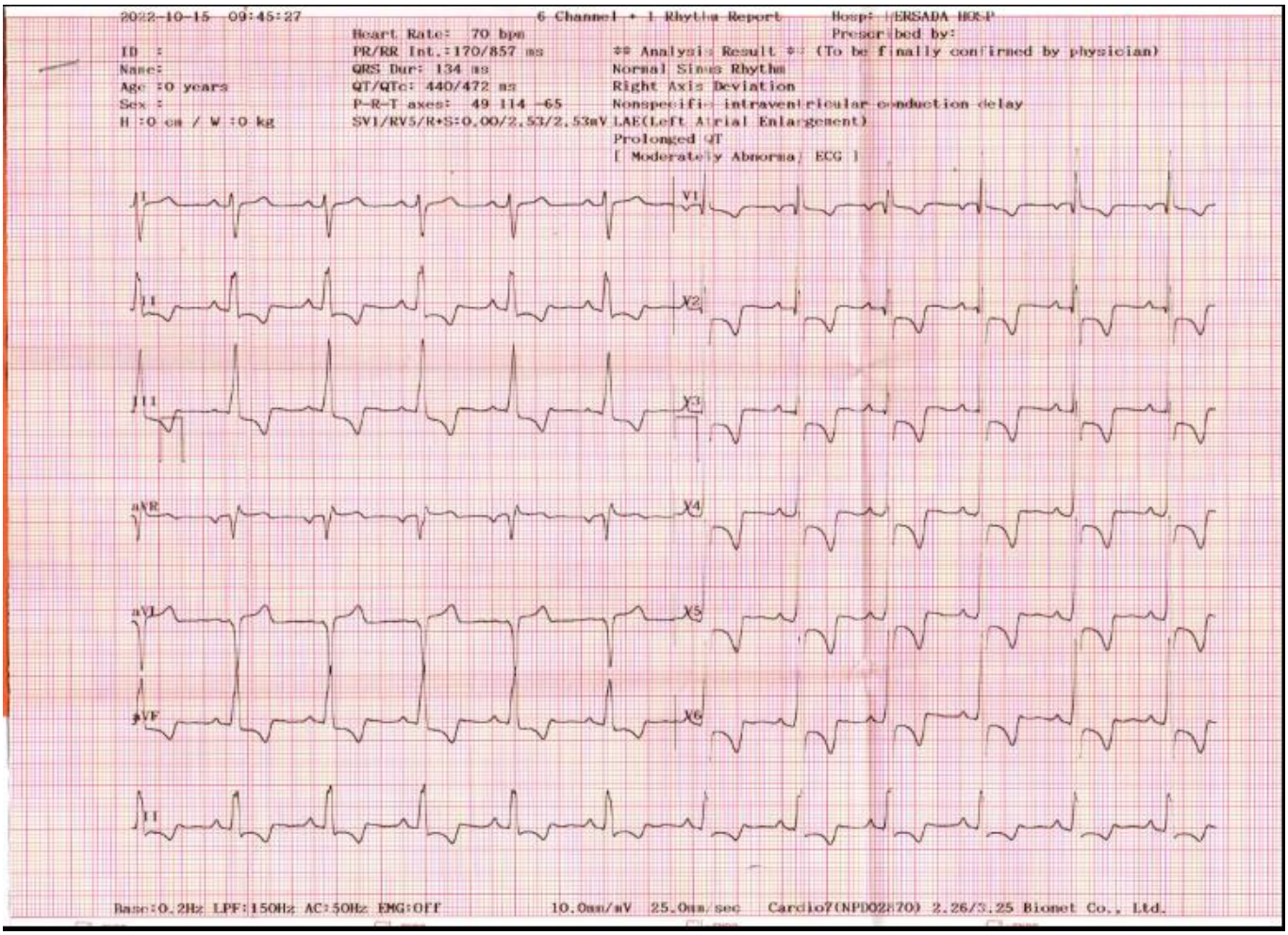

Figure 1. Electrocardiogram of the Patient

At the end of the 2nd trimester of pregnancy, she underwent transcatheter closure of the Atrial Septal Defect using zero fluoroscopies. Post-closure ASD evaluation found no residual shunt. She then continued her pregnancy with a multidisciplinary approach.

3. Discussion

Pulmonary hypertension is the term used to describe a complex multifactorial condition diagnosed based on an increase in mean pulmonary artery pressure of more than 20 mmHg through right heart catheterization. Diagnosis of PH in pregnancy is essential because it is associated with high mortality and morbidity rates.[1] One of the most prevalent acyanotic congenital heart abnormalities in patients is ASD. Possible complications include arrhythmias, pulmonary hypertension, embolic events, and right heart failure. These conditions often manifest in the fourth decade of life.8 Pregnancy-related CVA incidence rises postpartum up to 13 times, particularly during the puerperium. A recognized cause of CVA in pregnant individuals is paradoxical embolism through an atrial septal defect or a patent foramen ovale. Pregnancy-related hypercoagulation increases the risk of venous thrombosis.[2]

The total intravascular volume and cardiac output rise (30–50%) during pregnancy, among other cardiovascular alterations. Progressive dyspnea and arrhythmias during pregnancy are possible in those with significant hemodynamic abnormalities.[3] Arrhythmias (2%), as well as thromboembolic consequences, can affect pregnant women with ASD. There is a very high maternal mortality rate (up to 50%) and a very high fetal mortality rate (up to 60%) when severe pulmonary hypertension is present alongside an ASD.[3] Complications and death are related to the inability of the heart to accommodate the increased plasma volume and cardiac output, decreased systemic vascular resistance (SVR), and hypercoagulability that accompanies pregnancy. The World Heart Organization (WHO) classifies Pulmonary Arterial Hypertension with any cause as class IV and is not allowed to become pregnant.[1]

Women with PH from the start are not allowed to get pregnant. Good contraception is needed to be related to the prevention of pregnancy. The barrier method of contraception is safe but not very effective. Low-dose combination contraceptives containing ethinyloestradiol are not permitted in women with pulmonary hypertension because they are thrombogenic. Drugs containing only progesterone or dermal implants can be used in patients with PH.[4] When a woman with PH is pregnant, termination should be advised, even if the woman's condition is good. Termination of pregnancy is a high-risk procedure and should be performed in an experienced center. However, when the woman still decides to continue the pregnancy, it becomes crucial to treat this condition in a multidisciplinary team in a center that is experienced in treating PH patients.[4]

It is still unknown when a pregnant woman with PH should give birth. It's critical to balance the dangers of premature birth for the baby with the hazards of extending the pregnancy. Delivery can be scheduled at 34–36 weeks if the patient's PH is stable; however, if the patient's PH is unstable, the baby should be delivered at 32–34 weeks.[5] The Valsalva maneuver can decrease venous perfusion during vaginal birth because it raises intrathoracic pressure. Labor-induced acidosis, hypoxemia, and elevated pulmonary artery pressures might result from decreased venous perfusion brought on by vagal reflexes brought on by labor pains and increased heart rate brought on by sympathetic nervous system stimulation. Beneficial epidural analgesia ought to be

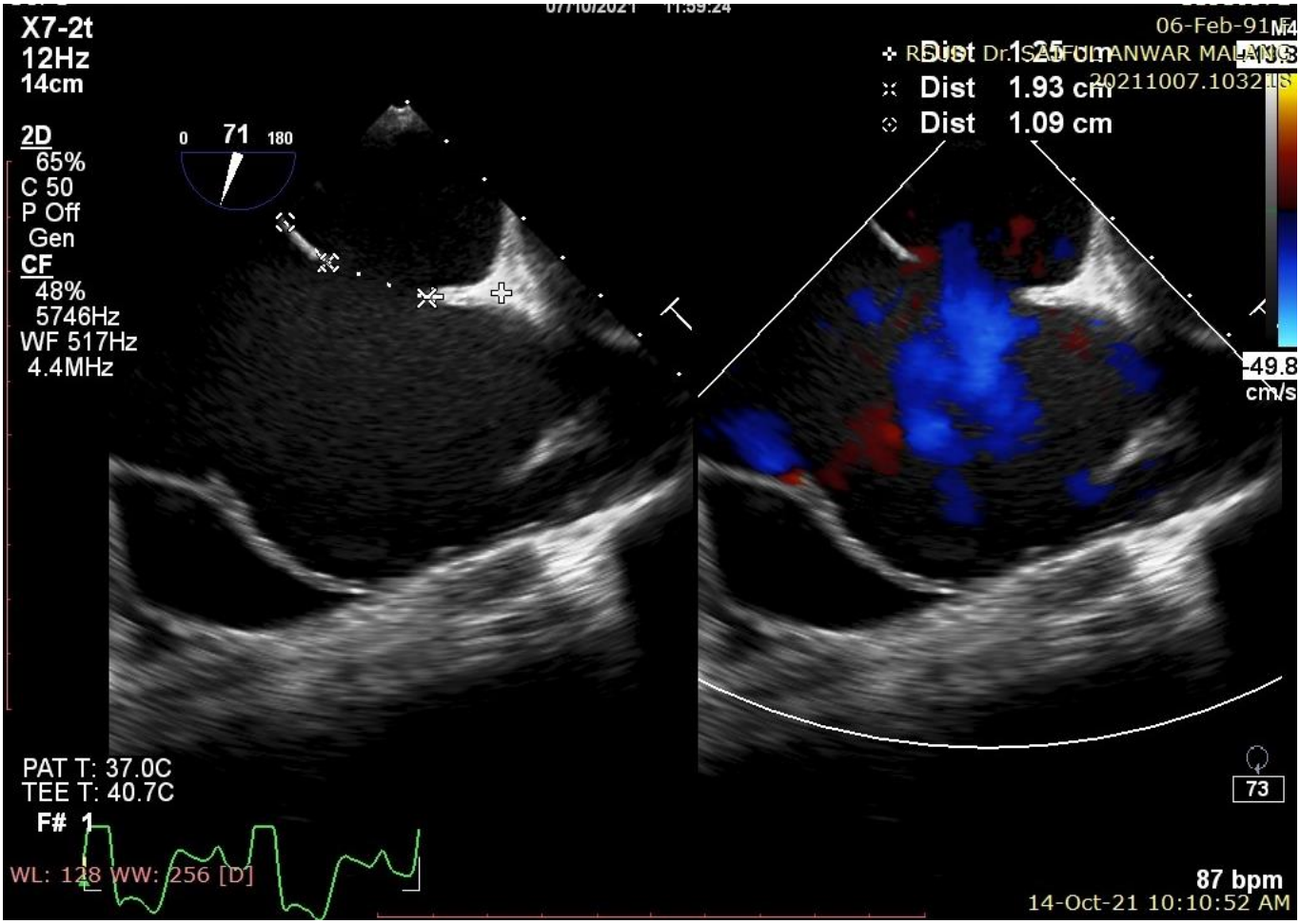

Figure 2. Transoesophageal Echocardiography of the Patient.

used. Due to the obstruction in the inferior vena cava being released after birth, there may be a fast autotransfusion of the uterus and an increase in venous perfusion. Therefore, careful blood pressure management is necessary during vaginal delivery. Because of the mother's hemodynamic status, premature birth is more likely among pregnant people with PH, and cesarean sections are frequently an option.[5]

Labor discomfort and autotransfusion related to uterine contractions in pregnant women with PH can be avoided by performing a cesarean section. In PH patients, general anesthesia significantly enhances PVR with positive pressure breathing and PAP through tracheal intubation for cesarean delivery. Low levels of breathing volume and intra-aortic pressure ought to be maintained. The anesthesiologist often employs epidural anesthesia or a combination of spinal subarachnoid anesthetics to prevent the hazards mentioned above.[5]

Parturients with congenital cardiac disease have been treated using general and regional anesthetic methods. Endotracheal intubation and GA preserve the airway. Mechanical ventilation reduces the effort required to breathe and may result in less oxygen consumption, which raises arterial oxygen content. Reduced venous return, cardiac dysfunction, compression of the pulmonary arteries, hypoxemia, hypo- or hypercarbia, and acidemia are all side effects of regulated mechanical breathing. In published cases detailing the anesthetic care of parturient women with congenital cardiac disease, crucial factors, including mode and frequency of ventilation, peak inspiratory pressure, percentage of inspired oxygen, ETCO2, and blood gas analyses, are rarely described.[6]

In parturient women with complicated cardiac defects, regional anesthetic permits spontaneous breathing with little interference to V/Q relationships. Continuous, titrated anesthetic or analgesia is available with epidural catheter procedures, and two catheters (one directed cephaloid, the other caudal) provide flexibility during delivery.[6] The neurotoxic effects of local anesthetics may be more sensitive in patients with congenital cardiac defects. Subarachnoid (spinal) anesthesia and individuals with severe heart disease have occasionally been the subject of debate. Because a quick drop in SVR worsens cyanosis by increasing right-to-left shunt, most people believe it should only very seldom, if ever, be administered to pregnant women with intracardiac shunts. The decline in venous return exacerbates cyanosis by further reducing pulmonary blood flow and encouraging preferred flow to the systemic circulation. Myocardial oxygen delivery is diminished, and mean blood pressure falls. The temptation is to add oxygen at this moment, although it would be far more suitable to boost SVR.[6]

To keep the woman awake for her delivery experience, anesthesiologists recommend neuraxial anesthesia during cesarean births rather than airway manipulation and general anesthesia. Cardiac, obstetric, or anesthetic reasons such as hemodynamic instability, concern over excessive blood loss, and contraindications to neuraxial methods may need general anesthesia.[7] The anesthesiologist must choose between a single-shot spinal, an epidural, a combination spinal epidural, a low-dose sequential combined spinal method, or a continuous spinal technique if regional anesthesia is chosen. Some cardiac abnormalities, such as severe left-heart blockage or right-to-left shunting, may be contra-indicated because of the quick drop in preload and afterload brought on by a single-shot spinal. The least circulatory disturbance is anticipated to be caused by an epidural given slowly and with the proper care. A low-dose sequential combination spinal anesthetic approach employs an incremental increase in epidural boluses after a tiny intrathecal local anesthetic dosage.

Patients with severe cardiac problems have had success with this method.[7] The anesthesiologist must use extreme caution during the beginning of neuraxial surgical or analgesic anesthesia. In patients with intravascular shunting, maintaining systemic vascular resistance is crucial to prevent inducing or aggravating pre-existing cyanosis due to increased right-to-left shunting. Maintaining uterine blood flow is crucial for the welfare of the fetus. To reduce the hemodynamic consequences of the surgical neuraxial block, try cautious intravenous hydration and/or a slow titration of phenylephrine or ephedrine. The first 48 to 72 hours following birth are the reasonable period with the most risk for women with congenital heart disease due to the abrupt return of uterine blood to the systemic circulation.[7]

Congenital heart disease is not a reason for a cesarean birth without significant aortopathy, and many expectant mothers will be permitted to labor naturally. It is crucial to understand that the care of women with congenital heart disease during the second stage of attempted vaginal birth is still debatable and that there is a lack of information to help decision-making. For parturients who are in labor and have moderate or complicated heart problems, some obstetricians conduct a "cardiac delivery." In such a birth, the baby is delivered using forceps or a vacuum and an early, thick epidural followed by a passive second stage (no pushing). By effectively controlling the discomfort, this approach prevents hemodynamic changes brought on by the mother's expulsive attempts and limits catecholamine release.[7]

Percutaneous device closure during pregnancy raises serious safety concerns regarding radiation dose exposure to the mother and fetus. To reduce the danger of radiation exposure to the growing fetus, the timing of percutaneous ASD closure is crucial. Delaying ASD closure until the second trimester's latter stages would be desirable since fetal danger would be reduced and CNS development and organogenesis would have mostly finished.[3]

Although the management of PH in pregnancy is not well documented, several case reports show some low-level evidence of the successful use of pulmonary vasodilator therapy. Many patients treated with IV epoprostenol, sildenafil, and nebulized iloprost showed positive outcomes, although data for this are limited.[8] The exact timing of initiating therapy using vasodilators remains unclear. Deterioration in PH patients with pregnancy usually appears in the 20-24th week of gestation, when hemodynamic changes appear in these weeks. If the patient's condition worsens, vasodilator therapy should be started immediately. If the therapy is given too late, the patient's outcome will be poor.[8] The development of advanced PH therapy, such as the administration of sildenafil as part of therapy, has increased functional capacity, survival rate, and improvement of symptoms in pregnancy patients with PH. However, there is no consensus regarding advanced PH therapies in pregnancy.[9] Pharmacological therapy widely used for PH patients is in the form of anticoagulation and other specific therapy related to PH. Anticoagulation using low molecular weight heparin (LMWH) or unfractionated heparin is recommended for idiopathic and hereditary PAH.[10]

Long-term treatment using high-dose calcium channel blockers (CCBs) is associated with improved hemodynamics and increased survival in patients with a positive vasodilator test. CCBs are generally tolerated during pregnancy and are not associated with teratogenic risks. Other medical therapies that focus on several pathways for the occurrence of PH include prostacyclin, endothelin receptor antagonist, phosphodiesterase type 5 inhibitors (PDE5i), and guanylate cyclase stimulators. However, among these drugs that can be used during pregnancy, only prostacyclin and PDE5i, while the rest have teratogenic effects.[10] Inhaled iloprost and intravenous Treprostinil, in combination with sildenafil, can be used in pregnancy. Sildenafil (not tadalafil) has shown promising efficacy in some cases when combined with prostaglandins.[10] Sildenafil works by inhibiting the degradation of the second messenger cyclic guanosine 3', 5'-monophosphate by the enzyme PDE-5. An increase in nitric oxide production results in smooth muscle relaxation and increased vasodilation. The vasodilatory effect of sildenafil is also manifested in the uterine and myometrial vessels, resulting in increased uterine flow.[11]

A multidisciplinary team should treat pregnant women with ASD-PH of obstetricians, anesthetists, physicians with a specialist interest and knowledge in PH, and hematologists. Pregnant women with PH should have regular check-ups at a PH specialist clinic at least once a month and evaluate with 2D echocardiography.[12]

4. Conclusion

Pregnancy in women with congenital heart disease and pulmonary hypertension is of concern because the condition of pregnancy that occurs can exacerbate PH conditions in patients. Drugs of PH that can be used for pregnant women is Phospodiesterase-5 inhibitors (sildenafil). Optimizing the use of sildenafil in treating PH with pregnancy becomes important in pregnant patients with PH who still want to continue their pregnancy. Sildenafil, apart from being a PH drug, also has the effect of increased uterine flow. Timing of Atrial Septal Defect closure with PH in pregnant patients is also important. After closure is done at the right time, delivery is planned by considering the mother's cardiac condition and the fetus's condition.

5. Declaration

5.1 Ethics Approval and Consent to participate
Patient has provided written informed consent prior to involvement in the study.

5.2. Consent for publication
Not applicable.

5.3 Availibility of data and materials
Data used in our study were presented in the main text.

5.4 Competing interests
Not applicable.

5.5 Funding Source
Not applicable.

5.6 Authors contributions
Idea/concept: AW Design: AW. Control/supervision: HM, AR, AF. Data collection/processing: HM Analysis/interpretation: HM. Literature review: HM. Writing the article: AW. Critical review: HM, AR, AF. All authors have critically reviewed and approved the final draft and are possible for the content and similarity index of the manuscript.

5.7 Acknowledgements
We thank to Brawijaya Cardiovascular Research Center

References

1. Martin SR, Edwards A. Pulmonary Hypertension and Pregnancy. *Obstetrics and Gynecology*. 2019;134(5):974-987. doi:10.1097/AOG.0000000000003549

2. E.A. Orchard, N. Wilson, O.J.M. Ormerod. Device closure of atrial septal defect during pregnancy for recurrent cerebrovascular accidents. *INTERNATIONAL JOURNAL OF CARDIOLOGY* . Published online 2009:241-242.

3. Stokes MB, Xu B, Nerlekar N, Lockwood SM, Harper RW. Successful percutaneous closure of an extremely large secundum atrial septal defect during pregnancy. *Cardiovasc Diagn Ther*. 2017;7(3):336-339. doi:10.21037/cdt.2016.10.03

4. Pieper PG, Hoendermis ES. Pregnancy in women with pulmonary hypertension. *Netherlands Heart Journal*. 2011;19(12):504-508. doi:10.1007/s12471-011-0219-9

5. Sakurako Mishima, Takashi Mitsui, Satoshi Akagi, Tomohiro Mitoma. Pregnant Woman With Severe Pulmonary Hypertension Due to an Atrial Septal Defect That Was Triggered by Pregnancy. *Res Sq*. Published online February 7, 2022. doi:https://doi.org/10.21203/rs.3.rs-1206711/v1

6. Luthra A, Bajaj R, Jafra A, Jangra K, Arya VK. Anesthesia in pregnancy with heart disease. *Saudi J Anaesth*. 2017;11(4):454-471. doi:10.4103/sja.SJA_277_17

7. Fernandes SM, Arendt KW, Landzberg MJ, Economy KE, Khairy P. Pregnant women with congenital heart disease: Cardiac, anesthetic and obstetrical implications. *Expert Rev Cardiovasc Ther*. 2010;8(3):439-448. doi:10.1586/erc.09.179

8. Huang S, DeSantis ERH. Treatment of pulmonary arterial hypertension in pregnancy. *American Journal of Health-System Pharmacy*. 2007;64(18):1922-1926. doi:10.2146/ajhp060391

9. RA Curry, C Fletcher, E Gelson, MA Gatzoulis, M Woolnough. Pulmonary hypertension and pregnancy—a review of 12 pregnancies in nine women. *An International Journal of Obstetric and Gynaecology*. Published online March 6, 2012.

10. Afify H, Kong A, Bernal J, Elgendy IY. Pulmonary Hypertension in Pregnancy: Challenges and Solutions. *Integr Blood Press Control*. 2022;15:33-41. doi:10.2147/IBPC.S242242

11. Dunn L, Greer R, Flenady V, Kumar S. Sildenafil in Pregnancy: A Systematic Review of Maternal Tolerance and Obstetric and Perinatal Outcomes. *Fetal Diagn Ther*. 2017;41(2):81-88. doi:10.1159/000453062

12. Madden BP. Pulmonary hypertension and pregnancy. *Int J Obstet Anesth*. 2009;18(2):156-164. doi:10.1016/j.ijoa.2008.10.006

Heart Sci J 2024; 5(2): 77-81

Contents list available at www.heartscience.ub.ac.id

Heart Science Journal

Journal Homepage : www.heartscience.ub.ac.id

Case Report

Navigating Complex Cardiovascular Pathologies: A Case Report on Aortic Arch Replacement in a Middle-Aged Male with Stanford A De Bakery I Aortic Dissection

Muhammad Firdaus[1*], Saskia Dyah Handari[2,4], Yan Efrata Sembiring[3,4]

[1]Brawijaya Cardiovascular Research Center, Department of Cardiology and Vascular Medicine, Faculty of Medicine, Universitas Brawijaya, Malang, Indonesia.
[2]Department of Cardiology and Vascular Medicine, Faculty of Medicine, Universitas Brawijaya, Malang, Indonesia.
[3]Department of Thoraric Cardiac and Vascular Surgery, Faculty of Medicine, Airlangga University, Surabaya, Indonesia.
[4]Premier Hospital, Surabaya Indonesia.

ARTICLE INFO

Keyword :
Aortic Dissection;
Dissection Flap;
Total Aortic Arch Replacement.

ABSTRACT

Background: Aorta dissection is characterized by the presence of an intimal tear, which permits the passage of blood through the tear and into the aorta media. This process leads to the separation of the intimal and the formation of a dissection flap, representing the true lumen and a newly formed false lumens. The incidence of aortic dissection varies between 0.2% and 0.8%. Management of acute aortic standford A aortic dissection primarily involves invasive surgical procedures.
Case presentation: A middle-aged male patient, aged 40, who possesses risk factors including uncontrolled hypertension and obesity, arrived to the emergency room with symptoms of chest pain. He described the pain as tearing in nature and said that it radiated towards the abdominal. The examination findings included a blood pressure reading of 255/143, a widened mediastinum and cardiomegaly observed on the chest X-ray, a slight elevation in Hs-Troponin levels, and the presence of sinus rhythm with left ventricular hypertrophy. He underwent CT scan, which demonstrated the presence of an aortic dissection extending from the ascending to descending aorta, with no associated damage to the aortic valve from echocardiography. He was diagnosed with Standford A DeBakey I Aortic dissection and underwent preference replacement of the aortic arch and elephant trunk implantation instead of Bentall procedure.
Conclusion: The surgical and perioperative methods employed may differ based on the specific clinical presentation and the nature of the aortic disease. Because there was no involvement of the aortic valve, we performed total aortic arch replacement and elephant trunk procedure over the Bentall procedure.

1. Introduction

Acute aortic dissection is a rare and extremely dangerous condition that affects the aorta, resulting in significant morbidity and mortality. Acute type A aortic dissection (ATAAD) is commonly acknowledged as the most lethal variant of dissection, predominantly impacting the ascending aorta. Aortic dissection is distinguished by the existence of an intimal tear, which allows blood to flow past the tear and into the media layer of the aorta. This phenomenon induces the detachment of the intima layer and the subsequent creation of a dissection flap, leading to the separation of the genuine lumen from a recently developed pseudo lumen. Aortic dissection has been associated with a range of underlying medical conditions that increase the risk, including genetic disorders, inflammatory vasculitides, as well as other risks such as pregnancy, trauma, history of cardiac surgery, stimulant misuse, and infection.[1–3]

ATAAD accounts for roughly 58-62% of the total occurrences of aortic dissections. The case-fatality rate of acute type A aortic dissection ATAAD is reported to be 73%, with over half of all deaths happening prior to arrival at a healthcare facility. Historical records indicate that the prevalence of ATAAD has been shown to range from 2.5 to 6 occurrences per 100,000 patient years.Approximately two-thirds of instances involving aortic dissections are observed in males.[1,3]

Aortic dissection presents with a wide range of symptoms, which are dependent on the underlying pathophysiological disruption. The primary presentation of an aortic dissection is characterized by the notable development of severe and sudden pain centered in the thorax, dorsal region, or abdominal region. Imaging modalities are of paramount importance in the diagnostic evaluation of aortic diseases, as they provide valuable information regarding the precise anatomical location, size, shape, and extent of pathological abnormalities affecting the aorta. The categorization of aortic dissection management is determined on the precise anatomical location of the condition. Type A necessitates surgical intervention, whereas type B, despite its intricate nature, can be efficiently addressed with pharmacological therapy.[3]

Total Aortic Arch Replacement is a surgical intervention that entails the complete substitution of the aortic arch, which refers to the

* Corresponding author at: Brawijaya Cardiovascular Research Center, Department of Cardiology and Vascular Medicine, Faculty of Medicine, Universitas Brawijaya, Malang, Indonesia.
E-mail address: muhfirdaus.dr@gmail.com (M. Firdaus).

https://doi.org/10.21776/ub/hsj.2024.005.01.8
Received 2 November 2023; Received in revised form 10 November 2023; Accepted 26 November 2023.
Available online 28 April 2024

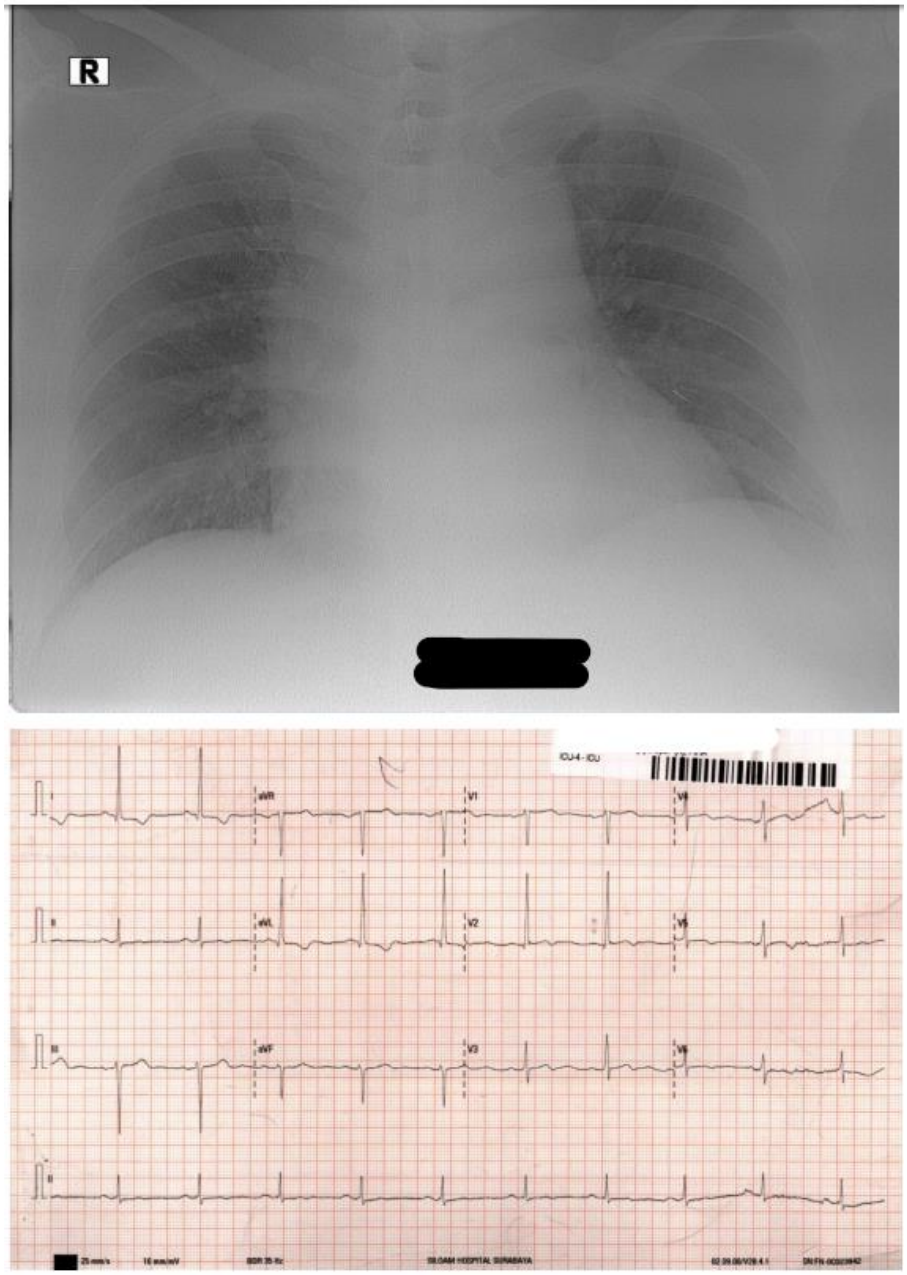

Figure 1. ECG and chest X-ray at initial presentation. Cardiomegaly and mediastinum enlargement were seen on the CXR. The ST-T wave on the ECG was non-specific.

curved segment of the aorta extending from the heart. This operation is commonly conducted to address various diseases, including as aneurysms, dissections, and other anomalies affecting the aorta.[4] This case report aims to elucidate the decision-making process for managing cases of aortic dissection.

2. Case Presentation

A middle-aged male, aged 40, who possesses risk factors including uncontrolled hypertension for a duration exceeding 10 years and obesity classified as class III with a body mass index (BMI) of 50.8 kg/m2, arrived at the emergency department with symptoms of abrupt chest pain. The pain was characterized as tearing in nature and extended to the abdominal region. The patient's physical findings included a blood pressure reading of 255/143, a widened mediastinum and cardiomegaly observed on chest X-ray, a small elevation in Hs-Troponin levels, and an electrocardiogram showing sinus rhythm with left ventricular hypertrophy. Based on the findings obtained from the anamnesis, physical examination, and supportive examination, medical professionals maintain a degree of uncertainty regarding the diagnosis of ACS. Consequently, they proceed to conduct CT scans as a triple rule out procedure on the aforementioned patient. The CT scans revealed a series of aortic dissections extending from the ascending to the descending aorta, with no apparent impact on the aortic valve from echocardiography. The individual received a medical diagnosis of Stanford A DeBakey I aortic dissection. Subsequently, the patient has a surgical intervention involving open heart surgery, resulting in a successful replacement of the entire aortic arch and conventional elephant trunk.

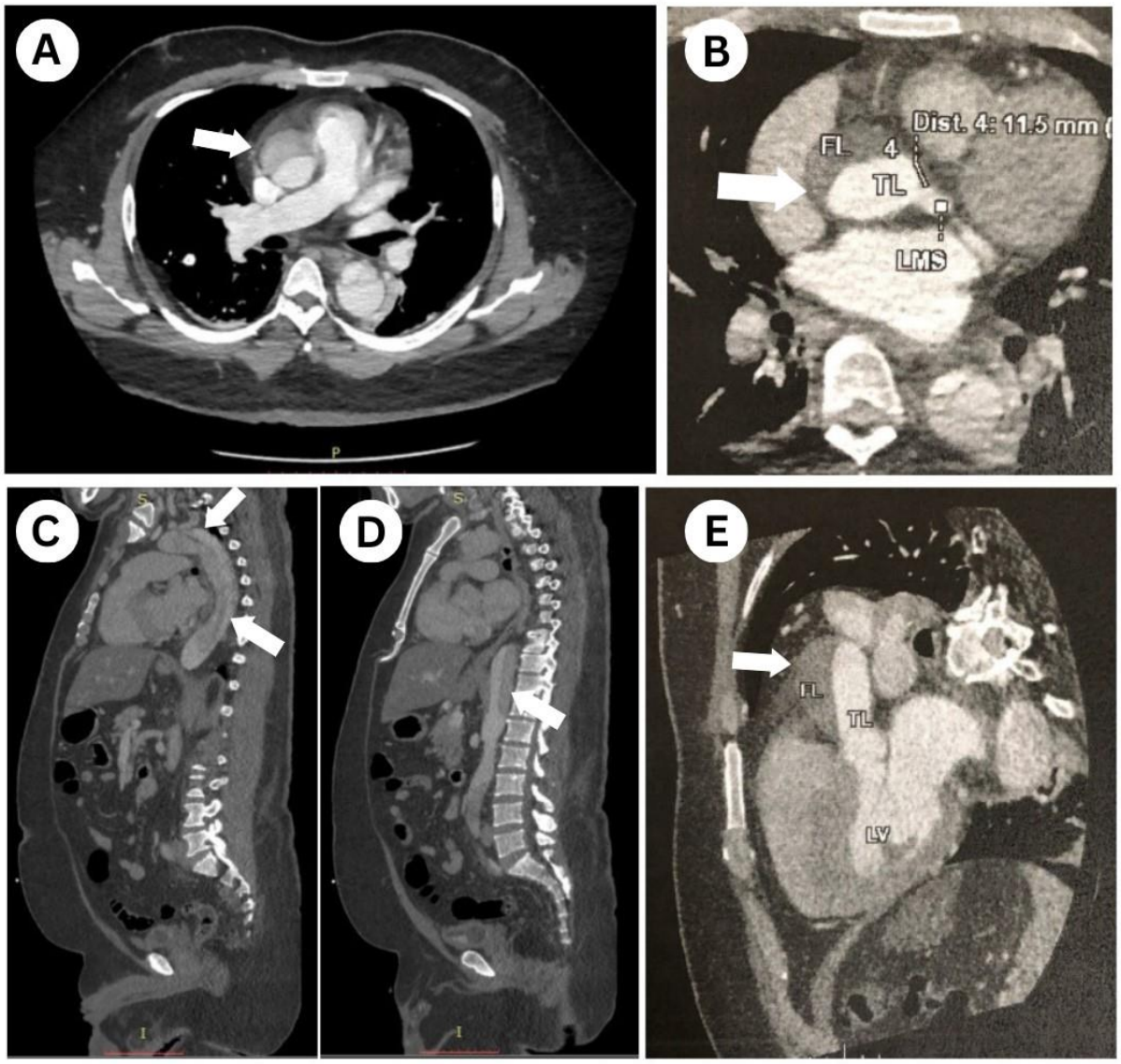

Figure 2. Image A and B (axial view CT scan) depict an intimal flap inside the ascending aorta, causing a division of the lumen into two separate spaces: the true lumen and the false lumen. The true lumen appears with a more intense coloration. Image C (sagittal view) revealed an intimal tear located at the arcus aorta, specifically following the left subclavia artery sinistra. Image D (sagittal view CT scan) clearly depicts the intimal flap at the descending aorta level and the artificial lumen. Image E (coronal view) displays an intimal flap located at the ascending aorta, which separates the inner space into two sections: a true lumen and a false lumen. However, the aortic root remains unaffected by this condition. These CT scan results indicate that the patient has a Stanford A DeBakey I aortic dissection.

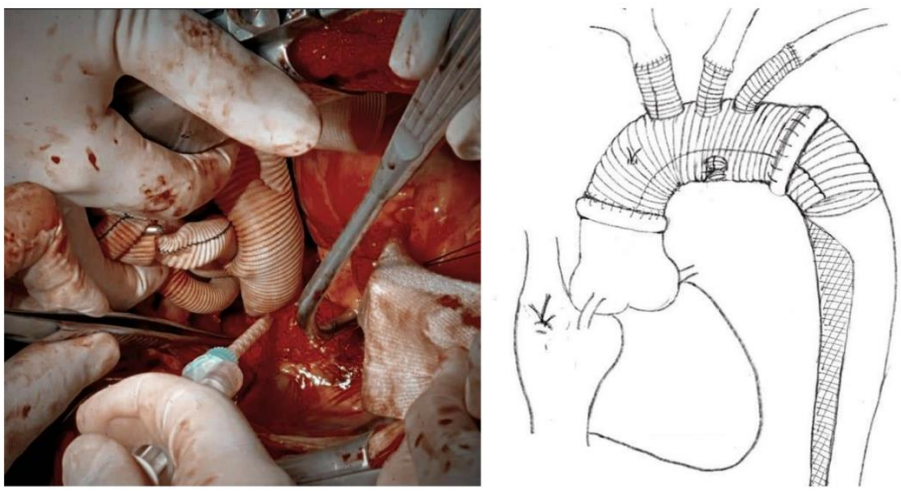

Figure 3. Total arch aortic replacement with elephant trunk procedure to manage patient with aortic dissection standford A DeBakey I

3. Discussion

Aorta dissection is characterized by the presence of an intimal tear, which permits the passage of blood through the tear and into the aorta media. This results in the longitudinal splitting of the intima, leading to the formation of a dissection flap that separates the genuine lumen from a newly formed false lumen. The dissection flap has the potential to propagate either in an antegrade or retrograde manner, giving rise to several severe consequences that can endanger the patient's life. These problems encompass acute aortic regurgitation, myocardial ischemia, cardiac tamponade, acute stroke, and malperfusion syndromes.[5] In this case, CT scan showed intimal tears and false lumen at level aortic ascending and descending without aortic regurgitation finding from physical examination and echocardiography.

Establishing the incidence of aortic dissection is difficult as many patients (18% to 49%) die before the condition is recognized. Population studies estimate the incidence of acute aortic syndrome to range from 2.6 to 7.7 cases per 100,000 person- years, with 15 cases per 100,000 in the middle- aged. Acute aortic dissection has a very high early mortality, with up to a 1% per hour death rate in the first hours after acute type A dissection. Type A aortic dissection occurs most commonly in individuals between 50 and 60 years of age, and type B dissection at a peak of 60 to 70 years of age. The occurrence of aortic dissections in men accounts for around two-thirds of cases.[1,3] In accordance with existing epidemiological data, this case occurs in men with a greater prevalence than women and happened in a younger age than usual.

The most commonly reported symptom of acute aortic dissection is chest discomfort. The most characteristic presentation is the sudden onset of intense chest and/or back pain. The pain experienced in this context has characteristics such as sharpness, ripping, tearing, and knife-like sensations, which distinguish it from other forms of chest pain. Notably, the suddenness with which it manifests is the most distinctive feature. The chest is the predominant location of pain, reported by almost 80% of individuals, but back discomfort and stomach pain are encountered by 40% and 25% of patients, respectively. The sensation of pain has the potential to relocate from its initial location to various other areas, tracing the course of dissection as it progresses along the aorta. In the study conducted on IRAD, it was noted that 15% of patients diagnosed with acute Type A AD had migrating pain, while around 20% of patients with acute Type B AD experienced the same symptom.[6] in accordance with existing theory, the clinical presentation of this patient that made him come to the emergency room was abrupt tearing chest pain radiating to abdominal.

The use of chest x-ray is customary in individuals who exhibit symptoms of chest pain. The radiographic features commonly observed in acute type A aortic dissection (ATAAD) often involve the enlargement of the mediastinum or aortic knob. Interestingly, it has been shown that more than 20% of patients diagnosed with AAD do not exhibit any abnormalities in the mediastinum or aortic contour. This phenomenon is more prone to manifest in people who have a dissection involving a nondilated aorta. The observation of a pleural effusion, which lacked specificity, was notably observed in individuals with prolonged durations till diagnosis.[7]

The electrocardiogram (ECG) is a standard diagnostic procedure that is commonly conducted when individuals exhibit symptoms of chest pain. The data indicates that 30% of individuals exhibit aberrant findings when an ECG displays irregularities, which can be attributed to hypertensive alterations, compromised coronary ostia, or underlying coronary artery disease. Within the IRAD series, it was observed that 42% of individuals with ATAAD displayed nonspecific ST and T-wave alterations on their ECG of patients exhibited ischemia changes, while evidence of an acute myocardial infarction was found in 5% of cases. The occurrence of diagnostic delays can be anticipated when an ECG displays abnormalities, as doctors frequently prioritize the investigation of coronary illness as a first diagnosis due to its higher prevalence.[7]

Effective imaging plays a crucial role in the diagnosis and management of this condition due to the high frequency of missed dissections, unusual presentations, and the potential for time-dependent morbidity and mortality. In the context of the Investigational Research and Development (IRAD), the primary diagnostic modality employed was CT (Computed Tomography) in around 69% of instances. Echocardiography was utilized in 25% of cases, MRI was employed in 4% of cases. Aortography, on the other hand, was utilized in 2% to 3% of cases. The growing utilization of computed tomography can potentially be attributed to the increased accessibility and improved scanning speed. CT demonstrates a notable degree of sensitivity and specificity in the diagnosis of acute aortic syndromes and traumatic aortic damage. Additionally, CT has the capability to detect simultaneous coronary involvement, involvement of all four branch vessels, and the presence of blood in the pericardial sac (hemopericardium). Furthermore, CT imaging can assist in the identification of entrance rips in cases of dissection.[5,7]

The patient underwent a surgical procedure involving comprehensive replacement of the aortic arch, including all three supra-aortic branches. Aortic valve replacement was not performed due to the absence of aortic regurgitation from echocardiography as a consequence of aortic dissection. The preferred therapeutic intervention for type A aortic dissection is surgical intervention. The death rate associated with unoperated acute type A aortic dissection is observed to be 1% per hour. Furthermore, the timing of symptom onset, diagnosis, and subsequent surgery has a crucial role in determining patient outcomes. Notably, individuals who undergo surgery within 8 to 12 hours following diagnosis exhibit the highest fatality rate. Previous studies have documented the superiority of surgical interventions compared to conservative treatment, especially in cases when patients come with unfavorable conditions and/or significant comorbidities. The study examined a cohort of 936 individuals diagnosed with ATAAD who were registered in the IRAD database. The analysis focused on patients up to 80 years of age. The findings revealed that the rate of mortality during hospitalization was significantly lower among those who underwent surgical intervention compared to those who received medicinal treatment. The study observed a decreased in-hospital death rate among octogenarians who underwent surgery compared to those who received conservative care (37.9% vs 55.2%).[5,6]

The incidence of aortic arch dissection is observed in over 70% of cases classified as type A dissections, with arch vascular involvement reported in a range of 28% to 73% of cases. The procedure of arch replacement is conducted in cases where there is a significant intimal tear present throughout the arch and its associated vessels, which cannot be effectively addressed through primary resection. Additionally, arch replacement is performed when the aortic arch is either aneurysmal or has experienced a rupture. Furthermore, if a primary tear in the arch is identified during surgery or if the patient has heritable aneurysm disease, arch replacement may also be considered as a treatment option. The utilization of branched graft procedures is commonly favored in the management of arch vessels that are affected.[1]

Drug treatment alone should be the initial approach for managing dissections limited to the descending aorta. It is advisable to suggest prompt interventional therapy just for instances involving problems associated with dissection, such as unyielding discomfort or hypertension, fast aortic expansion, bleeding or controlled rupture, and ischemia of distal organs. Therefore, it is imperative to promptly administer endovascular or surgical intervention to individuals who exhibit the aforementioned problems. The utilization of endovascular repair as a substitute for traditional open surgery in the management of descending aorta has gained considerable popularity due to its notable reduction in morbidity and mortality rates compared to conventional surgical interventions.[8]

The technique of total arch replacement with the elephant trunk surgery has been devised and has shown encouraging outcomes in the treatment of DeBakey type I aortic dissection. Nevertheless, there are numerous issues that might significantly impact the long-

term result, including the continuous perfusion of the distal false lumen and the adverse remodeling of the distal aorta following the surgical procedure. The utilization of thoracic endovascular aortic repair (TEVAR), which is a less invasive method, has demonstrated notable efficacy in the management of type B aortic dissection (TBAD) as well as in cases requiring re-intervention subsequent to the frozen elephant trunk operation. It is believed that open surgery has the potential to transform type I aortic dissection into TEVAR. The utilization of a total arch aortic replacement with an elephant trunk surgery is employed as a therapeutic approach for patients presenting with Stanford type A aortic dissection DeBakey I.[5,9,10]

The endovascular technique can be performed either concurrently (concomitant) with the initial surgery or at a separate time (staged, either earlier or later) than the initial open operation. A randomized controlled trial was conducted across multiple centers, with a total of 154 patients enrolled. The objective of the study was to evaluate the impact of early minimally invasive endovascular repair on distal aortic remodeling and long-term clinical outcomes in patients who had dominant false lumen and residual tears in the descending thoracic aorta following total arch replacement and frozen elephant trunk procedure. In this study, it is recommended that TEVAR operation be conducted no earlier than 30 days following the elephant trunk treatment, but no later than 90 days after its initiation. This timing is intended to facilitate collateral revascularization of the intercostal arteries and minimize the impact of the inflexible thick intimal flap on aortic remodeling. The recommendation for immediate interventional treatment utilizing an endoprosthesis should be limited to instances when complications arising from dissection are present. These complications may include refractory pain or hypertension, fast expansion of the aorta, bleeding or controlled rupture, as well as distal organ ischemia.[10] According to previous study, we did not perform TEVAR procedure for descending aorta at acute onset and planned to perform TEVAR procedure next time because there was no related complication.

4. Conclusion

Type-A aortic dissection (ATAAD) is a cardiovascular emergency with a significant mortality rate. The utilization of imaging and diagnostic technologies has significantly influenced the approach to managing cases with suspected conditions. Acute surgical intervention is recommended for all patients, with the exception of individuals who are in a moribund state or have significant comorbidities. The surgical and perioperative methods employed may differ based on the specific clinical presentation and the nature of the aortic disease. This patient performed a total aortic arch replacement with elephant trunk procedure successfully with is currently scheduled for a planned thoracic endovascular aortic repair (TEVAR) treatment to address the descending aorta.

5. Declaration

5.1 Ethics Approval and Consent to participate
Patient has provided written informed consent prior to involvement in the study.

5.2. Consent for publication
Not applicable.

5.3 Availibility of data and materials
Data used in our study were presented in the main text.

5.4 Competing interests
Not applicable.

5.5 Funding Source
Not applicable.

5.6 Authors contributions
Idea/concept: MF. Design: MF. Control/supervision: SDH, YES. Data collection/processing: MF Analysis/interpretation: MF, SDH. Literature review: MF. Writing the article: MF. Critical review: SDH, YES. All authors have critically reviewed and approved the final draft and are possible for the content and similarity index of the manuscript.

5.7 Acknowledgements
We thank to Brawijaya Cardiovascular Research Center

References

1. Bonow Mann L, Bhatt T, Elsevier S. *Heart disease a textbook of cardiovascular medicine*.

2. Gudbjartsson T, Ahlsson A, Geirsson A, et al. Acute type A aortic dissection–a review. *Scandinavian Cardiovascular Journal*. 2020;54(1):1-13. doi:10.1080/14017431.2019.1660401

3. Sayed A, Munir M, Bahbah EI. Aortic Dissection: A Review of the Pathophysiology, Management and Prospective Advances. *Curr Cardiol Rev*. 2020;17(4). doi:10.2174/1573403x16666201014142930

4. Czerny M, Schmidli J, Adler S, et al. Editor's Choice – Current Options and Recommendations for the Treatment of Thoracic Aortic Pathologies Involving the Aortic Arch: An Expert Consensus Document of the European Association for Cardio-Thoracic Surgery (EACTS) & the European Society for Vascular Surgery (ESVS). *European Journal of Vascular and Endovascular Surgery*. 2019;57(2):165-198. doi:10.1016/j.ejvs.2018.09.016

5. Isselbacher EM, Preventza O, Black JH, et al. 2022 ACC/AHA Guideline for the Diagnosis and Management of Aortic Disease: A Report of the American Heart Association/American College of Cardiology Joint Committee on Clinical Practice Guidelines. *Circulation*. 2022;146(24):E334-E482. doi:10.1161/CIR.0000000000001106

6. Erbel R, Aboyans V, Boileau C, et al. 2014 ESC guidelines on the diagnosis and treatment of aortic diseases. *Eur Heart J*. 2014;35(41):2873-2926. doi:10.1093/eurheartj/ehu281

7. Evangelista A, Isselbacher EM, Bossone E, et al. Insights from the international registry of acute aortic dissection: A 20-year experience of collaborative clinical research. *Circulation*. 2018;137(17):1846-1860. doi:10.1161/CIRCULATIONAHA.117.031264

8. Dinato FJ, Ribeiro Dias R, Abrahão Hajjar L. DISSECÇÃO DA AORTA: MANEJO CLÍNICO E CIRÚRGICO. *Revista da Sociedade de Cardiologia do Estado de São Paulo*. 2018;28(3):260-266. doi:10.29381/0103-8559/20182803260-6

9. Juraszek A, Czerny M, Rylski B. Update in aortic dissection. *Trends Cardiovasc Med*. 2022;32(7):456-461. doi:10.1016/j.tcm.2021.08.008

10. Liu Y, Li L, Xiao Z, et al. Early endovascular intervention for unfavorable remodeling of the thoracic aorta after open surgery for acute DeBakey type I aortic dissection: study protocol for a multicenter, randomized, controlled trial. *Trials*. 2023;24(1). doi:10.1186/s13063-023-07548-x

Heart Sci J 2024; 5(2): 82-85

Contents list available at www.heartscience.ub.ac.id

Heart Science Journal

Journal Homepage : www.heartscience.ub.ac.id

Case Report

Cracking The Case of The Cryptic Coronary: Diagnostic Strategies for Anomalous RCA Originating from LAD

Pratiwi Indrihapsari[1*], Budi Satrijo[2], Anna Fuji Rahimah[2]

[1]Brawijaya Cardiovascular Research Center, Department of Cardiology and Vascular Medicine, Faculty of Medicine, Universitas Brawijaya, Malang, Indonesia.
[2]Department of Cardiology and Vascular Medicine, Faculty of Medicine, Universitas Brawijaya, Malang, Indonesia.

ARTICLE INFO

Keyword :
Anomalous Right Coronary Artery;
CT Coronary Angiography;
RCA from LAD;
Single Coronary Artery.

ABSTRACT

Background: Coronary artery anomalies are typically congenital, though they may remain undetected until routine cardiac catheterization is performed. With a detection rate of only 1.3%, these anomalies often go unnoticed. In rare cases, the right coronary artery may originate from the left coronary system, but this anomaly is generally benign.
Case presentation: A 55-year-old male patient was diagnosed with NSTEMI and underwent coronary angiography. However, despite multiple attempts, the medical team could not cannulate into the right coronary ostium. The left coronary ostium was located in the left sinus of Valsalva. Selective left coronary arteriography revealed normal courses of the left main and LAD but identified a critical stenosis in the LCx and a possible CTO at the RCA ostium. The patient received a stent in the LCx and returned the following month for another angiography, during which he received a stent in the proximal LAD. However, during cine angiography, it was found that the patient had an anomalous RCA that originated from the mid-portion of LAD, coursing anteriorly to the pulmonary artery and down to the right atrioventricular groove. Subsequent CCTA confirmed the RCA's origin from the mid-LAD.
Conclusion: The report finds a rare RCA origin in the mid-LAD. The heart and its complex arterial network may be examined thoroughly, appreciate to coronary CTA, a non-invasive imaging approach. This allows for effective interventional cardiovascular therapy and is helpful for medical cardiac abnormality detection and assessment.

1. Introduction

Congenital coronary artery anomalies manifest differently. Others may have chest pain, dizziness, or cardiac arrest. These abnormalities are often found incidentally during cardiac angiography or coronary CT scans. Approximately 1.3% of people have coronary artery anomalies. However, the aberrant origin of the right coronary artery (RCA) from the left anterior descending artery (LAD) is even rarer, at 0.26%. This abnormality is typically harmless, although its clinical significance depends on the anatomical trajectory.[1,2] It's important to appropriately diagnose and characterize these abnormalities to avoid misdiagnosis as obstructive coronary disease and avoid unnecessary operations and complications.

2. Case Presentation

A male patient, aged 55, was admitted to the catheterization laboratory following an episode of NSTEMI. The patient had a smoking history of more than 20 years and was newly diagnosed with diabetes mellitus. The electrocardiogram showed an inverted T wave at lead II, III, and aVF. The patient's troponin level was markedly elevated at 22.7 mcg/L (normal <1 mcg/L). Coronary angiography was performed through the right femoral artery. The left coronary injection revealed a patent left main coronary artery bifurcated into the left circumflex artery (LCx) and the left anterior descending (LAD) artery. The LCx artery was found to have a diffuse, critical stenosis with thrombus formation in the distal, while the LAD artery had a diffuse stenosis from the ostial to mid segment. A drug-eluting stent was successfully implanted at the stenosis of the LCx artery. However, despite multiple attempts, cannulation into the right coronary ostium was unsuccessful. A chronic total occlusion (CTO) at the ostium of the right coronary artery (RCA) was suspected.

During the subsequent month, the patient underwent another coronary angiography procedure. The LAD revealed diffuse stenosis from its origin to the middle section, and a drug-eluting stent was effectively placed at the site of stenosis. During the angiography procedure, a unique anatomical variation was observed wherein the RCA exhibited an abnormal course, originating as an independent branch from the middle region of the LAD, specifically distal to the first diagonal artery. The RCA

* Corresponding author at: Brawijaya Cardiovascular Research Center, Department of Cardiology and Vascular Medicine, Faculty of Medicine, Universitas Brawijaya, Malang, Indonesia.
E-mail address: tiwihapsari22@gmail.com (P. Indrihapsari).

https://doi.org/10.21776/ub/hsj.2024.005.02.15
Received 22 October 2023; Received in revised form 23 November 2023; Accepted 4 December 2023.
Available online 28 April 2024

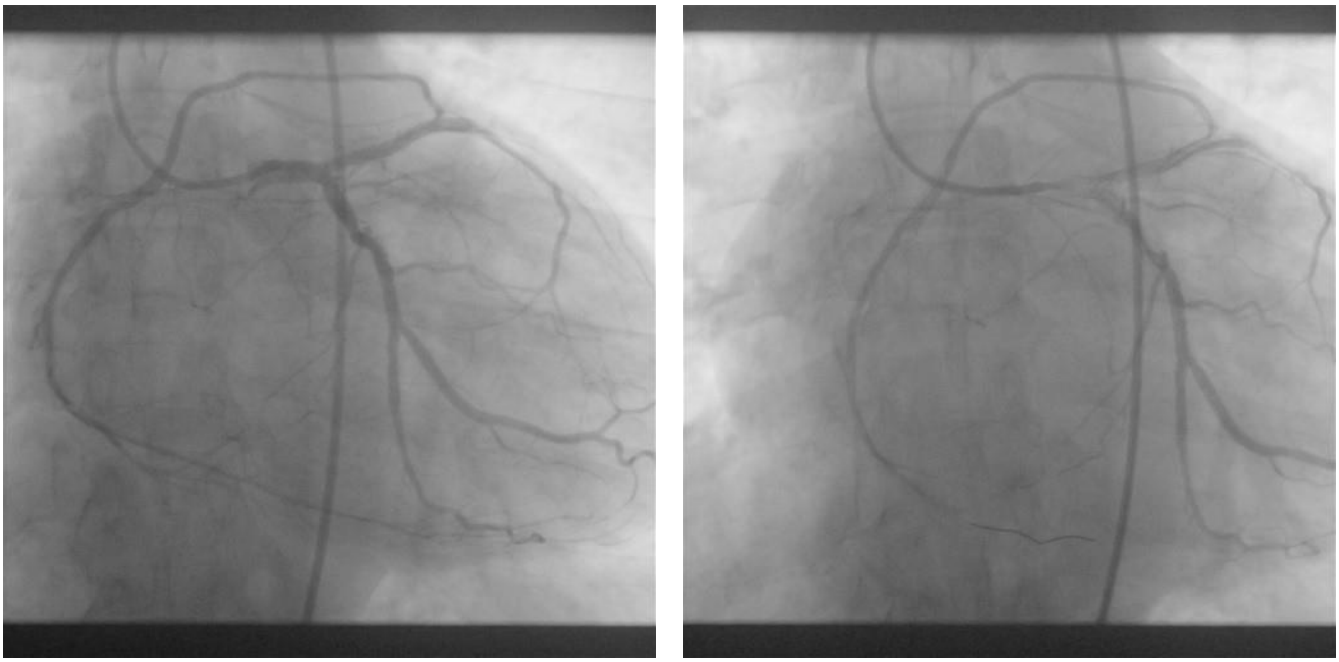

a **b**

Figure 1. a. Coronary angiographic view showed an anomalous RCA arising from mid LAD (arrow); b. A guide wire was inserted into the anomalous RCA



a

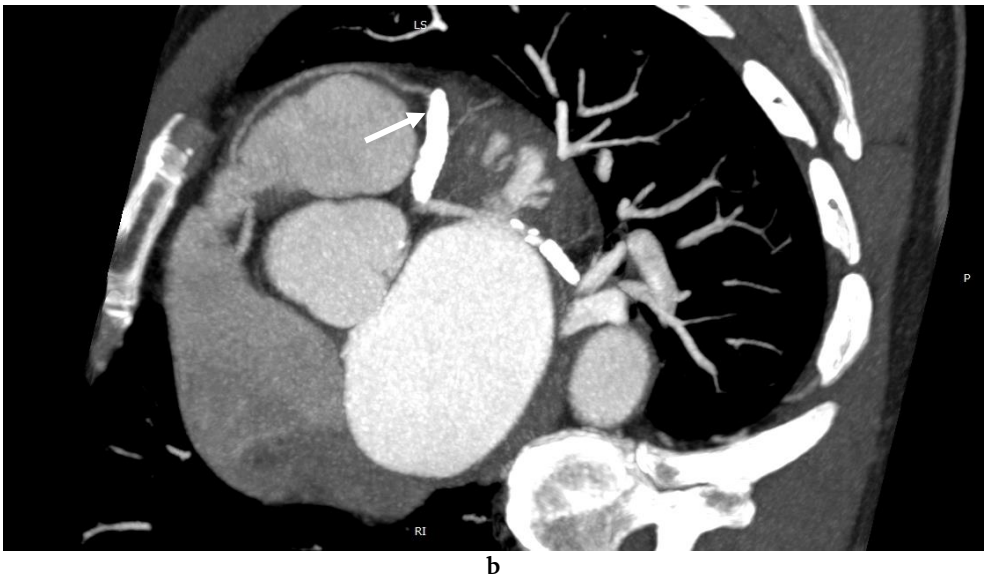

b



c

Figure 2. a. CTA coronary showed Single Left Coronary Artery (arrow); b. Anomalous RCA arising from mid LAD (arrow); c. Course of the anomalous RCA (arrow)

3. Discussion

CAA occur in 0.6% to 5.6% of diagnostic coronary angiography patients and over 1% of routine autopsy.[3] When the ostium of the coronary artery lies above the sinotubular junction, in the posterior aortic sinus, or close to the aortic commissure, this is known as an aberrant origin of the coronary artery. It is also possible for the left and right coronary arteries to branch off from the noncoronary sinus or the opposing artery. In addition, two ostia may originate from a single point, or one ostium may originate from another. The latter condition is referred to as Single Coronary Artery (SCA). When the RCA originates from the left side, it is commonly known as Single Left Coronary Artery (LCA). Conversely, when the LAD originates from the RCA, it is called Single Right Coronary Artery (RCA).[4]

The majority of this report is on the Single Coronary Artery focus on the occurrence of the RCA coming from middle segment of the LAD. This particular anomaly has been widely acknowledged as having a clinically benign nature.[5] Most coronary artery anomalies are not functionally significant; nevertheless, external compression, acute angulation, kinking, twisting, spasm, and atherosclerotic obstruction are all processes that have been proposed to explain myocardial ischemia and can lead to severe complications. The critical clinical implication of the specific coronary artery anomaly described here is the existence of severe proximal LAD stenosis just before the take-off of the anomalous RCA from the LAD. Symptomatic left heart failure was present in this 55-year-old male, and his LVEF was just 33%, which may have been due to severe stenosis in the proximal LAD. In such patients, LAD stenosis can also impact blood flow in the RCA, and in the worst-case scenario, it can induce simultaneous blockage of the LAD and RCA, resulting in a very high risk of death and a catastrophic prognosis. Because of this, it is essential that clinicians understand the possible hazards connected to this kind of coronary artery anomaly and perform the necessary diagnostic imaging to find these anomalies and the risks they may carry. In addition to improving the prognosis and quality of life for people with this condition, this will enable prompt management and intervention.

Coronary angiography is often the gold standard for assessing coronary artery conditions. Unfortunately, it only provides a two-dimensional (2D) image of the intricate three-dimensional (3D) route of the vessel, making it challenging to determine the anatomic path of the aberrant vessel in relation to the pulmonary artery and aorta. If angiographers are not selectively engaged, they may fail to notice aberrant vessels or suppose they are obstructed.[6,7] Even while coronary angiography often displays the coronary architecture, geometry, and course, analyzing the course of anomalous coronary arteries can be difficult for even experienced angiographers.[4,8]

The progression of technology has resulted in the emergence of non-invasive techniques, such as coronary computed tomography angiography (CTA), which are of significant importance in the identification and assessment of coronary anomalies.[3,9] Contrast-enhanced multidetector computed tomography (MDCT) has effectively addressed most issues associated with catheter angiography. The administration of a contrast agent allows for enhanced visualization of the coronary artery, enabling a clear depiction of the anatomical pathway of the coronary arteries inside the major blood vessels and heart chambers. Contrast-enhanced CT has demonstrated a consistent ability to visualize the progression of coronary abnormalities effectively. Moreover, using volume-rendered pictures derived from three-dimensional CT datasets offers a thorough depiction of the anatomical structures of the heart and blood vessels. This is especially valuable for examining intricate vascular abnormalities such as tortuous fistulas.[4,8] CTA of the coronary arteries possesses numerous advantages, such as its noninvasive nature, 3D information provision, ability to achieve high spatial resolution, and relatively short examination duration. The method excels in detecting the potentially harmful pathway known as inter-arterial when the coronary artery traverses between the aorta and the main pulmonary artery. Additionally, it can identify other anatomical characteristics that pose a significant danger, such as a narrow opening resembling a slit, constriction of the vessel at its origin, a route within the artery's walls, and a sharp angle at which it branches off. Coronary abnormalities are more significant in coronary CTA than traditional coronary angiograms.[10,11]

4. Conclusion

The following report outlines a clinical scenario in which a patient was diagnosed with an unusual RCA originating from the LAD. Even though this presentation is uncommon, it usually has no adverse effects unless it travels through prominent vasculature and into the interarterial space. In order to achieve an accurate diagnosis and develop an effective treatment plan, it is necessary to possess

comprehensive knowledge regarding the imaging manifestations of coronary origin anomalies. The utilization of multidetector CT angiography, which incorporates multiplanar reconstruction capabilities and volume rendering techniques, has surpassed traditional angiography's ability to identify these anomalies and offer a more precise depiction of the ostium and course. To facilitate accurate diagnosis and treatment planning, it is mandatory to emphasize the importance of possessing an extensive understanding of the imaging characteristics associated with coronary origin anomalies.

5. Declaration

5.1 Ethics Approval and Consent to participate
Patient has provided written informed consent prior to involvement in the study.

5.2. Consent for publication
Not applicable.

5.3 Availibility of data and materials
Data used in our study were presented in the main text.

5.4 Competing interests
Not applicable.

5.5 Funding Source
Not applicable.

5.6 Authors contributions
Idea/concept: PI. Design: PI. Control/supervision: BS, AF. Data collection/processing: PI Analysis/interpretation: PI. Literature review: PI, BS, AF. Writing the article: PI. Critical review: BS, AFR. All authors have critically reviewed and approved the final draft and are possible for the content and similarity index of the manuscript.

5.7 Acknowledgements
We thank to Brawijaya Cardiovascular Research Center

References

1. Salih M, Abdel-Hafez O, Ibrahim R, Halabi AR, Aloka F. A Single Coronary Artery Anomaly: Right Coronary Artery as a Branch From the Left Anterior Descending Artery. *Cureus*. Published online August 17, 2020. doi:10.7759/cureus.9801

2. Erdogan O, Buyuklu M, Aktoz M. Anomalous origin of the right coronary artery from the left anterior descending artery in a patient with single left coronary artery: A rare coronary artery anomaly and review of the literature. *Int J Cardiol*. 2008;127(2):280-283. doi:10.1016/j.ijcard.2007.04.121

3. Yurtdas M, Gülen O. Anomalous origin of the right coronary artery from the left anterior descending artery: Review of the literature. *Cardiol J*. 2012;19(2):122-129. doi:10.5603/CJ.2012.0023

4. Sampath A, Chandrasekaran K, Venugopal S, et al. Single coronary artery Left (SCA L)-Right coronary artery arising from mid-left anterior descending coronary artery: New variant of Lipton classification (SCA L-II) diagnosed by computed tomographic angiography. *Echocardiography*. 2020;37(10):1642-1645. doi:10.1111/echo.14669

5. Niu Q, Zhao Y, Li H, et al. Case report: Treatment of a patient with STEMI and cardiogenic shock caused by RCA originating from LAD. *Front Cardiovasc Med*. 2023;9:1036274. doi:10.3389/fcvm.2022.1036274

6. Shi H, Aschoff AJ, Brambs HJ, Hoffmann MHK. Multislice CT imaging of anomalous coronary arteries. *Eur Radiol*. 2004;14(12):2172-2181. doi:10.1007/s00330-004-2490-2

7. Ghadri JR, Kazakauskaite E, Braunschweig S, et al. Congenital coronary anomalies detected by coronary computed tomography compared to invasive coronary angiography. *BMC Cardiovasc Disord*. 2014;14(1):81. doi:10.1186/1471-2261-14-81

8. Duran C, Kantarci M, Subasi ID, et al. Remarkable Anatomic Anomalies of Coronary Arteries and Their Clinical Importance: A Multidetector Computed Tomography Angiographic Study. *J Comput Assist Tomogr*. 2006;30(6).

9. Zeina AR, Blinder J, Sharif D, Rosenschein U, Barmeir E. Congenital coronary artery anomalies in adults: non-invasive assessment with multidetector CT. *Br J Radiol*. 2009;82(975):254-261. doi:10.1259/bjr/80369775

10. Husin MH, Mohamad Jamali AA, A Hamid MA, Saad K. Right Coronary Artery Originating From Mid Left Anterior Descending Artery: A Rare Variant of Anomalous Right Coronary Artery Detected on CT Coronary Angiography. *J Cardiovasc Neurovascular Stroke*. 2022;4(3):21-25. doi:10.32896/cvns.v4n3.21-25

11. Rahalkar AM, Rahalkar MD. Pictorial essay: Coronary artery variants and anomalies. *Indian J Radiol Imaging*. 2009;19(01):49-53. doi:10.4103/0971-3026.45345

Heart Sci J 2024; 5(2): 86-91

Contents list available at www.heartscience.ub.ac.id

Heart Science Journal

Journal Homepage : www.heartscience.ub.ac.id

Case Report

Recurrent Orthodromic SVT AVRT with Multiple Accessory Pathway in WPW Syndrome: Ablate All or Not?

Indra Jabbar Aziz[1*], Ardian Rizal[2]

[1]Brawijaya Cardiovascular Research Center, Department of Cardiology and Vascular Medicine, Faculty of Medicine, Universitas Brawijaya, Malang, Indonesia.
[2]Department of Cardiology and Vascular Medicine, Faculty of Medicine, Universitas Brawijaya, Malang, Indonesia.

ARTICLE INFO

Keyword :
Ablation;
Multiple Accessories Pathway;
SVT AVRT Orthodromic;
WPW Syndrome.

ABSTRACT

Background: Patients diagnosed with Wolff-Parkinson-White syndrome (WPW) have a relatively low, nevertheless persistent risk of unexpected mortality. However, this risk can be effectively mitigated by applying radiofrequency catheter ablation targeting the accessory pathway. It is difficult to accurately study predictors because only a minority of patients develop potentially malignant arrhythmias (MA) or passed away, despite essential risk variables being relatively well-known.[1] This study aimed to describe ablation in WPW syndrome.
Case presentation: A 16-year-old male presents with symptoms characterized by palpitations during intense physical exertion, followed by chest pain episodes. The physical examination, CXR, laboratorium, and echocardiography were all within the normal range; his ECG showed shortened PR interval and a delta wave with a positive delta wave at V1 and mostly positive at the inferior lead. He also has recorded ECG when the patient has a tachycardia event with SVT AVRT orthodromic pattern. He underwent EP Study and had several accessory pathways at the posteroseptal mitral annulus and anteroseptal tricuspid. The decision was made to perform ablation on the posteroseptal accessory pathway located at the mitral annulus. An electrophysiology (EP) investigation was conducted at the anteroseptal tricuspid annulus, which did not induce tachyarrhythmia.
Conclusion: Wolff-Parkinson-White syndrome is a congenital cardiac pathway formation, with not all accessory pathways causing tachyarrhythmias. Ablation therapy is necessary for patients with multiple pathways, with pathways with an ERP less than 250 being the only option.

1. Introduction

Wolff-Parkinson-White syndrome, often known as WPW syndrome, is characterized by symptomatic tachycardia, a short PR interval, and delta waves on the electrocardiogram (EKG). Although extremely rare, the disorder can be fatal if not diagnosed and treated promptly. The WPW pattern on an electrocardiogram can conceal ischemia alterations and may raise the risk of arrhythmia and, consequently, mortality.[2]

Wolff-Parkinson-White (WPW) syndrome is a congenital condition that impacts roughly 0.1% of individuals worldwide. During the early heart developmental stages, the atrial and ventricular myocardium become interconnected. Typically, as the atrial and ventricular septa invaginate and form the annulus fibrosus, they terminate all atrioventricular (AV) links with the exception of the AV node and the His bundle. The anatomical pathways causing ventricular preexcitation are termed persistent AV connections. These pathways can either entirely or partly circumvent the AV node and His bundle system.[3] In individuals with this syndrome, electrical impulses bypass the typical AV node pathway due to an anomalous conduction pathway. Diagnosis hinges on distinct ECG waveform patterns indicative of this irregular conduction. Yet, this alternative pathway can sometimes exhibit accelerated impulse transmission, resulting in occasional bouts of rapid heart rhythms and palpable heartbeats.[4] The Wolff-Parkinson-White syndrome, frequently abbreviated as WPW, represents a prevalent etiology of supraventricular tachycardia in the pediatric population. Distinctive electrocardiographic (EKG) manifestations associated with WPW encompass the presence of a delta wave, an expanded QRS duration exceeding 110 milliseconds, a PR interval less than 120 milliseconds, and inversed T wave configurations.[6]

2. Case Presentation

A 16-year-old male presents with symptoms characterized by palpitations during intense physical exertion, which are followed by chest pain episodes. The described chest pain appears within 3 to 5 minutes after the onset of the palpitations. Over the past several months, there has been a noticeable increase in the frequency of reported episodes of chest palpitations. He had no history of febrile illness,

* Corresponding author at: Brawijaya Cardiovascular Research Center, Department of Cardiology and Vascular Medicine, Faculty of Medicine, Universitas Brawijaya, Malang, Indonesia.
E-mail address: indra.jabbar.a@gmail.com (I.J. Aziz).

https://doi.org/10.21776/ub/hsj.2024.005.02.16
Received 23 August 2023; Received in revised form 24 October 2023; Accepted 24 October 2023.
Available online 28 April 2024

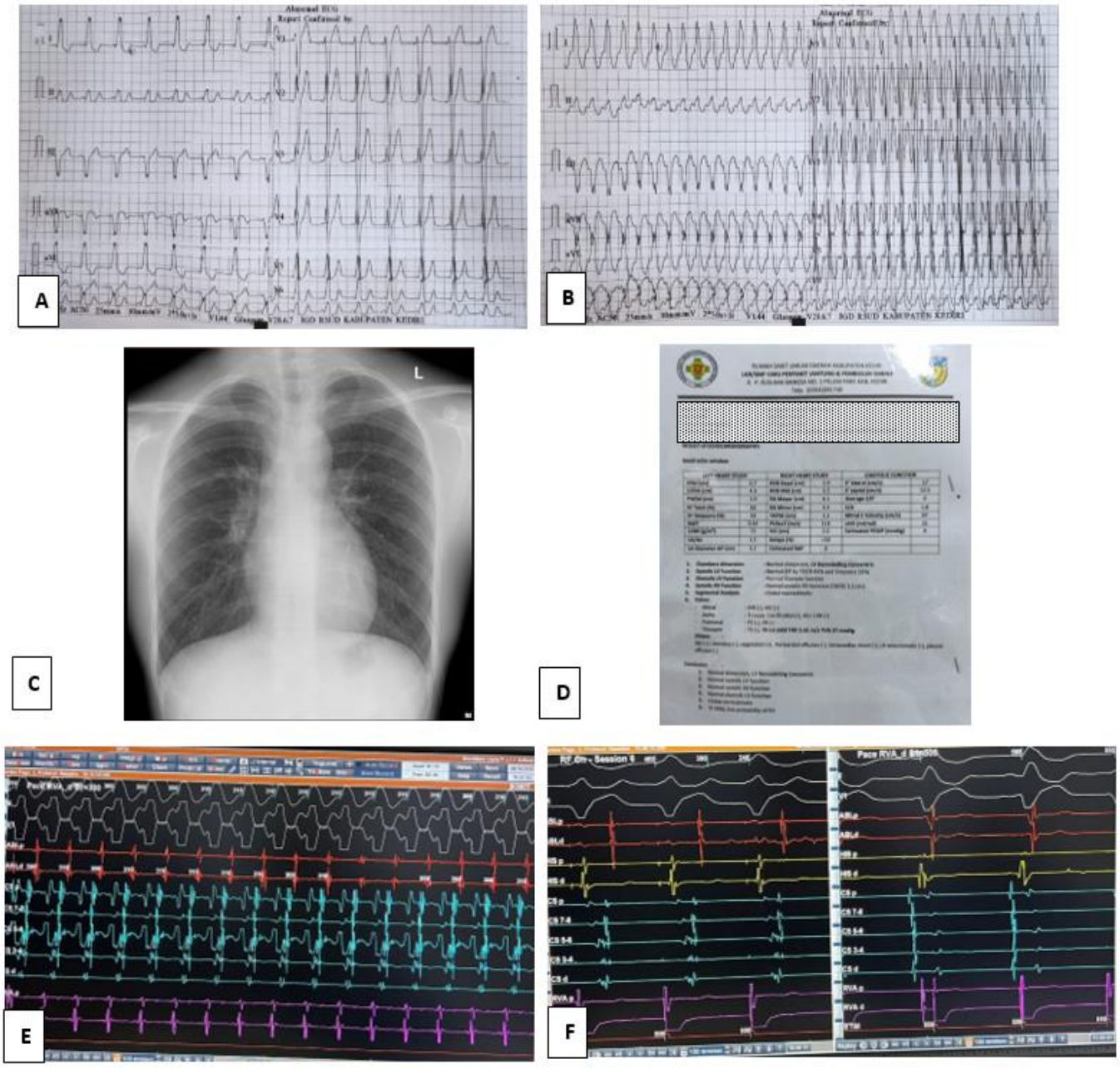

Figure 1. Patient Data : a. ECG at rest with delta wave, b. SVT AVNRT orthodromic ECG, c. Chest X-Ray, d. Echocardiography of Patient, e. EGM of SVT with eccentric pattern, f. Accesory Pathway ablation

dehydration, alcohol consumption, or any medication before having syncope. The patient's family did not have a medical history of a similar condition. The physical examination, CXR, laboratorium, and echocardiography were all within the normal range, and his ECG showed shortened PR interval and a delta wave with a positive delta wave at V1 and mostly positive at inferior lead. He also has recorded ECG when the patient has a tachycardia event with SVT AVRT orthodromic pattern (Figure 1). He underwent EP Study and had several accessory pathways at the posteroseptal mitral annulus and anteroseptal tricuspid. The study of electrophysiology (EP) revealed that eccentric ventricular activation with the right ventricular (RV) catheter had the most rapid activation of the V wave. Eccentric activation was observed during right ventricular pacing, with the fastest A wave detected in the lead CS 5.6. This finding suggests the presence of retrograde conduction in the posteroseptal accessory pathway. The decision was made to perform ablation on the posteroseptal accessory pathway located at the mitral annulus. Additionally, an electrophysiology (EP) investigation was conducted at the anteroseptal tricuspid annulus, with incremental pacing from HRA showing antegrade AP ERP 250 ms, which did not result in the induction of tachyarrhythmia; it was decided not to do ablation at this accessory pathway. The conclusion of the electrophysiology (EP) investigation was obtained, multiple accessories pathway with right accessories pathway antegrade only conduction and concealed left posteroseptal accessories pathway, SVT due to AVRT using left posteroseptal accessories pathway, successful ablation at left posteroseptal accessories pathway, right accessories pathway with ERP 250ms (Benign) did not induce SVT.

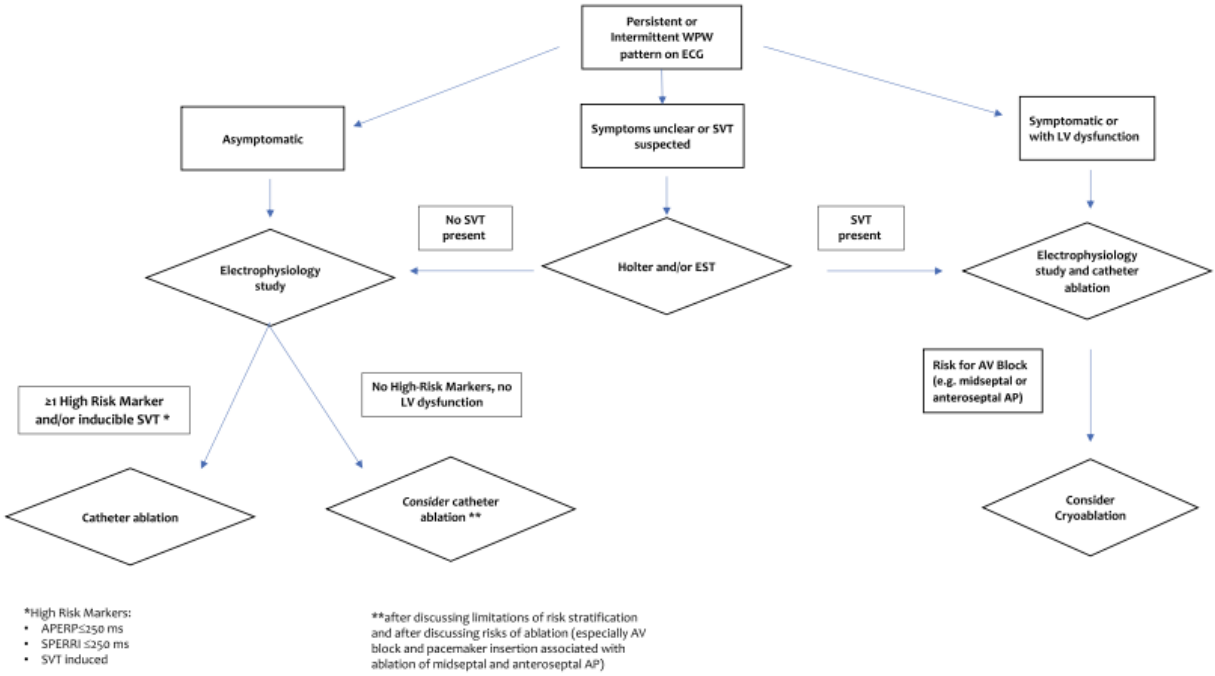

Figure 2. Flow diagram for management of a young person with WPW. [12]

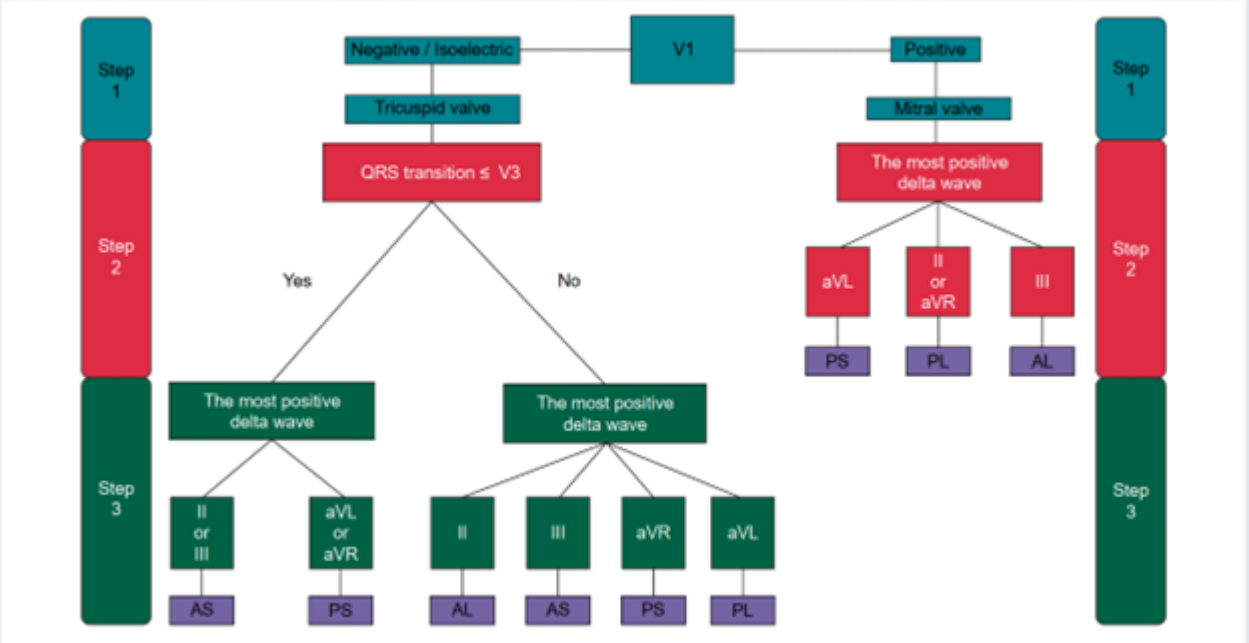

Figure 3. Flowchart for stepwise AP-identification.[15]

3. Discussion

The Wolff-Parkinson-White (WPW) syndrome is characterized by ventricular pre-excitation due to the existence of an extraneous conduction pathway. Clinical manifestations of this syndrome denote both symptomatic presentations and distinct electrocardiogram (ECG) deviations. Conversely, those with only the WPW electrocardiographic pattern might not display clinical symptoms. This syndrome was first elucidated in 1930 by Drs. Louis Wolff, John Parkinson, and Paul White from Boston, Massachusetts, and London, UK. Their characterization related to a syndrome typified by a diminished PR interval, derived from observations in eleven athletically inclined, ostensibly healthy subjects. Further insights in 1932 by Holzmann and Scherf pinpointed the syndrome's origin to an accessory conduction pathway.[7]

Accessory conduction tracts denote myocardial conduction channels traversing the atrioventricular (AV) groove at distinct positions along the annulus fibrosus on both cardiac aspects. Crucially, these tracts are absent within the mitral valve annulus sector between the right and left fibrous trigones. These pathways predominantly inhabit specific cardiac zones. The left lateral wall is frequently involved, representing around 58% of instances. Following this, the posterior septal zone accounts for nearly 24% of cases. The right lateral wall is involved in about 13% of cases, while the anterior septal area is relatively rare, constituting roughly 5% of instances. Unlike the AV node, which typically manifests gradual, incremental conduction, these accessory tracts display swift, non-decremental conduction coupled with an extended effective refractory period (ERP).[8]

Within a sinus rhythm, the electrocardiographic depiction reveals a hallmark configuration. This is delineated by (i) a diminished PR interval (sub-120 milliseconds), (ii) a nuanced initial segment of the QRS complex, often referred to as the 'delta wave', and (iii) a prolonged QRS duration (exceeding 120 milliseconds). Notably, most accessory pathways (APs) resulting in the WPW electrocardiographic

pattern arise in anatomically regular hearts. Infrequent familial iterations of pre-excitation linked with left ventricular (LV) hypertrophy and systemic disorders have also been documented.[9]

The presence of numerous accessory pathways within pediatric groups is an aspect scarcely illuminated in contemporary studies. An intensive analysis was conducted on medical records of 317 pediatric individuals diagnosed with Wolff-Parkinson-White syndrome, who underwent electrophysiological assessment and radiofrequency catheter ablation. Of these, 28 patients (constituting 9% of the aggregate) revealed multiple conduits, collectively summing to 64 pathways. Specifically, 21 patients had two pathways, six had three, and a lone case exhibited four conduits. In terms of distribution, the left lateral wall encompassed 22 pathways, the right lateral wall housed 19, the posteroseptal area had 17, and the anteroseptal region contained 6. Optimal treatment requires meticulous mapping of the principal accessory conduit and recognition of any supplementary tracts. Failing to pinpoint multiple pathways might lead to sustained tachycardia post-ablation. While multiple conduits have been acknowledged in various research undertakings, a focused investigation on the traits of these pathways in a younger population is yet to be undertaken.[10]

Approximately 10% of patients diagnosed with Wolff-Parkinson-White (WPW) syndrome present with antidromic supraventricular tachycardia (SVT), where the accessory pathway functions as the anterograde conduit. Conversely, the retrograde conduit might be represented by either the typical conduction mechanism or an additional accessory pathway. This clinical presentation is frequently termed a manifest accessory trajectory, delineated by evident pre-excitation on the electrocardiogram (ECG) and an augmented predisposition for the onset of antidromic supraventricular tachycardia (SVT) in the implicated cohort.[8] In scenarios involving pre-excited atrial fibrillation (AF), prudence is essential to preclude its transformation into atrial flutter and subsequently deter the potential initiation of 1:1 conduction. Beyond class IC antiarrhythmic agents, therapeutic options such as beta-blockers, diltiazem, or verapamil might be considered, especially when there's an absence of evident pre-excitation on the baseline electrocardiogram (ECG).[9]

In the recent two decades, catheter ablation has emerged and fortified its role as a widely accepted treatment modality for Wolff-Parkinson-White syndrome (WPW) patients. The procedure has continually shown commendable efficacy, characterized by high success rates and minimal complication occurrences. Contemporary guidelines issued by the European Heart Rhythm Association in conjunction with the American College of Cardiology Foundation/American Heart Association/Heart Rhythm Society emphasize catheter ablation as the recommended therapeutic approach for those exhibiting Wolff-Parkinson-White syndrome symptoms.[11]

Catheter ablation stands as the endorsed therapeutic intervention for individuals manifesting symptoms of recurrent atrioventricular reentrant tachycardia (AVRT) or pre-excited atrial fibrillation (AF). For those patients presenting with asymptomatic and sporadic episodes, it remains imperative to judiciously weigh the benefits against the potential risks of the invasive ablation procedure relative to sustained pharmacologic management in therapeutic decision-making (Figure 2). Procedures aimed at the atrioventricular pathway (AP) have showcased a commendable immediate success rate, while also maintaining a comparatively reduced complication frequency, contingent upon the pathway's precise location. Noteworthy complications post-ablation of septal accessory pathways (APs) encompass cardiac tamponade, which is seen in a range of approximately 0.13% to 1.1% of instances, and complete atrioventricular (AV) block, noted in about 0.17% to 2.7% of the patient population. When septal accessory pathways (APs) are proximal to the atrioventricular node (AVN), the electrocardiogram (ECG) typically reveals a positive delta wave in leads avF and AVL, combined with a slender positive delta wave in lead V1, juxtaposed with a predominantly negative QRS complex.[9]

The evolution and efficiency of catheter ablation, complemented by cutting-edge innovations like 3-dimensional (3D) mapping, cryothermal modalities, and intracardiac echocardiography (ICE), have substantially reshaped the electrophysiologists' perspective on Wolff-Parkinson-White syndrome (WPW). When executed by proficient specialists, the curative rate for Wolff-Parkinson-White syndrome (WPW) in the pediatric cohort stands at an impressive 95%. This shifts the risk-benefit equilibrium decidedly in favor of ablation as the therapeutic modality of choice. Within the electrophysiology community, there's a converging view that catheter ablation is warranted for symptomatic WPW patients meeting specific criteria in age or anatomical dimensions. However, the management of asymptomatic individuals remains a topic of active debate and scholarly scrutiny.[12]

Incomplete ablation of the accessory pathway (AP) can often stem from the existence of multiple pathways that elude detection during the electrophysiological study. When spaced by an interval of 1-3 cm, the presence of several accessory paths (APs) has been documented. Within a cohort of 250 patients, the most commonly identified tandem of multiple APs was the coexistence of right posteroseptal and right free wall conduits. The incidence of these multitudinous accessory pathways (APs) fluctuates between 3% and 13%. Afflicted individuals might harbor a heightened predisposition to conditions like supraventricular tachycardia (SVT), antidromic reentrant circuits, expedited conduction during atrial fibrillation (AF), and ventricular fibrillation.[13] It's well-acknowledged within the medical community that ventricular fibrillation (VF) can manifest due to sustained preexcited atrial fibrillation (AF), even in the absence of underlying structural heart abnormalities. This occurrence becomes especially pertinent when multiple accessory pathways (APs) coexist. Detecting the presence of numerous accessory pathways (APs) can pose diagnostic intricacies and is deemed a significant risk determinant for ventricular fibrillation (VF) in patients diagnosed with Wolff-Parkinson-White (WPW) syndrome.[14]

The EASY-WPW algorithm hinges on the scrutiny of QRS polarity and transition to pinpoint the most positive delta wave, or, in its absence, the most pronounced QRS complex. Operationally, the delta wave is perceived as the inaugural 20-40 milliseconds of the earliest QRS deviation (Figure 3).

In the context of a left-sided AP:

- Initial focus is on the V1 lead's polarity; a positive polarity signifies a left-sided action potential.
- Subsequent identification of the most salient delta wave comes next.
- Specific delineation of the atrioventricular pathway (AP) hinges on observing the dominant positive delta wave across leads II, III, aVR, and aVL. For instance, a pronounced positive delta wave in lead aVL indicates a posteroseptal locale, whereas its presence in leads II or aVR points towards a posterolateral orientation. Furthermore, a lead III positive delta wave alludes to an anterolateral position of the AP.

Considering a right-sided AP:

- Either a negative polarity or an isoelectric waveform in V1 earmarks a right-sided atrial potential.
- The consequent step, reliant on the QRS transition in precordial leads concerning the V3 lead's polarity, zeroes in on QRS transitions either ≤ or > V3.
- The AP's precise location is discerned by the predominant positive delta wave across leads II, III, aVR, and aVL. For instance, a positive delta wave in either lead II or III suggests an anteroseptal orientation, while its observation in leads aVR or aVL leans towards a posteroseptal pathway. If the QRS transition exceeds V3, the most pronounced delta wave in aVL hints at a posterolateral AP positioning, whereas in lead II, an anterolateral orientation emerges. Likewise, lead III suggests an anteroseptal placement, and finally, aVR insinuates a posteroseptal AP location.[15]

The clinical and electrophysiological features that are correlated with an increased probability of sudden cardiac death include:

- a younger age group
- the manifestation of AV-reciprocating tachycardia during electrophysiological investigations,
- the presence of multiple accessory pathways
- the capability of the accessory pathway to promote rapid conduction to the ventricles.

In evaluating the electrophysiological dynamics during atrial fibrillation (AF), two principal parameters emerge as pivotal: the Shortest Pre-excited RR Interval (SPERRI), which manifests an initial duration of less than 250 ms, and the Antegrade Effective Refractory Period (ERP) of the atrioventricular node (AVN) that is demarcated by a duration not exceeding 250 ms. The prevailing consensus within the cardiological community advocates for the prophylactic utilization of catheter ablation targeting the accessory pathway, especially under defined clinical scenarios. Such scenarios encompass instances where the SPERRI during AF does not surpass 250 milliseconds, the ERP during programmed atrial stimulation remains within 240 milliseconds or shorter, the accessory pathway is a tangible contributor to the manifest arrhythmic episode, the presence of any high-risk clinical markers, or the detection of multiple accessory pathways. [8] During exercise testing or subsequent to the administration of agents such as procainamide, propafenone, or disopyramide, the abrupt normalization of the PR interval and concomitant absence of the delta wave have been interpreted as surrogate markers of a reduced risk profile in non-invasive electrophysiological evaluations.[9]

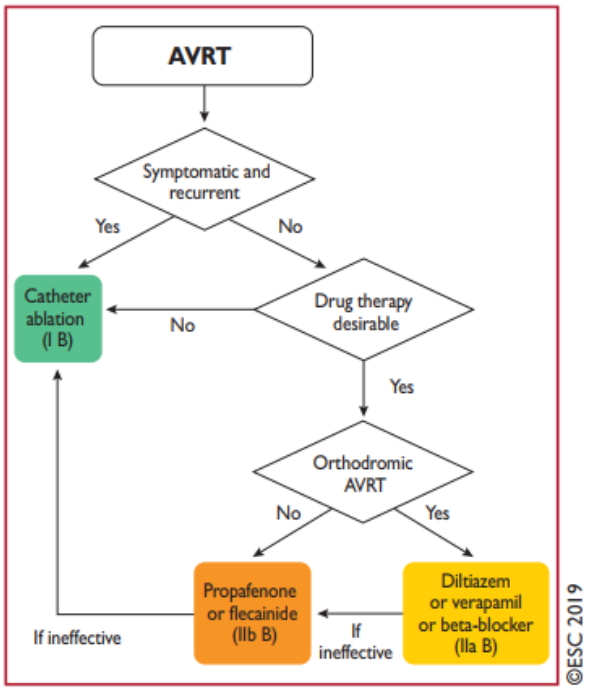

Figure 4. Chronic therapy of atrioventricular re-entrant tachycardia. atrioventricular re-entrant tachycardia.[9]

In assessing the approach to radiofrequency catheter ablation (RFCA) for Wolff-Parkinson-White (WPW) syndrome, it is pivotal to weigh the potential complications of the intervention against the risks of life-threatening arrhythmias if WPW remains unaddressed. The consensus guidelines from the American College of Cardiology (ACC), American Heart Association (AHA), and European Society of Cardiology (ESC) opine that the inherent risks of untreated WPW pose a greater threat than those tied to RFCA. Given its commendable efficacy and minimal risk profile, RFCA is thereby endorsed as the primary therapeutic choice for symptomatic WPW patients by these guidelines (Figure 4). However, a clear stance on prophylactic RFCA for asymptomatic WPW cases is still lacking. Pertinent literature suggests that a notable fraction, about 15%, of those with asymptomatic WPW might confront arrhythmic events later in life. It is paramount to note, though, that only a subset of this population is susceptible to ventricular fibrillation (VF) culminating in cardiac arrest. A substantial majority of asymptomatic individuals remain free of any clinical manifestations. Hence, electrophysiological studies (EPS) play a quintessential role in risk stratification for these asymptomatic WPW individuals, with RFCA being reserved for those discerned to harbor an elevated risk of detrimental arrhythmias.[16]

4. Conclusion

Wolff-Parkinson-White (WPW) syndrome is a variant of ventricular pre-excitation resulting from an extraneous conduction tract. This is demarcated by a reduced PR interval, a nuanced QRS segment, and an expanded QRS complex. Predominantly, accessory pathways (APs) in WPW are present in anatomically regular hearts. Unsuccessful ablation of these pathways can sometimes be ascribed to undetected conduits. The prevalence of multiple APs oscillates between 3% and 13%, elevating the risk factors like tachycardia, antidromic reentry, heightened conduction during atrial fibrillation, and ventricular fibrillation. For those manifesting with recurrent atrioventricular reentrant tachycardia or pre-excited atrial fibrillation, catheter ablation is advocated. Parameters signaling an augmented risk of sudden cardiac demise encompass a younger demographic, AV-reciprocal tachycardia, the presence of severalaccessory conduits, and the pathway's capability to expedite conduction to ventricles. Pertinent metrics encompass SPERRI, the minimal preexcited RR interval, and the effective refractory period (ERP) of the atrioventricular node, both falling below 250 ms.

5. Declaration

5.1 Ethics Approval and Consent to participate
Patient has provided written informed consent prior to involvement in the study.

5.2. Consent for publication
Not applicable.

5.3 Availibility of data and materials
Data used in our study were presented in the main text.

5.4 Competing interests
Not applicable.

5.5 Funding Source
Not applicable.

5.6 Authors contributions
Idea/concept: JAB. Design: JAB. Control/supervision: AR. Data collection/processing: JAB Analysis/interpretation: AR. Literature review: JAB, AR. Writing the article: JAB. Critical review: AR. All authors have critically reviewed and approved the final draft and are possible for the content and similarity index of the manuscript.

5.7 Acknowledgements
We thank to Brawijaya Cardiovascular Research Center

References

1. Pappone C, Vicedomini G, Manguso F, et al. The natural history of WPW syndrome. *Eur Hear Journal, Suppl.* 2015;17:A8-A11. doi:10.1093/eurheartj/suv004

2. Iqbal AM, Ghazni MS, Mubarik A, Zubair N, Jamal SF. The Conversion of Wolff-Parkinson-White (WPW) Pattern into WPW Syndrome in the Presence of Ischemia: A Case Report. *Cureus*. 2019;11(2). doi:10.7759/cureus.4147

3. CAIN ME, LUKE RA, LINDSAY BD. Diagnosis and Localization of Accessory Pathways. *Pacing Clin Electrophysiol*. 1992;15(5):801-824. doi:10.1111/j.1540-8159.1992.tb06847.x

4. Ibrahim Ali Sherdia AF, Abdelaal SA, Hasan MT, et al. The success rate of radiofrequency catheter ablation in Wolff-Parkinson-White-Syndrome patients: A systematic review and meta-analysis. *Indian Heart J*. 2023;75(2):98-107. doi:10.1016/j.ihj.2023.02.001

5. Dalili M, Kargarfard-Jahromi MR, Kamali F. Successful catheter ablation in infants with multiple accessory pathways and incessant arrhythmia. *Iran Hear J*. 2021;22(2):119-123.

6. Chen M, Gomaa H, Cortez-resendiz A, Martin C, Francis A, Bellon A. Case Report Quetiapine and Wolff-Parkinson-White Syndrome. 2020;2020(Table 1).

7. Balta A, Ceasovschih A, Șorodoc V, et al. Broad Electrocardiogram Syndromes Spectrum: From Common Emergencies to Particular Electrical Heart Disorders. *J Pers Med*. 2022;12(11). doi:10.3390/jpm12111754

8. Vijay Y, Sanjeev T, Ratna Mani G, et al. A Wolff-Parkinson-White (WPW) Electrocardiographic Pattern in Asymptomatic Patient – State-of-the-Art-Review. *J Cardiol Cardiovasc Med*. 2022;7(2):045-052. doi:10.29328/journal.jccm.1001132

9. Brugada J, Katritsis DG, Arbelo E, et al. 2019 ESC Guidelines for themanagement of patients with supraventricular tachycardia. *Eur Heart J*. 2020;41(5):655-720. doi:10.1093/eurheartj/ehz467

10. Weng KP, Wolff GS, Young ML. Multiple accessory pathways in pediatric patients with Wolff-Parkinson-White syndrome. *Am J Cardiol*. 2003;91(10):1178-1183. doi:10.1016/S0002-9149(03)00263-7

11. Fujino T, De Ruvo E, Grieco D, et al. Clinical characteristics of challenging catheter ablation procedures in patients with WPW syndrome: A 10 year single-center experience. *J Cardiol*. 2020;76(4):420-426. doi:10.1016/j.jjcc.2020.05.003

12. Etheridge SP, Gakenheimer-Smith L, Asaki SY, Niu M. Asymptomatic Wolff-Parkinson-White Syndrome: An Ounce of Prevention Is Worth the Risk of Cure. *Curr Cardiol Rep*. 2023;25(6):543-551. doi:10.1007/s11886-023-01879-6

13. Helm RH, Varkey SC, Karnik AA. Differential effective refractory period as a useful marker of multiple accessory pathways. *J Arrhythmia*. 2019;35(2):296-299. doi:10.1002/joa3.12162

14. Pappone C, Santinelli V, Rosanio S, et al. Usefulness of invasive electrophysiologic testing to stratify the risk of arrhythmic events in asymptomatic patients with Wolff-Parkinson-White pattern: Results from a large prospective long-term follow-up study. *J Am Coll Cardiol*. 2003;41(2):239-244. doi:10.1016/S0735-1097(02)02706-7

15. El Hamriti M, Braun M, Molatta S, et al. EASY-WPW: a novel ECG-algorithm for easy and reliable localization of manifest accessory pathways in children and adults. *Europace*. 2023;25(2):600. doi:10.1093/EUROPACE/EUAC216

16. Liu A, Pusalkar P. Asymptomatic Wolff-Parkinson-White syndrome: Incidental ECG diagnosis and a review of literature regarding current treatment. *BMJ Case Rep*. Published online 2011:2-5. doi:10.1136/bcr.05.2011.4192

Volume 05 | Issue 02
28st April 2024
p-ISSN 2721 - 9984
e-ISSN 2721 - 9976
heartscience.ub.ac.id

Heart Science Journal

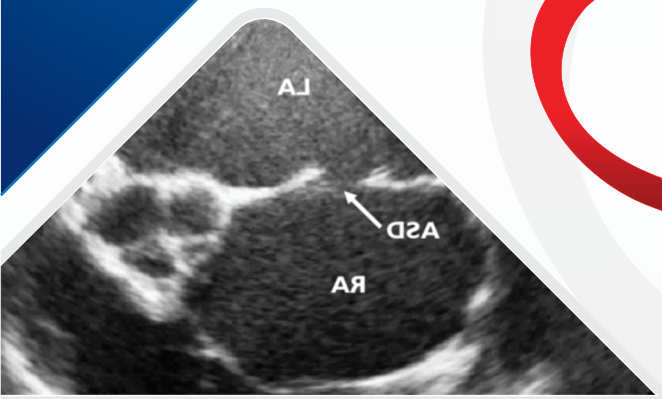

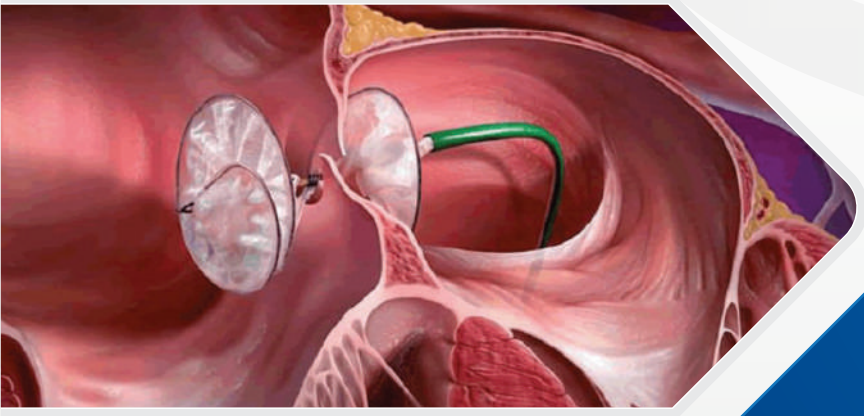



Heart Science Journal Secreteriat

Department of Cardiology and Vascular Medicine Universitas Brawijaya
dr. Saiful Anwar General Hospital - ICVCU 3rd Floor
Jl. Jaksa Agung Soeprapto No. 2, Malang, Indonesia - 65121
Tel/Fax: (+62341) 346 818
Website: www.heartsciencejournal.ub.ac.id

Universitas Brawijaya