



## Case Report

# Primary Percutaneous Coronary Intervention in ST-Elevation Myocardial Infarction with Acute Kidney Injury Caused by Cardiogenic Shock, Is it Really Safe?; A Case Report

Oktafin Srywati Pamuna<sup>1\*</sup>, Mohammad Saifur Rohman<sup>2</sup>, Setyasih Anjarwani<sup>2</sup>, Cholid Tri Tjahjono<sup>2</sup>

<sup>1</sup> Brawijaya Cardiovascular Research Center, Department of Cardiology and Vascular Medicine, Faculty of Medicine, Universitas Brawijaya, Malang, Indonesia.

<sup>2</sup> Department of Cardiology and Vascular Medicine, Faculty of Medicine, Universitas Brawijaya, Malang, Indonesia

## ARTICLE INFO

## Keywords:

Acute Kidney Injury;  
Cardiogenic Shock;  
ST-Elevation Myocardial Infarction

## ABSTRACT

**Background:** ST-elevation myocardial infarction (STEMI) is a life-threatening condition. STEMI condition accompanied by complications such as prolonged shock condition and become Acute Kidney Injury (AKI), it is still a question of whether to be treated conservatively or invasively. If PPCI was an option, how to prevent the worsening outcome is still an issue. We present the case of a woman, 53 years old with STEMI inferior onset 5 hours underwent PCI in acute kidney injury condition caused by cardiogenic shock.

**Objective:** This study aimed to elaborate the safety of Primary Percutaneous Coronary Intervention in ST-Elevation Myocardial Infarction with Acute Kidney injury caused by Cardiogenic Shock

**Case Presentation:** A 53 years old, woman, was referred from a private hospital with STEMI inferior Killip IV onset 5 hours with typical chest pain and azotemia. Creatinine serum was 3.4 mg/dl; eGFR 15 ml/m/1.73m<sup>2</sup>. Blood Gas Analyses show metabolic acidosis uncompensated. In the emergency room, she got hydration and inotropic drugs. After the PCI procedure, she was fallen into an altered mental status and shock condition. The laboratorium result in our hospital showed improvement of creatinine level to 1.6 mg/dl. We treated this patient for 9 days, with optimal medicaments and fluid therapy. On the last day of treatment, there is an improvement in clinical presentation and laboratorium results.

**Conclusion:** Acute renal failure is a frequent complication in STEMI, leading to higher mortality, morbidity, and intrahospital complications. PPCI is a reperfusion strategy recommended by the guideline in the setting of myocardial infarction with cardiogenic shock. Proper management to prevent worsening of renal function in this condition is very important.

## 1. Introduction

ST-elevation myocardial infarction (STEMI) is a life-threatening condition, defined by characteristic symptoms of myocardial ischemia in association with ST-segment elevation in two contiguous lead of electrocardiogram (EKG) and elevation of the cardiac marker. Its frequency is increasing, with 1-year mortality approximately 10%. In the presentation of cardiogenic shock, the mortality rate remains high at 40-50%. Delays in reperfusion for direct-presenting patients were associated with higher mortality.<sup>1,2</sup> AKI is characterized by a dysfunction of structure and function of the kidney acutely. AKIN (Acute Kidney Injury Network) and KDIGO (Kidney Disease Improving Global Guidelines) define AKI as a percentage increase in serum creatinine of more than or equal to 50% (1.5-fold from baseline), with or without oliguria.<sup>3</sup>

AKI is a frequent complication in STEMI patients, leading to higher morbidity, mortality, bleeding complications, and prolonged hospitalization.<sup>4,5</sup> The incidence of AKI in STEMI patients ranges from 5% to 30%, more than 33 % in cardiogenic shock, more often in women than men (10.5 % vs 7.8%).<sup>6,7</sup> Some studies showed that STEMI patients who underwent PPCI in acute kidney injury conditions were associated with a higher mortality rate and renal function worsening. CADILLAC study showed that the 30-day mortality rate was 16% in patients with AKI compared to 1 % in those without AKI. On the other side, in the setting of STEMI with cardiogenic shock, PPCI can improve renal perfusion and renal function. An accurate clinical assessment is needed according to each patient's condition to determine the appropriate treatment option. Management pre, during, and post-procedure related to outcome.<sup>8</sup>

\*Corresponding author at: Brawijaya Cardiovascular Research Center, Department of Cardiology and Vascular Medicine, Faculty of Medicine, Universitas Brawijaya, Malang, Indonesia  
E-mail address: [okspamuna@gmail.com](mailto:okspamuna@gmail.com) (O. S. Pamuna).

<https://doi.org/10.21776/ub.hsj.2021.002.03.8>

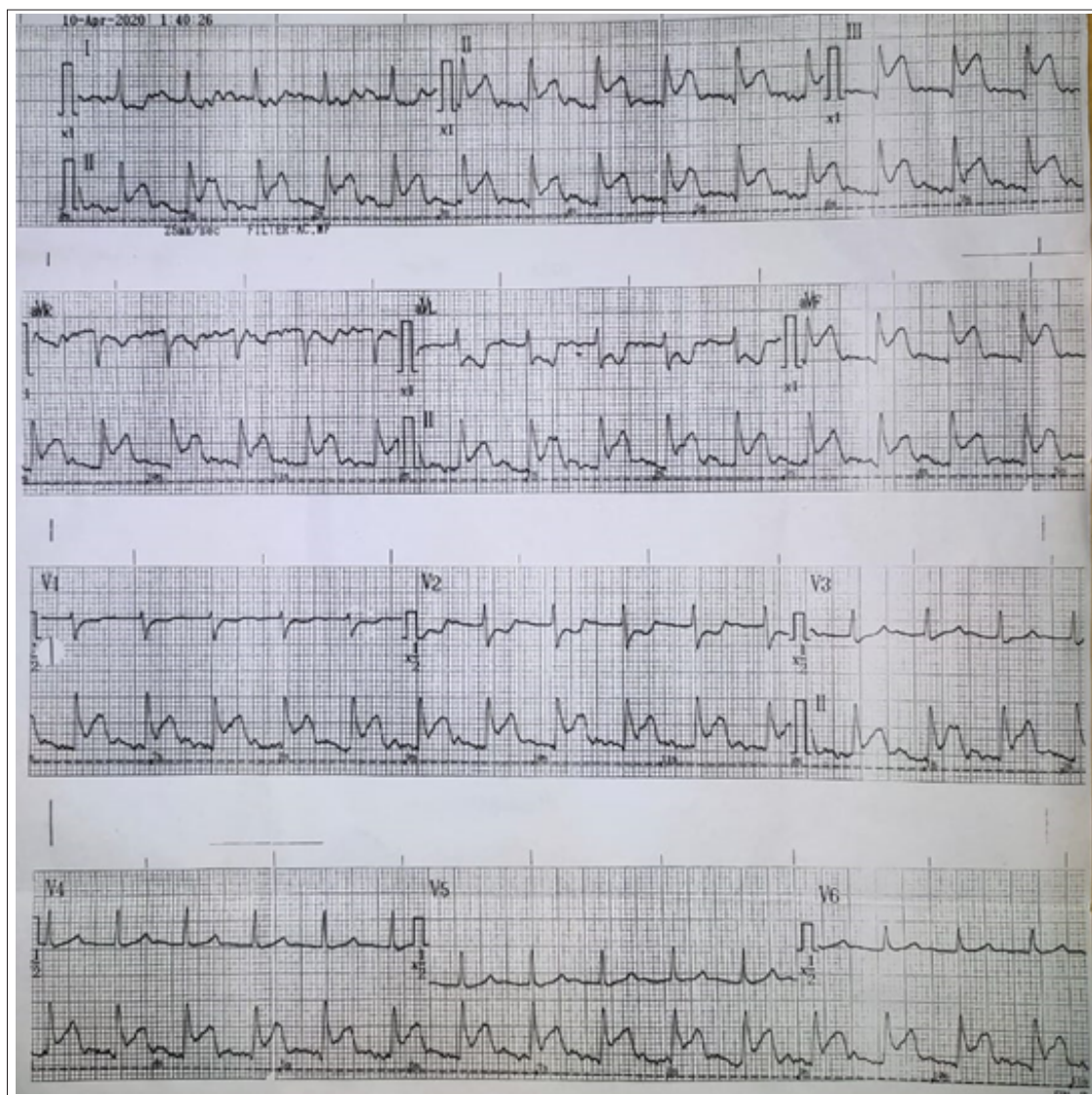
Received 9 June 2021; Received in revised form 12 June 2021; Accepted 24 June 2021

Available online 1 July 2021

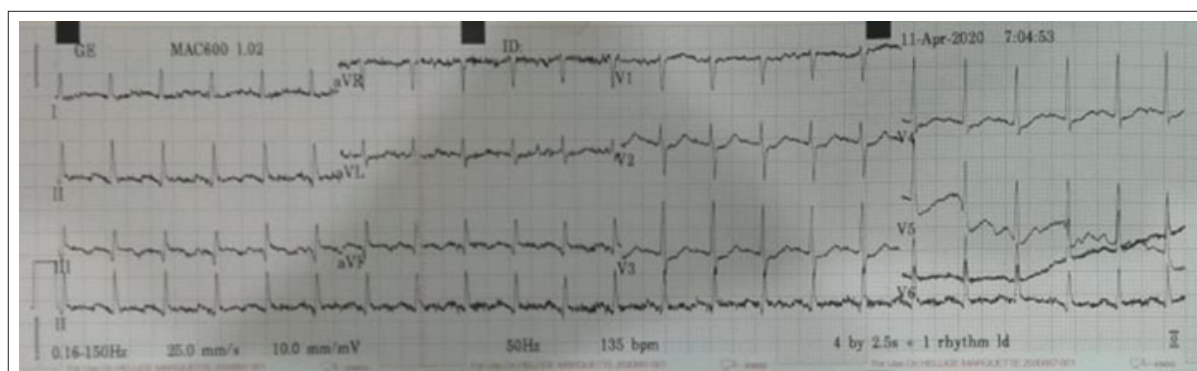This case demonstrates that STEMI conditions complicated with prolonged shock and AKI stage 3 could have a better outcome if treated appropriately.

## 2. Case Presentation

A 53 years old, woman, was referred to a capable PCI hospital from a private hospital with STEMI inferior. She was already admitted to a private hospital due to nausea and vomiting and was diagnosed with gastritis. The ECG showed a normal sinus rhythm. In the middle night, she felt chest pain, typical, with worsening of nausea



(A)



(B)

Figure 1. (A) EXG before PPCI shows STEMI Inferior (B) ECG iafer PPCI, ST-elevation in inferior lead was back to baseline, with T inverted.

and vomiting accompanied by cold sweating, duration > 30 minutes, didn't relieve by rest. At the time, the ECG was performed and showed STEMI inferior. Laboratory result show mild leukocytosis, 12,700/ $\mu$ L, Urea 68 mg/dL, creatinine 3.4 mg/dL, with eGFR 15 ml/m<sup>2</sup>/1.73m<sup>2</sup>. There were cardiomegaly and minimal pleural effusion in hemithorax Sinistra on the CXR view. Then she was referred to a capable PCI hospital for revascularization. When she arrived, the systolic blood pressure was found at 70 mmHg; blood gas analyses show severe metabolic acidosis (pH 7.0, pCO<sub>2</sub> 20.2, pO<sub>2</sub> 94, bicarbonate 5.3, base excess -26, SaO<sub>2</sub> 93%). She was given 250 ml of normal saline and an inotropic agent. Echocardiography findings were left ventricle dilatation with LV eccentric hypertrophy, ejection fraction was 22%, impaired relaxation, normal RV function, and valve. Primary PCI was performed in the early morning, using about 100cc of contrast. Two DES was implanted in the ostial proximal Right Coronary Artery (RCA) and distal RCA. After PPCI, hemodynamic was more stable with hydration 1 cc/kg BW/hour and inotropic agent. During observation in the intensive care unit, she becomes delirious and was referred to RSSA for further management. Laboratory findings after PPCI show improvement in renal function with Urea 48.3 mg/dL, creatinine 1.64 mg/dL, and eGFR 35 ml/m<sup>2</sup>/1.73m<sup>2</sup>. Blood gas analyses show metabolic acidosis fully compensated (pH 7.35, pCO<sub>2</sub> 25.1, pO<sub>2</sub> 140, bicarbonate 14, base excess -12, SaO<sub>2</sub> 99%).

During two days of follow-up at the cardiovascular intensive care unit, the patient still complained about intermittent nausea and vomiting, hemodynamic relative stable with tapering off of inotropic agents. She got hydration IVFD NS 0.9% 1 cc/kg BW/hour. Urine output was 1600 cc/day, equal fluid balance. BGA results show improvement compared to the previous one, with acidosis metabolic fully compensated (pH 7.34, pCO<sub>2</sub> 34.6, pO<sub>2</sub> 119, bicarbonate 19, base excess -6.9, SaO<sub>2</sub> 98.4%). Renal function also found to be improved with Urea was 23.5 mg/dL, creatinine was 1.29 mg/dL, and eGFR 47 ml/m<sup>2</sup>/1.73m<sup>2</sup>.

During follow-up in the ward, she complains about intermittent vomiting; hemodynamic was stable, urine output was 1700-1900 cc/24 hours with equal to -100 cc/24 hours balance. Urea was 8.2 mg/dL, creatinine 0.8 mg/dL and GFR 84 ml/m<sup>2</sup>/1.73m<sup>2</sup>. The patients improved both clinically and laboratory findings.

### 3. Discussion

STEMI is a life-threatening condition caused by acute occlusion in the coronary artery. This condition leading to serious complication and need right and prompt treatment.<sup>9</sup> STEMI was diagnosed based on consistent symptoms of myocardial ischemic such as persistent chest pain and elevation of the ST-T segment in at least two contiguous leads in ECG. Revascularization with PCI is a standard procedure recommended by guidelines. Cardiogenic shock is one of the frequent complications in STEMI, characterized by decreased cardiac output, leading to organ hypoperfusion and hypoxemia.<sup>2</sup> In this case, the patient suffered from STEMI complicated with cardiogenic shock characterized by hypotension, cold acral, altered mental status, and acute kidney injury.

The etiology of acute kidney injury was grouped into three groups, prerenal, renal, and post renal. A prerenal condition characterized by a decrease in renal perfusion due to hypovolemia includes renal losses, impaired cardiac output or low output states, and peripheral vasodilatation. Renal achieves up to 25% of total cardiac output. Inadequate renal perfusion leads to impairment of renal function without damage in the parenchymal. Damage in renal structure also can lead to acute renal failure. Acute tubular necrosis, glomerulonephritis, interstitial damage, and injury to intrarenal vessels lead to impairment renal structure and function. Post renal conditions are

characterized by obstruction in urinary flow. This condition increases intratubular pressures and thus decreases GFR. The inflammation process also contributes to diminished GFR.<sup>10</sup> In this patient, acute kidney injury is a prerenal condition caused by a low cardiac output state because of myocardial infarction.

AKI in STEMI patients was a consequence of acute cardiac condition and its treatment. The incidence is increasing in the elderly, hypertension, and diabetic population. Acute cardiac conditions, such as hemodynamic changes, arrhythmia, and increased sympathetic activation, directly reduce renal arterial blood flow. Of note, factors reflecting hemodynamic impairment such as reduced ejection fraction and high end-diastolic pulmonary arterial blood pressures are independent AKI factors. Low EF also can induce intrarenal vasoconstriction and increase renal medullary necrosis.

Furthermore, increased thrombogenicity during acute coronary syndromes and microemboli during a cardiac catheterization may also contribute to renal damage. During STEMI, enhanced inflammatory response and increase oxidative stress synergistically accelerated the development of AKI. The other renal damage mechanism in STEMI treatment is contrasted with associated kidney injury (CA-AKI).<sup>11</sup>

This patient setting is a complicated situation. She was in a life-threatening condition with STEMI and cardiogenic shock. This condition complication in low renal perfusion and causing acute kidney injury. Previous nausea and vomiting worsen the condition. She also may suffer from depletion of intravascular volume due to low intake. Besides, the risk factor of renal failures such as hypertension and DM also plays a role in worsening renal function in this patient.

As the recommended procedure by guideline, primary PCI has a benefit and risk if done in AKI condition. It also can lead to worsening renal failure due to contrast-associated kidney injury. Some studies predict that PPCI in AKI baseline condition leads to higher mortality, prolonged hospitalization, and other complication.<sup>12,13</sup> Both cardiac complications and noncardiac complications were higher in AKI populations. In the other side, some study shows that there was a benefit from PCI in the setting of acute kidney injury caused by cardiogenic shock. Improvement in hemodynamic instability leads to improved renal perfusion, decreased creatinine level, and improved renal function.<sup>14-16</sup>

Guideline recommended that a decision on reperfusion strategy in renal dysfunction should be made as soon as possible, with an estimate of GFR function. There are several ways to prevent worsening renal function due to PCI; optimal hydration pre, Durante, and post-procedural; adjusting antithrombotic drugs, using iso-osmolar contrast and a minimal amount of contrast agent.<sup>2</sup> A randomized study showed that intravascular volume expansion among myocardial infarction treated with PCI confers protection from contrast-related AKI. Intravenous volume expansion, obtained immediately before primary PCI, although average (3 mL/kg in 1 hour) followed by 1 cc/kg BW/hour after procedure adjusted to EF, could partially compensate for reduced cardiac output and hypotension secondary to myocardial infarction and contribute to patient hemodynamic equilibrium (Figure 2).<sup>17</sup> Moreover, this can maintain renal perfusion in patients with depletion of intravascular volume caused by vomiting, diaphoresis, or decreased oral intake and hypovolemia.<sup>16</sup> Another study reveals that rapid hydration in the emergency room before the PPCI procedure is significantly more effective than both no hydration or post-procedural hydration.<sup>11</sup>

In these patients, acute kidney injury resulted from a low cardiac output state due to myocardial infarction and cardiogenic shock. A reperfusion strategy with PCI is recommended. She underwent

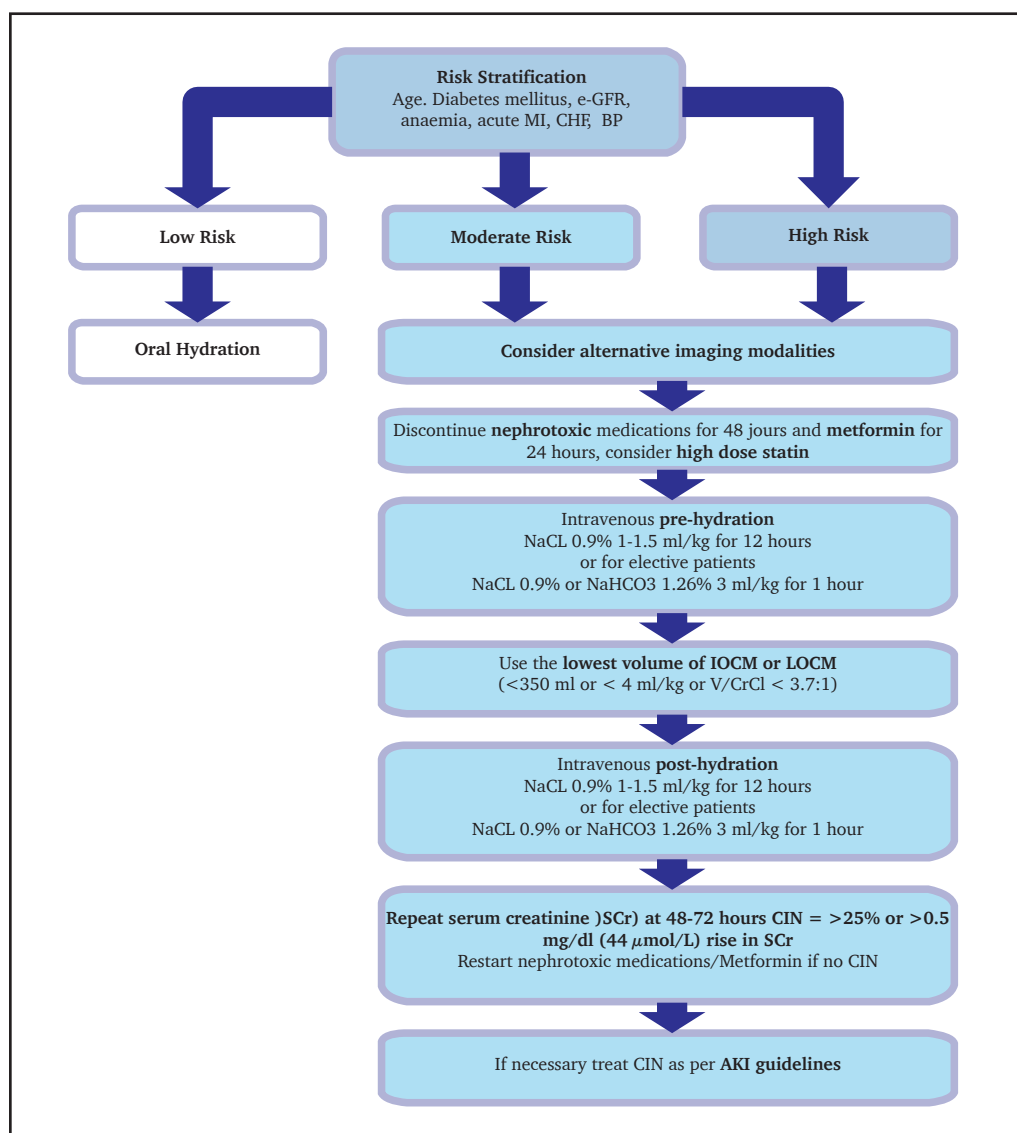


Figure 2. Algorithm for the management of CIN. Adapted from Rear R, et al. Contrast induced nephropathy following angiography and cardiac interventions, *bmj*.journal,2016

PCI in high-risk conditions. We give hydration pre-procedural in ER with normal saline 0.9% about 250cc. Durante procedural, we give hydration 1 cc/kg BW/hour and using minimal contrast about 100cc iso-osmolar contrast. After the procedure, we continue the maintenance hydration of 1 cc/kg BW/hour. After PCI was performed, there is an improvement in general condition, both myocardial infarction and renal function. This condition is characterized by the improvement of clinical outcomes, urine production, and laboratory findings.

In the study of Fox et al., bleeding risk, and complications after the procedure are related to AKI. The patient who experienced AKI has a higher femoral access-site bleeding, hematoma formations, and pseudoaneurysm compared to no AKI.<sup>13</sup> AKI in STEMI is related to poor prognosis, both short term, and long term. In-hospital mortality and 30-day mortality rate were higher in STEMI with AKI. In the long term, AKI onset following primary PCI was independently associated with a significant increase in death or dialysis's 2-year cumulative event rate.<sup>18</sup> Marenzi et al. show that renal function improvement after STEMI has a better prognosis than worsening renal failure. In this patient, there is an improvement in renal function after PPCI was performed.

### 3. Conclusion

Acute renal failure is a frequent complication in STEMI, leading to higher mortality, morbidity, and intrahospital complications. PPCI is a reperfusion strategy recommended by the guideline in the setting of myocardial infarction with cardiogenic shock. Hydration and volume status pre, Durante, and post PPCI procedures play an important role in clinical outcome. Close fluid monitoring is needed in AKI condition post-PPCI complicate with reduced cardiac function to avoid overload.

### 4. Declarations

#### 4.1. Ethics Approval and Consent to participate

Patient has provided informed consent prior to involve in the study.

#### 4.2. Consent for publication

Not applicable.

#### 4.3. Availability of data and materials

Data used in our study were presented in the main text.

#### 4.4. Competing interests

Not applicable.

#### 4.5. Funding source

Not applicable.

#### 4.6. Authors contributions

Idea/concept: OSP. Design: OSP. Control/supervision: MSR, SA, CTT. Data collection/processing: OSP. Extraction/Analysis/interpretation: OSP. Literature review: MSR, SA, CTT. Writing the article: OSP. Critical review: MSR, SA, CTT. All authors have critically reviewed and approved the final draft and are responsible for the content and similarity index of the manuscript.

#### 4.7. Acknowledgements

We thank to Brawijaya Cardiovascular Research Center.

## References

- Granger CB. Delays in Primary Percutaneous Coronary Intervention in ST-Segment Elevation Myocardial Infarction Patients Presenting With Cardiogenic Shock. 2018;11(18). 10.1016/j.jcin.2018.06.030
- Ibanez B, James S, Agewall S, et al. 2017 ESC Guidelines for the management of acute myocardial infarction in patients presenting with ST-segment elevation. *Eur Heart J* 2018;39(2):119–77. 10.1093/eurheartj/ehx393
- Danilo E, Laville M, Covic A, et al. NDT Perspectives A European Renal Best Practice ( ERBP ) position statement on the Kidney Disease Improving Global Outcomes ( KDIGO ) Clinical Practice Guidelines on Acute Kidney Injury : Part 1 : de fi nitions , conservative management and contrast-induc. 2012;1–10. 10.1093/ndt/gfs375
- Vavalle JP, Diepen S Van, Ms RMC, et al. *Am Heart J* 2015; 10.1016/j.ahj.2015.12.001
- Reinstadler SJ, Kronbichler A, Reindl M, et al. Acute kidney injury is associated with microvascular myocardial damage following myocardial infarction. *Kidney Int* 2017;92(3):743–50. 10.1016/j.kint.2017.02.016
- Kanic V, Vollrath M, Kompara G, Suran D, Hojs R. Women and acute kidney injury in myocardial infarction. *J Nephrol* 2018;31(5):713–9. 10.1007/s40620-018-0504-4
- El-Ahmadi A, Abassi MS, Andersson HB, et al. Acute kidney injury – A frequent and serious complication after primary percutaneous coronary intervention in patients with ST-segment elevation myocardial infarction. *PLoS One* 2019;14(12):1–11. 10.1371/journal.pone.0226625
- Kooiman J, Seth M, Nallamotheu BK, Heung M, Humes D, Gurm HS. Association Between Acute Kidney Injury and In-Hospital Mortality in Patients Undergoing Percutaneous Coronary Interventions. 2015;1–8. 10.1161/CIRCINTERVENTIONS.114.002212
- Sinkovič A, Masnik K, Mihevc M. Predictors of acute kidney injury (AKI) in high-risk st-elevation myocardial infarction (STEMI) patients: A single-center retrospective observational study. *Bosn J Basic Med Sci* 2019;19(1):101–8. 10.17305/BJBMS.2018.3797
- Basile DP, Anderson MD, Sutton TA. Pathophysiology of acute kidney injury. *Compr Physiol* 2012;2(2):1303–53. 10.1002/cphy.c110041
- Häner JD, Räber L. Oral post-hydration after primary PCI for STEMI. *Ann Transl Med* 2019;7(18):425–425. 10.21037/atm.2019.08.27
- Fan PC, Chen TH, Lee CC, Tsai TY, Chen YC, Chang CH. ADVANCIS score predicts acute kidney injury after percutaneous coronary intervention for acute coronary syndrome. *Int J Med Sci* 2018;15(5):528–35. 10.7150/ijms.23064
- Rihal CS, Textor SC, Grill DE, et al. Incidence and prognostic importance of acute renal failure after percutaneous coronary intervention. *Circulation* 2002;105(19):2259–64. 10.1161/01.CIR.0000016043.87291.33
- Sood MM, Zieroth S. Acute Kidney Injury Following Percutaneous Coronary Intervention: Trying to Get Whole Eggs From an Omelette. *Can J Cardiol* 2015;31(10):1221–2. 10.1016/j.cjca.2015.06.022
- Dai X, Bumgarner J, Spangler A, Meredith D, Smith SC, Stouffer GA. Acute ST-elevation myocardial infarction in patients hospitalized for noncardiac conditions. *J Am Heart Assoc* 2013;2(2):1–6. 10.1161/JAHA.113.000004
- Maioli M, Toso A, Leoncini M, Micheletti C, Bellandi F. Effects of hydration in contrast-induced acute kidney injury after primary angioplasty: A randomized, controlled trial. *Circ Cardiovasc Interv* 2011;4(5):456–62. 10.1161/CIRCINTERVENTIONS.111.961391
- Rear R, Bell RM, Hausenloy DJ. Contrast-induced nephropathy following angiography and cardiac interventions. *Heart* 2016;102(8):638–48.
- Kanic V, Kompara G, Šuran D, Tapajner A, Naji FH, Sinkovic A. Acute kidney injury in patients with myocardial infarction undergoing percutaneous coronary intervention using radial versus femoral access. *BMC Nephrol* 2019;20(1):1–7. 10.1186/s12882-019-1210-8